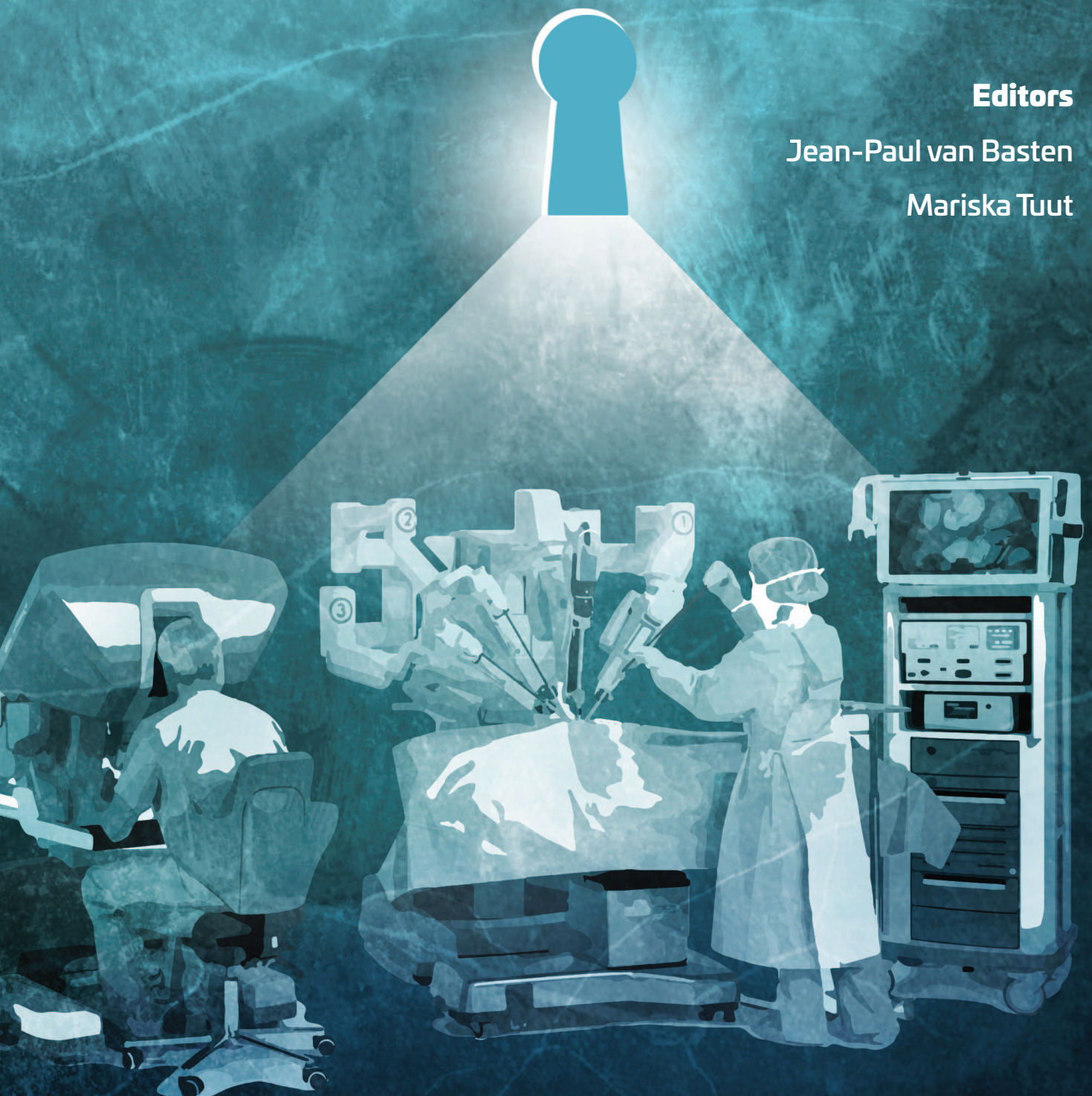

Recommendations in laparoscopic and robotic surgery in urology

Editors

Jean-Paul van Basten

Mariska Tuut



Colophon

Recommendations in laparoscopic and robotic surgery in urology

© 2017, Dutch Urological Association

Dutch Urological Association

P.O. Box 20078

3502 LB Utrecht

Phone: +31 30 282 3218

E-mail: nvu@xs4all.nl



NEDERLANDSE VERENIGING VOOR UROLOGIE

Initiative

Dutch Urological Association

In co-operation with members of

- Dutch Association for Obstetrics and Gynaecology
- Dutch Association for General Surgery
- Dutch Association for Anesthesiology
- National Society of Surgical Assistants

In co-operation with

- Netherlands Institute for Health Services Research
- TNO
- PROVA

Contents

<i>Contents</i>	4
<i>Working group members</i>	6
<i>Preface</i>	7
<i>Chapter 1. General introduction</i>	8
<i>Chapter 2. General aspects</i>	10
2.1. Instruments and equipment.....	10
2.2. Patient selection and contraindications.....	17
2.3. Anesthesiology for laparoscopic and robot-assisted urological procedures	19
2.4. Ergonomics	24
2.5. Efficacy and efficiency	25
2.6. Implementation of new techniques	26
<i>Chapter 3. Safety</i>	27
3.1. Introduction.....	27
3.2. Checklists and time-out	27
3.3. Instrument surveillance.....	29
3.4. Patient information and informed consent.....	30
3.5. Multidisciplinary user meeting.....	31
3.6. General and specific complications.....	32
3.7. Complications, outcome registration, and guidelines.....	33
<i>Chapter 4. Training and certification</i>	34
4.1. Introduction.....	34
4.2. Practical training leading to certification	34
4.3. The Dutch program on urological practical skills (D-UPS).....	34
4.4. The program for laparoscopic urological skills.....	35
4.5. Training and certification in robotic surgery	36
4.6. Transfer from training to daily practice.....	37
4.7. Operative assistants	37
4.8. Laparoscopic suturing and knotting	38
<i>Chapter 5. Procedure-specific aspects of laparoscopic and robotic surgery</i>	45
5.1. Introduction.....	45
5.2. Adrenalectomy	45
5.3. Nephrectomy.....	49

5.4. Cryoablation	59
5.5. Pyeloplasty.....	63
5.6. Robot-assisted radical prostatectomy (RARP).....	67
5.7 Robot-assisted sacrocolpopexy	86
5.8. Children	94
5.9. Radical cystectomy	102
5.10. Image-guided minimally invasive surgery in an experimental setting: robotic and laparoscopic sentinel node detection	107
5.11 Robot-assisted laparoscopic enucleation of the prostate (RALEP)	109
5.12. Robot-assisted laparoscopic ureterolysis and omental wrap	113
5.13. Robot-assisted partial cystectomy for bladder endometriosis	114
5.14. Laparoscopic and robot-assisted radical nephro-ureterectomy.....	117
5.15. Future perspectives	121
<i>References</i>	<i>124</i>
<i>Appendices (in Dutch)</i>	<i>134</i>
Appendix 1. Nederlandse samenvatting	134
Appendix 2. Samenvatting voor patiënten.....	136
Appendix 3. Implementatieplan	137

Working group members

- Jean-Paul van Basten, MD PhD, urologist, Canisius Wilhelmina Ziekenhuis, Nijmegen, chair
- Mariska Tuut, MSc, epidemiologist, PROVA, Varsseveld, co-chair
- Frank d'Ancona, MD PhD, urologist, Radboud University Medical Center, Nijmegen
- Maurits Barendrecht, MD PhD, urologist, Tergooi Hospital Blaricum
- Harrie Beerlage, MD PhD, urologist, Jeroen Bosch Hospital, Den Bosch
- Arto Boeken Kruger, MD, urologist, Tergooi Hospital, Blaricum, University Medical Center, Utrecht
- Willem Brinkman, MD PhD, urological resident, Erasmus Medical Center, Rotterdam
- Ivo Broeders, MD PhD, professor in surgery, Meander Medical Center, Amersfoort
- Ron van den Brom, MD, anesthesiologist, Medical Center Leeuwarden
- Tammo Brouwer, MD, anesthesiologist, Medical Center Leeuwarden
- Piet Calleweert, MD, pediatric urologist, Maastricht University Medical Center
- Rafal Chrzan MD PhD, pediatric urologist, Jagiellonian University Medical College, Krakow
- Nicole Dreessen, surgical assistant, Rijnstate Hospital, Arnhem
- Laurent Fossion, MD PhD, urologist, Maxima Medical Center, Veldhoven
- Ad Hendriks, MD PhD, urologist, Catharina Hospital, Eindhoven
- Flip Jansen, MD PhD, urologist, University Medical Center, Utrecht
- Sjoerd Klaver, MD, urologist, Maastad Ziekenhuis, Rotterdam
- Ben Knipscheer, MD, urologist, Treant Group, Emmen
- Anko Kooistra, MD PhD, urologist, Meander Medical Center, Amersfoort
- Brunolf Lagerveld, MD PhD, urologist, OLVG Hospital, Amsterdam
- Pilar Laguna, MD PhD, professor in urology, Academic Medical Center, Amsterdam
- Hans Langenhuijsen, MD, PhD, urologist, Radboud University Medical Center, Nijmegen
- Richard Meijer, MD, PhD, urologist, University Medical Center, Utrecht
- Jorg Oddens, MD PhD, urologist, Jeroen Bosch Hospital, Den Bosch
- Henk van der Poel, MD PhD, urologist, Antoni van Leeuwenhoek Hospital, Amsterdam
- Fieke Prins, MD, University Medical Center, Utrecht
- John Rietbergen, MD PhD, urologist, St. Fransiscus Hospital, Rotterdam
- Wout Scheepens, MD PhD, urologist, Catharina Hospital, Eindhoven
- Barbara Schout, MD, PhD, urologist, Alrijne Hospital, Leiderdorp
- Steven Schraffordt Koops, MD PhD, gynaecologist, Meander Medical Center, Amersfoort
- Geert Smits, MD PhD, urologist, Rijnstate Hospital, Arnhem
- Irene Tjiam, MD PhD, urological resident, Canisius Wilhelmina Hospital, Nijmegen
- Fred van der Toorn, MD PhD, pediatric urologist, Erasmus Medical Center, Rotterdam
- Paul Verhagen, MD PhD, urologist, Erasmus Medical Center, Rotterdam
- Lisanne Verweij, PhD, researcher, Netherlands Institute for Health Services Research, Utrecht
- André Vis, MD PhD, urologist, Vrije Universiteit Medical Center, Amsterdam
- Cordula Wagner, PhD, professor in patient safety, Netherlands Institute for Health Services Research, Utrecht
- Fokko Wieringa, PhD, senior scientist, TNO Science and Industry, Delft
- Carl Wijburg, MD, urologist, Rijnstate Hospital, Arnhem
- Patricia Zondervan, MD, urologist, Academic Medical Center, Amsterdam

Support from the Dutch Urological Association:

Until 31-12-2014 Rinie Lammers, from 1-1-2015 Jozette Stienen (policy advisor concerning quality)

Preface

Minimally invasive diagnostic and surgical approaches are now features of urological surgery. Urologists have a long tradition of endoluminal procedures, which have always been at the forefront of minimally invasive surgery. Laparoscopy makes it possible to operate intracorporally, which causes less surgically induced trauma than open surgery does. When laparoscopy was first introduced, only ablative procedures such as nephrectomies and dissections of pelvic lymph nodes were used. However, complex reconstructive procedures such as partial nephrectomy and radical prostatectomy became available to endo-urologists due to technological innovations in optical engineering, new cauterization devices, and the development of diminutive surgical instruments.

Laparoscopic surgery has been widely adopted in general urological practice and has now become the gold standard in renal and adrenal surgery. However, laparoscopy has its limitations due to rigid, non-articulated instruments, loss of three-dimensional vision and depth perception, the steep learning curve, and poor ergonomics. With the arrival of robot-assisted surgery in 2001, it became possible to perform difficult procedures in a minimally invasive way. Consequently, more and more open and reconstructive laparoscopic procedures are being replaced with robotic techniques. Urologists have adopted the robot for radical prostatectomy on a large scale worldwide. They have also adopted the robot for cystectomy, but to a lesser extent.

The Dutch Inspectorate for Public Health criticized robotic surgery in 2010. The criticism was about the inaccurate introduction of novel surgical techniques in general and, more specifically, about the introduction of robotic surgical systems in clinical practice. Moreover, policy makers and health insurance organizations are concerned about additional costs and the limited scientific evidence for the supremacy and efficacy of robot-assisted surgery. Although the advantages of robot-assisted surgery are obvious to most professionals, urologists should be aware of the criticism. They should introduce and master new techniques with great care and consideration. Education, training, and evaluation are of paramount importance due to the introduction of these new surgical techniques, patient safety, and the public pressure for transparency in healthcare and transparency of surgical outcomes. Professionals should evaluate the results, the efficacy, and the costs of different surgical techniques to assess whether an open, laparoscopic, or robotic technique is best suited to a given indication.

Laparoscopic surgery and robot-assisted surgery are appealing and challenging techniques for current- and next-generation urologists, but they do require special training and skills. A validated educational training program has been developed for laparoscopy, and another such program for robot-assisted surgery is being developed. The ultimate aim is to develop a validated, accessible, and cost-effective educational program leading to uniform quality of care in Europe. Collaboration with the European Association of Urology is essential, and is being sought, to achieve this goal.

The *Recommendations in laparoscopic and robotic surgery in urology* have been written to fulfill the need of a directory providing instructions in the domains of laparoscopic and robot-assisted surgery. The Dutch Urological Association and the Dutch Endo-urology Association are collaborating with allied societies, organizations, and work groups to meet the challenge of gathering all the important information about indications, safety, technical information, and education regarding laparoscopic and robot-assisted surgery in urology. The aims are to improve patient safety and to improve the quality of surgical outcomes.

The Dutch leading authorities on the subjects of laparoscopy and robotic surgery in urology have provided their input, and it is the wish of this editorial team that their work will contribute to a standard reference book for urological practice.

Jean-Paul van Basten
Mariska Tuut

Chapter 1. General introduction

Jean-Paul van Basten, Mariska Tuut

Since the first laparoscopic radical nephrectomy in 1997, laparoscopy has become accepted as an advantageous technique in the urological community worldwide, and it has been implemented in most European urological practices. The advantages for patients of minimally invasive surgeries versus open techniques are well established. They include less blood loss and a shorter convalescence time. Laparoscopic surgery is the gold standard in specific surgical procedures such as radical nephrectomy and adrenalectomy.

Laparoscopy is appealing and technically challenging to professionals. It provides remote vision and more distance between the instruments and the surgical field, the movements are opposite, and the vision is two dimensional, and it is augmented by the endoscope. Because of this complexity, it requires different surgical skills than open surgery does. Laparoscopic surgery was initially introduced without proper preparation, training, instruments, or guidance. Patients may have been exposed to unnecessary risks at that time.

The Dutch Health Care Inspectorate published their report *Risks of minimally invasive surgery underestimated* in November 2007.⁽¹⁾ The Inspectorate identifies professionals' underestimation of the risks of complications in laparoscopic surgery. Moreover, the Inspectorate demands that professional societies, such as the Dutch Urological Association, take measures to improve the safety and quality of laparoscopy. Guidelines or recommendations for laparoscopic surgery, including training, were lacking at that time. Guidelines for implementing new techniques such as single-site surgery were unavailable then.

In reply to this report, the Dutch Endo-Urological Foundation was commissioned by the Dutch Urological Association to develop scientifically based recommendations for common laparoscopic procedures in urology, training, instrumentation, and introduction of new surgical techniques. A modular, validated, training program in laparoscopic surgery was started, i.e. *Basic laparoscopic urological skills* (BLUS). The recommendations form the theoretical basis of the BLUS.

The surgical robot was introduced in the Netherlands in 2003. The number of surgical robots has increased rapidly since 2008. The government promoted a free market economy in healthcare. This created competition between hospitals. The surgical robot became a part of this competition and the purchase and rapid introduction of surgical robots was encouraged.

The Dutch Health Care Inspectorate published another report in 2010: *Inadequate precision in the introduction of surgical robots*.⁽²⁾ This report states that the starting criteria were undefined for autonomously performed robotic surgery. The report advocates proven capability and competency for "robotic surgeons". Furthermore, a validated training program for robotic surgery and certification for use were recommended. Surgical complications should be registered and evaluated on a regular basis. The final responsibility for patient care lies in the national guidelines and the recommendations of the professional societies, according to the Inspectorate.

New recommendations

The Dutch Urological Association took the initiative to develop evidence-based practical recommendations with the purpose of achieving a high-quality standard of laparoscopic and robotic surgery in urological care in the Netherlands. The new recommendations were unified with the guidelines of the Dutch Society of Endoscopic Surgery wherever applicable and possible. The first recommendations were published in 2010 as *Recommendations in laparoscopy in urology*,⁽³⁾ which constituted the basis for the *Basic training in laparoscopic urological skills*, and which is mandatory for urological residents. These recommendations were well received by the Health Care Inspectorate.

These 2010 recommendations contain general information about the safe practice of laparoscopy, and to a lesser extent, robot-assisted laparoscopy. Modification and modernization of these recommendations became necessary because robot-assisted surgery has a prominent role in current uro-oncological surgery.

The “present” EAU *Guidelines on laparoscopy* appeared in 2002,(4) and they describe specific procedures point by point, but they provide only limited background information about laparoscopy and training. Moreover, these outdated guidelines are almost 15 years old. The 2013 EAU *Guidelines on robotic and single-site surgery* briefly compares open surgery, laparoscopic surgery, and robot-assisted surgery, but does not determine procedure-specific information, training, or certification.(5) This necessitates updating practical recommendations including the fundamental principles of laparoscopy and robotic surgery.

The new recommendations describe indications and contraindications for laparoscopy and robotic surgery, the physiological effects of carbon dioxide insufflation, patient positioning, abdominal access and trocar placement, equipment, laparoscopic instrumentation, training in laparoscopy and robotic surgery, and complications unique to laparoscopic and robotic surgery. The recommendations also present a detailed description and illustration of common laparoscopic and robotic procedures. It is imperative that every urological resident and urologist be familiar with these procedures. These recommendations aim to provide comprehensive, state-of-the-art information about laparoscopic and robot-assisted urological surgery. Leading urologists and authorities have provided their opinions and thoughts about the safety, training, and best practice in laparoscopic and robot-assisted urology. The recommendations do not contain criteria, but they do give advice for best practice in safe surgery.

The authors hope that the current recommendations in this handbook will serve as a sound foundation for all professionals in urology who wish to expand their knowledge and skills to laparoscopic and robotic surgery. They also hope that the recommendations will lead to maximum safety and quality.

Justification

These recommendations are intended for both resident urologists and trainee urologists, and they are meant to serve them in the daily practice of laparoscopic or robot-assisted procedures. For the development of these recommendations, a working group of urologists with specific expertise in laparoscopy and/or robot-assisted interventions, along with experts in the field of anesthesiology, gynecology, surgery, surgical assistance, pediatric urology, technical aspects, and guideline methodology was set up. All working group members were mandated representatives of their professional associations.

The working group has considered the 2010 recommendations as the basis for the topics to be covered in the new recommendations. The group supplemented these topics with new-development topics (e.g. robot-assisted procedures and the image-guided sentinel-node procedure). The working group prepared draft texts for the chapters in a set lay-out. Contrary to the 2010 recommendations, these recommendations are formulated in the English language to reach a larger target population and to facilitate connecting with the European Association of Urology. Jean-Paul van Basten, working group chairperson, and Mariska Tuut, guideline methodologist, edited the drafts of the chapters to a draft manuscript. The target group of the recommendation then reviewed the draft manuscript, after which the final recommendations were established. The Dutch Urological Association has authorized these final recommendations.

These recommendations should be seen as a guideline: they have been developed to help urologists in their daily clinical practice. Departures from the recommendations may be necessary in individual cases, but they must be justified.

Chapter 2. General aspects

2.1. Instruments and equipment

Anko Kooistra, Fokko Wieringa

The tools for laparoscopy and robot-assisted surgery can be divided in two groups: instruments and equipment (Table 2.1.1).

Table 2.1.1. Instruments and equipment

Instruments	Trocars	
	Tissue handlers	Forceps, scissors Retractors, spacers
	Sealing	Clips, staplers Coagulation and electro-sealing Ultracision
	Miscellaneous	Endo bags Stitching and closing Suction and irrigation
Equipment	Insufflator Light source Optic and camera Graphic processor unit Monitor	

Applicable guidelines, standards, and laws

Applicable medical guidelines, standards, and laws:

- EAU guidelines on robotic and single-site surgery in urology(5)
- Multidisciplinary guideline for minimally invasive surgery(6)
- EAES guidelines for endoscopic surgery(7)

Applicable technical guidelines, standards, and laws:

- Covenant for safe application of medical technologies in the hospital; NFU-11.4224(8)
- Standards from the International Electrotechnical Commission (<http://www.iec.ch/>):
 - IEC 60601-2-2. Particular requirements for the basic safety and essential performance of high-frequency surgical equipment and high-frequency surgical accessories
 - IEC 60601-2-18. Particular requirements for the basic safety and essential performance of endoscopic equipment
 - IEC/TR 60930. It is advisable to embed this report into the hospital quality system for medical technology. An international workgroup regularly updates the report.

Instruments

Trocars

To enter the abdominal cavity, trocars (access ports) are placed in the abdominal wall so that laparoscopic instruments can be introduced. Blind insertion of the initial trocar bears the risk of intra-abdominal injury.

Evidence

There are three main options for initial port insertion: the open Hasson technique, closed access via the Veress needle, or the use of an optical port [Pemberton, 2006]. Good-quality evidence that compares these techniques in regard to complications is lacking [NVOG, 2012]. However, an open-entry technique is associated with a significant reduction in failed entries compared to a closed-entry technique.(9)

Trocars can be divided into two groups: disposable and reusable (Figure 2.1.1). There are also combinations of both types, the reposables. There is no preference for a particular type.



Figure 2.1.1. Types of trocars

Trocars can have different obturator tips (Figure 2.1.2):

- Blunt-tip trocars (open access)
- Cutting trocars, bladed and non-bladed
- Dilating trocars and radially expanding trocars
- Combination trocars: separators




Figure 2.1.2. Types of obturator trocars

These trocars differ in the force that is needed to go through the abdominal wall and in the size of the defect they leave behind in the fascia.(10) Unnecessary force should be avoided and the skin incision should be large enough.

Trocars come in different sizes (5, 10, 11 and 12 mm). To reduce the risk of trocar herniation, trocar wounds greater than 10 mm should be sutured. Dedicated fascial closure devices can be used (Figure 2.1.3). Hybrid trocars (metal trocars with plastic holders) should not be used (Figure 2.1.4).




Figure 2.1.3. Fascial closure device



Figure 2.1.4. Hybrid trocar

Hybrid trocars can create capacitive coupling when monopolar current is being used. Capacitive coupling commences if electrical current passes through intact insulation. Electrical current may come in contact with non-target tissue, causing unintended injury. These stray energy burns occur outside the view of the laparoscope, and are unknown to the surgeon.(11)

Specific trocars through which a camera and instruments can pass are available for single-site surgery.(5)

At the end of the procedure, all trocars should be withdrawn under visual guidance so that any excessive bleeding at the trocar sites will be observed. Placing the trocars at the lateral border of the rectus abdominis muscles in the lower abdomen creates a risk of injuring the epigastric vessels (Figure 2.1.5).

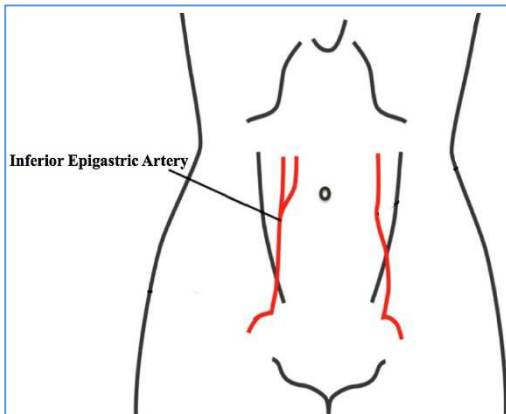


Figure 2.1.5. Location of inferior epigastric vessels

Recommendations

- Open trocar introduction is advisable for reducing failed entries and the risk of intra-abdominal injury
- Prevention of primary trocar injury requires control of the axial forces during introduction. This can be achieved by making the skin incision wide enough and placing a stretched index finger alongside the trocar to prevent uncontrolled passage
- Do not use a hybrid trocar as an entry port for electro-surgical instruments
- At the end of the procedure, all trocars should be withdrawn under visual guidance
- All trocar wounds greater than 10 mm should be sutured.

Tissue handlers

There are many types of tissue handlers such as forceps, scissors, retractors, and spacers. It is beyond the scope of this chapter to provide a comprehensive overview. However, we highlight one specific emergency situation: if a robotic grasper holding tissue suddenly fails (e.g. due to a shut-down of electrical power), the surgeon should know how to open it mechanically for safe retraction of the grasper (Figure 2.1.6).



Figure 2.1.6. Key for mechanically opening the robotic grasper

Sealing

Clips and staplers

There are various types of clips: polymer self-locking clips and titanium clips (Figures 2.1.7 and 2.1.8). These clips come in various sizes. It is important to leave a cuff to prevent a clip slipping from a blood vessel.



Figure 2.1.7. Various types of metallic clip appliers

Laparoscopic disposable staplers place multiple rows of small staples (Figure 2.1.9). There are usually six rows, and the tissue is automatically cut between the rows. Stapler malfunctions are rare, but they have been described.(12) Staplers can be used to construct a neobladder or pouch. However, stone may form on staples exposed to urine.

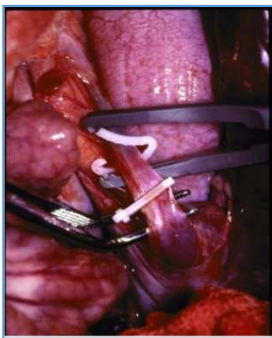


Figure 2.1.8. Polymer self-locking clip

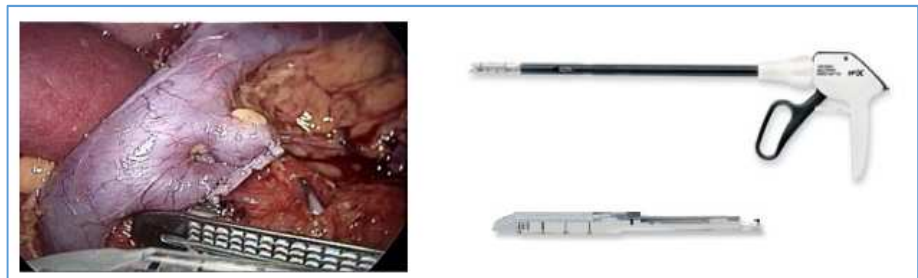

Figure 2.1.9. Renal vein and disposable stapling device

Recommendations

- Leave a cuff above the clip to prevent it from sliding off
- Free vessels before clipping
- Check the stapler before using it.

Coagulation, electro-sealing, and ultracision

Ultrasonic devices rapidly convert electrical energy into mechanical energy to induce frictional heating, sealing, and vaporization of the target tissue. Sealers directly apply heat to cauterize without conducting electrical energy through target tissues to achieve hemostasis, to seal tissue, and to divide it.

Electrosurgical devices conduct electrical current through tissues [Feldman, 2012].(13) There are two types:

- **Monopolar.** The active electrode instrument is used to cut tissue and coagulate blood. A return electrode pad is attached to the patient, and electric current then flows from the generator to the instrument through the patient to the patient return electrode (PRE) pad. The PRE is placed on the same site of surgery as close to the surgery site as possible. Because the PRE should be placed over a large muscle with adequate blood supply, it is usually placed on the upper leg. The reason for this is that muscle contains water, which is a conductor of electricity. If the patient has a metal hip prosthesis, the PRE should be placed on an alternative site. Monopolar diathermia is contra-indicated for any patient with a pacemaker or an implantable cardioverter defibrillator.

- **Bipolar.** The instrument contains two electrodes: an active electrode and a return electrode. The path of the electrical current is confined to the tissue between the two electrodes that are contained in the bipolar forceps, for example.

The tip of a recently activated ultrasonic device can cause an accidental burn if it contacts surrounding tissues. It takes a few seconds before this device has cooled down sufficiently.(14)

Insulation failure or capacitive coupling can occur at any point and can cause stray energy burns when monopolar diathermy is being used. The check of the insulation of the electrosurgical instruments is embedded in the hospital's protocols. Figures 2.1.10 until 2.1.12 summarize the causes of accidental injuries.(15)

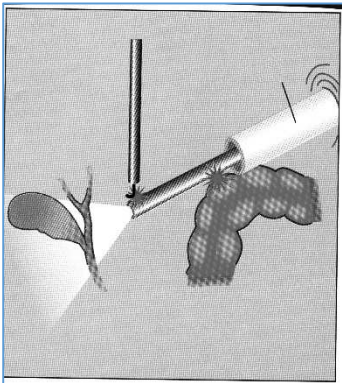


Figure 2.1.10. Direct coupling

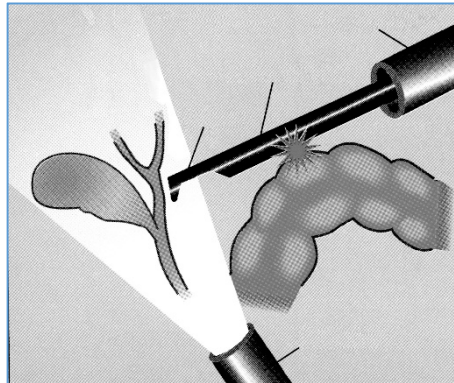


Figure 2.1.11 Defects in the insulation

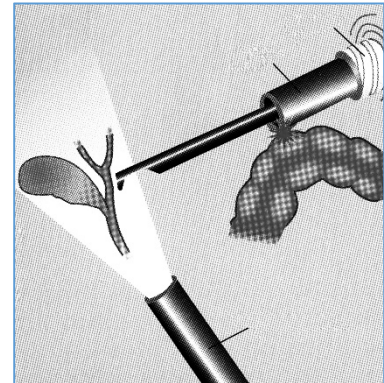


Figure 2.1.12 Capacitive coupling

Recommendations

- Do not use hybrid trocars when electrosurgical devices are being used
- The insulation of electrosurgical instruments must be checked according to the hospital protocol
- Be aware that the tip of the ultrasonic dissector remains hot after use
- Bipolar devices are preferable to monopolar devices. A monopolar device is contra-indicated for any patient with a pacemaker or an implantable cardioverter defibrillator. If a monopolar device is used, the PRE must be placed correctly.

Equipment

The insufflator

The insufflator regulates the intra-abdominal pressure (Figure 2.1.13). It is advisable to maximize the intra-abdominal pressure to 15 mmHg for adults, which is considered safe (Chapter 2.3). Lowering the intra-abdominal pressure reduces the intra-abdominal space. An acoustic signal of the insufflator gives a warning when the maximum intra-abdominal pressure has been reached. Table 2.1.2 shows the various circumstances that activate this warning. To maintain the intra-abdominal pressure, the CO₂ flow is set to a minimum of 10–20 L/min, but it is set even higher if there is leakage (for instance at the trocar sites).



Figure 2.1.13. Insufflator

It is advisable not to connect the CO₂ tube to the scope trocar because of the risk of condensation on the scope due to the relatively cold CO₂.

When argon beam coagulation is used (in partial nephrectomy), the extra gas will elevate the intra-abdominal pressure. The insufflator gives a warning if this happens. A tap of one of the trocars should be opened to release the excess gas and reduce the intra-abdominal pressures.

When the insufflation trocar or Veress needle is malpositioned (e.g. preperitoneally or in an intra-abdominal organ such as the omentum majus), the insufflator also gives a high-pressure warning.

Table 2.1.2. Circumstances activating the insufflator’s “intra-abdominal high-pressure” warning

Cause	High pressure in abdomen	False positive
Inadequate muscle relaxation	X	
Additional devices (e.g. an argon beam coagulator) to bring extra gas into the abdomen	X	
Kinked CO ₂ tube		X
Malpositioned Veress needle or insufflation trocar		X
Closed Veress needle or trocar tap		X
Filter defect		X

For preventing insufflator contamination, it is obligatory to place a microbe filter at the CO₂ outflow nipple (Figure 2.1.14) and to place the insufflator higher than the patient so that there is no fluid flow from the patient into the machine.



Figure 2.1.14. Tubing with microbe filter

At the beginning of the surgery, the pneumoperitoneum is created with a low flow at 1–2 L/min. The patient can gradually adapt to the elevation of the intra-abdominal pressure (Chapter 2.3). If the insufflator trocar or Veress needle is misplaced, this low inflow prevents serious adverse events. It is advisable to interrupt insufflation when the insufflator pressure immediately rises above 10 mmHg because such a rise indicates misplacement.

Before insufflation, the following items should be checked:

- The CO₂ container must be filled, open, in the upright position, and connected to the tube
- The power of the insufflators must be checked
- The CO₂ tube must be connected to the container and must not be kinked
- The CO₂ tube from the insufflator to the trocar must not be kinked
- The proper position of the Veress needle or insufflator trocar must be verified
- The trocar taps must be closed

Optic & camera, light source, graphic processor unit, and monitor

Visualization of the abdominal cavity is established through a laparoscope in combination with a camera, a video processor unit, and a monitor. There are two endoscope systems:

- Systems with an endoscope rod lens with a “clip-on camera” and a separate light source
- Integrated systems – the “chip on the tip” endoscope systems – that have a camera and light source at the tip of the shaft, as well as an integrated cable for the light source and a video connection.

There are different optics: 0° en 30°, and variable diameters (5, 8, and 10 mm). There is also a type of endoscope with a stereo lens system that creates 3D vision.

Purchase and life cycle of equipment

For laparoscopy, the Dutch Health Care Inspectorate mandates the installation of a hospital committee on minimally invasive surgery harboring surgeons who use minimally invasive techniques, OR staff, personnel from the sterilization department as well as the technical support department, and ICT. Other staff members can join when necessary.(1, 2) It is generally advisable to standardize the materials used by the various disciplines working in the OR.

Applicable guidelines, standards, and laws:

- National: Covenant for the safe application of medical technology in hospitals(8)
- International: IEC/TR 60930 (<http://www.iec.ch/>)

The IEC/TR 60930 is also valuable. For a hospital organization as a “user”, the life cycle of medical equipment starts with specifications of requirements. The IEC/TR 60930 describes the equipment life cycle from this user perspective. It deals with points such as:

- Involving potential users in the prepurchase and purchase phases
- Preparing a program of essential requirements from the user perspective
- Training and manuals for use and service
- Recording of periodic maintenance and repairs
- Commissioning testing for acceptance after purchase and delivery
- The important fact that it’s all about the people who work with the equipment and systems
- Electrical safety.

With this document at hand, directors and medical staff including a clinical physicist, nursing staff, purchase staff, and technical departments can steer the selection, acquisition, and maintenance of medical equipment and associated technical installations.

- International: IEC 60601-1 designated for market admission of medical equipment (<http://www.iec.ch/>)
Before medical equipment is approved for commercial release, it must pass a stringent “type test” against the requirements listed in the basic safety standard IEC 60601-1. This standard applies worldwide: for CE (which refers to "Conformité Européene") marking in the European Union (via the Medical Device Directive), for FDA approval in the USA, and all countries that maintain regulations for medical equipment. Of course it is superfluous to go through this complete type test for every individual device after purchase or maintenance. The IEC 62353 is available for that purpose. Different equipment categories have dedicated particular standards for treating particular aspects of each specific equipment category (e.g. IEC 60601-2-2 for electro-surgical equipment).

Recommendations

It is advisable to embed IEC/TR 60930 in the hospital quality system for medical technology. This report is regularly updated by an international working group.

2.2. Patient selection and contraindications

Paul Verhagen, Patricia Zondervan, Tammo Brouwer

Introduction

Laparoscopy is generally safe and can be applied to almost every patient. With increasing experience, laparoscopic surgery has become appropriate for patients with conditions previously regarded as suboptimal. Here we discuss various aspects of selecting patients for laparoscopy.

Contraindications

Contraindications for pneumoperitoneum:

- High intracranial pressure
- Retinal detachment
- Patients in shock
- Ileus
- Peritonitis, including peritonitis carcinomatosa

Relative contraindications for pneumoperitoneum:

- Decreased left-ventricular ejection fraction
- Respiratory insufficiency
- A history of pneumothorax
- Previous abdominal surgery or peritoneal dialysis
- Pregnancy
- Morbid obesity

Careful patient selection and the surgeon's expertise are critical in the decision to perform a laparoscopic procedure on patients with these comorbidities.(16) The anesthesiologist should be involved in the decision. The relative benefits and risks of laparoscopy should be discussed with the informed patient.

Decreased left-ventricular ejection fraction

The increased intra-abdominal pressure during laparoscopy in combination with the positioning of the patient increases the peripheral resistance, which requires adequate myocardial function. Preoperative cardiologic evaluation is advisable.

Respiratory insufficiency

Intra-abdominal insufflation with carbon dioxide increases the concentration of carbon dioxide in the blood. The ventilation must be increased to decrease the concentration of carbon dioxide in the blood. Limited pulmonary reserve will lead to hypercapnea, which may be a relative contraindication for laparoscopy. Decreasing the intra-abdominal pressure may reduce hypercapnea.

History of pneumothorax

Increased positive end-expiratory pressure during laparoscopy bears the risk of barotrauma, especially for patients with a history of pneumothorax.

Previous abdominal surgery and peritoneal dialysis

The most important predictive factor for adhesion formation ranging from 67% to 93% is a history of previous abdominal surgery.(17) Peritoneal dialysis is associated with extensive adhesions, the "cocoon abdomen". The retroperitoneal approach may offer advantages to the transabdominal technique in these cases.

Pregnancy

Laparoscopic surgery can safely be performed during any trimester of pregnancy, not only during the previously privileged second trimester. Specific measures, such as correct patient positioning, have to be taken. Gravid patients should preferably be placed in the left lateral decubitus position to minimize compression of

the vena cava. Prophylaxis is necessary to prevent deep vein thrombosis. The open, or Hasson, technique is preferable for initial abdominal access, and the location should be adjusted to the fundal height. Insufflation in the first trimester can safely be done with a Veress needle. There is a small risk of spontaneous abortion following surgical procedures that appears to be related to the anesthesia. Whenever laparoscopic surgery during pregnancy is considered, the procedure and alternatives should be discussed with the patient, the gynecologist, and the anesthesiologist.(18)

Obesity (BMI > 30 kg/m²)

Special long trocars and instruments have been developed for these procedures. The ventilation of morbidly obese patients during anesthesia can be a challenge.

Recommendations

- Laparoscopic surgery is contraindicated for patients with elevated intracranial pressure, retinal detachment, shock, ileus and peritonitis, including peritonitis carcinomatosa.
- Laparoscopy is a relative contra-indication for a patient with decreased left-ventricular ejection fraction, respiratory insufficiency, history of pneumothorax, peritoneal dialysis, previous abdominal surgery, pregnancy, or morbid obesity.

2.3. Anesthesiology for laparoscopic and robot-assisted urological procedures

Tammo Brouwer, Ron van den Brom

Introduction

Laparoscopic and robot-assisted surgery can only be performed once general anesthesia has been induced in the patient. Such surgery is facilitated by adequate muscle relaxation, establishment of a pneumoperitoneum [by insufflation with carbon dioxide (CO₂)], and the use of the Trendelenburg position (e.g. for prostatectomy or cystectomy). It is important to bear in mind that laparoscopic and robot-assisted procedures can induce specific and potentially harmful pathophysiologic changes.

An oro- or naso-gastric tube is placed to decompress the gastro-intestinal tract. This is important for reducing the risk of gastric injury when the trocars are inserted. The abdomen is inflated with CO₂ to effect a pneumoperitoneum. Patient positioning (e.g. the Trendelenburg position) may induce relevant pathophysiologic effects during anesthesia. We review these effects for each organ system in more detail.(19-22)

Perioperative monitoring

Laparoscopic and robotic surgery is performed while the patient is under general anesthesia with endotracheal intubation.

Standard patient monitoring for this procedure includes:

- Electrocardiogram
- Continuous blood pressure monitoring
- Pulse oximetry
- Capnography
- Temperature monitoring
- Monitoring of the muscle relaxation
- Airway pressure monitoring

Invasive arterial blood pressure monitoring with or without cardiac output monitoring (such as Vigileo or PICCO) or even trans-thoracic echocardiography (TTE) should be considered for older patients and for patients with cardiopulmonary comorbidities.

Hemodynamic effects

Hemodynamic effects of pneumoperitoneum

Hemodynamic changes during laparoscopy are primarily due to pneumoperitoneum and the induction of anesthesia, and, to a lesser extent, it is caused by the Trendelenburg position. Insufflating CO₂ into the abdomen with pressures of 15 to 20 mmHg establishes the pneumoperitoneum.

Normal intra-abdominal pressure (IAP) is 0 to 5 mmHg. Increases of IAP greater than 10 mmHg are clinically relevant, and increases above 15 mmHg can result in abdominal compartment syndrome, which affects multiple organ systems.

The cardiovascular reaction is an increase in systemic vascular resistance (SVR) with a decrease in cardiac output. However, the mean arterial pressure increases overall because an SVR increase exceeds the decrease in cardiac output. These effects are proportional to the increase in IAP. The SVR also increases due to the physiological effects of CO₂ insufflation, which include the release of catecholamines and vasopressin and activation of the renin-angiotensin-aldosterone-system. The decrease in cardiac output is due to compression of the inferior vena cava, which decreases the venous return (i.e. a decreased cardiac preload) and increased resistance in the venous circulation. If a patient is also relatively hypovolemic, these effects may be exaggerated. Cardiac output typically decreases from 10% to 30% (Figure 2.3.1).

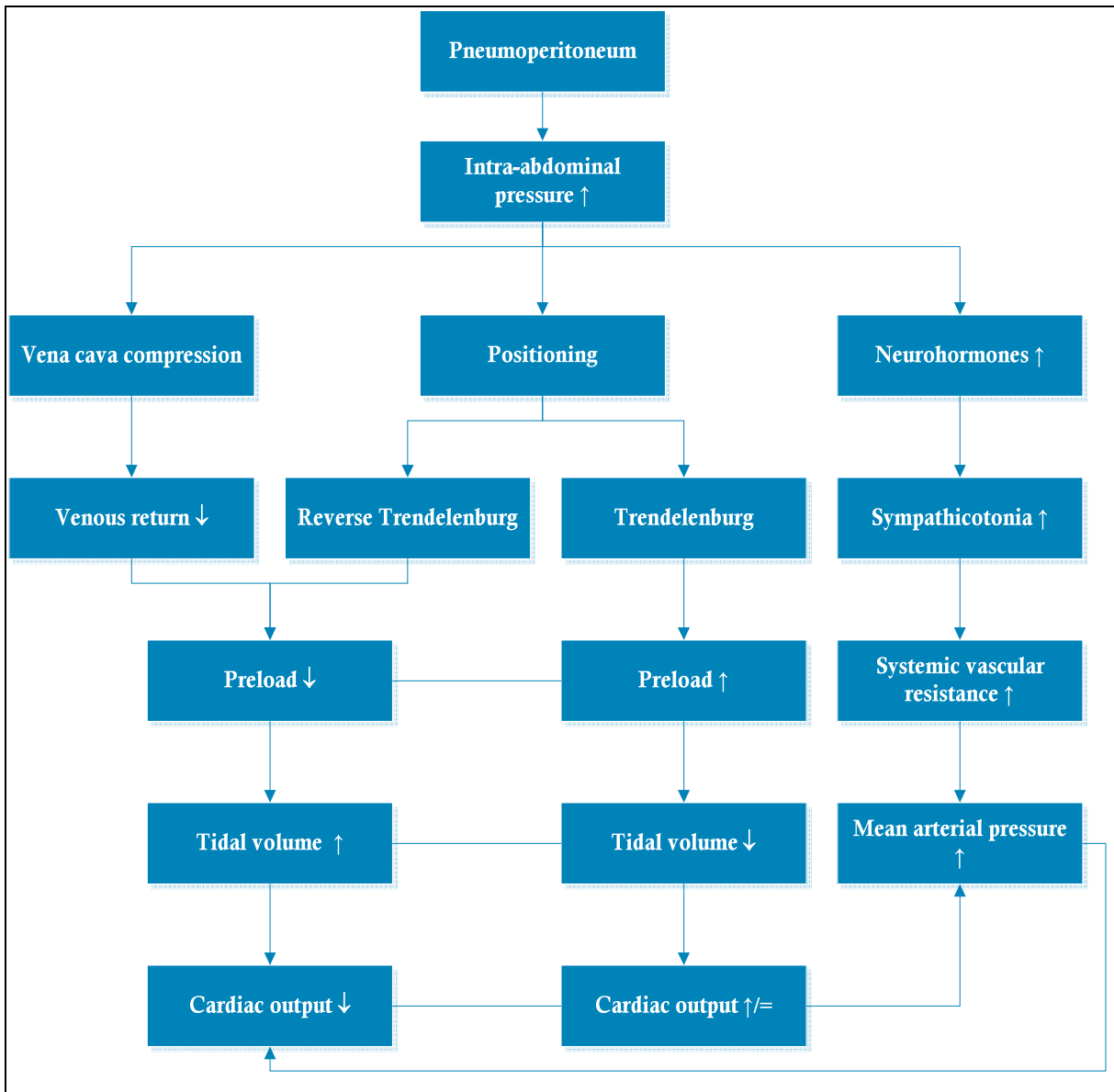


Figure 2.3.1. Hemodynamic effects of pneumoperitoneum (intra-abdominal pressure at 10-15 mmHg)

A patient with a cardiac disease may be at increased risk of further cardiac compromise and deterioration. Patients with depleted intravascular volume appear to be least able to tolerate these effects. To minimize the risks, the lowest insufflation pressure required to achieve adequate surgical exposure should be used. Ideally, the insufflation pressure should be less than 15 mmHg. Increases in SVR can be treated with vasodilating agents, centrally acting alpha-2 agonists, or opioids. Appropriate intravenous fluid loading prior to the induction of pneumoperitoneum can attenuate decreases in venous return and cardiac output.

Hemodynamic effects of positioning

The Trendelenburg position increases venous return and cardiac output. Conversely, pneumoperitoneum decreases venous return and cardiac output. The Trendelenburg position increases intracranial and ocular pressures. If this position is maintained longer than 4 hours, cerebral edema occurs, and the risk of retinal detachment increases.

The reverse Trendelenburg position (i.e. lumbotomy) decreases venous return and cardiac output. An extreme lumbotomy position may lead to “kinking” and compression of the vena cava that obstructs the venous return. Baroreceptors activate the sympathetic system, rising heart rate, and SVR. The reverse Trendelenburg

lenburg position causes venous stasis and creates the risk of venous thrombosis. It is advisable to administer low-molecular-weight heparin perioperatively and subcutaneously to prevent thrombosis.

Cardiovascular complications

Surgical manipulation of the peritoneal membrane, as well as irritation caused by the CO₂ insufflation, may result in cardiac dysrhythmia. Slow insufflation of CO₂ can decrease the risk of dysrhythmias.

Pulmonary and respiratory effects

Pulmonary and respiratory effects of pneumoperitoneum

Increased abdominal pressure elevates the diaphragm, which reduces the functional residual capacity (FRC) and the thoracic compliance. Hypoventilation of the basal pulmonary segments may result in atelectasis. These phenomena cause hypoxemia. Increases in IAP are directly related to decreases in ventilator capacity.

Using positive end-expiratory pressure mitigates the decreases in FRC. Greater airway pressure is required to generate a given tidal volume. Conversely, a mechanically delivered tidal volume results in higher airway pressures. Ventilation is adapted according to the measured end tidal CO₂.

Pneumoperitoneum causes hypercapnia due to the systemic absorption of CO₂. The pressure of arterial CO₂ (PaCO₂) rises on induction of pneumoperitoneum and equilibrates 15 to 30 minutes later. The degree of hypercapnia depends on the IAP. Inducing hyperventilation compensates hypercapnia. If hypercapnia remains despite hyperventilation, the IAP has to be reduced. If these measures do not suffice, the Trendelenburg position can be decreased.

Pulmonary effects of positioning

The Trendelenburg position decreases the FRC and thoracic compliance. This is more explicit in obese or morbidly obese patients.

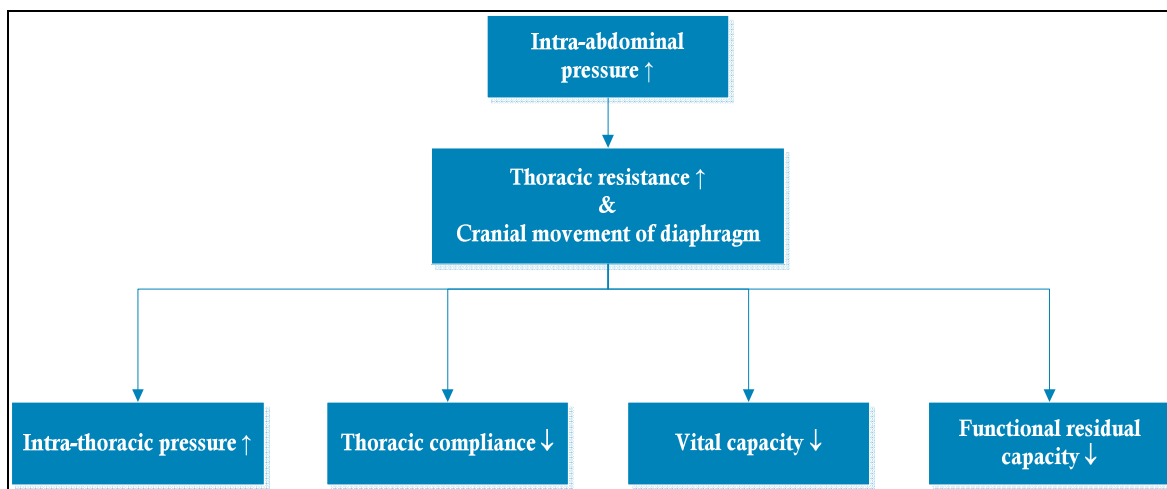


Figure 2.3.2. Pulmonary effects of pneumoperitoneum

Pulmonary and respiratory complications

Hypercapnia

Hypercapnia releases catecholamines, which increase the SVR, heart frequency, and blood pressure. Hypercapnia causes cerebral vasodilatation, which increases the intracranial pressure. In the case of life-threatening hypercapnia the following measures can be taken:

- Decrease the IAP
- Decrease the Trendelenburg position
- Convert to open surgery

Subcutaneous emphysema

Subcutaneous emphysema occurs during laparoscopy. Increased accumulation of CO₂ in subcutaneous fat may necessitate post-operative ventilation of obese patients with limited respiratory capacity.

Pneumothorax

CO₂ leaks from the intraperitoneal cavity through the diaphragmatic hiatus and orifices to the intrathoracic space. The resulting pneumothorax may be asymptomatic, or it may manifest as increased peak airway pressure, decreased O₂ saturation, and hypotension. In severe cases, this leads to cardiac arrest.

If anesthesiologic problems occur due to pneumothorax, surgery should be stopped immediately and the IAP released. After the patient has been stabilized, conversion to an open procedure may be indicated.

Endobronchial intubation

In the Trendelenburg position, it is possible that the endotracheal tube is advanced beyond the carina – usually into the right main-stem bronchus. When this occurs, only the right lung is ventilated. Atelectasis of the left lung and desaturation may also occur. The diagnosis is often confirmed by the unequal breathing sounds heard when the lungs are auscultated. Slightly withdrawing the endotracheal tube re-establishes two-lung ventilation.

Gas embolism

A gas embolism is rare, but it constitutes a life-threatening situation. The estimated incidence is between 0.0014% and 0.6%, with a mortality rate of nearly 30%. Asystole can occur as a result of a “gas lock” in the caval vein or right ventricle (RV) that interrupts circulation. The main cause is intravascular CO₂ insufflation by misplacement of the Veress needle or trocar into a vein or a parenchymal organ.

Initial steps include immediate deflation of the pneumoperitoneum, starting a 100% fraction of inspired oxygen, placing the patient in the left lateral head-down position to remove air from the RV outflow track, and hyperventilating to eliminate the increased PaCO₂ caused by the sudden increase in pulmonary dead space. A central line may be required to aspirate gas from the RV. Cardiopulmonary resuscitation is required.

Neurohormonal and renal effects of pneumoperitoneum

Pneumoperitoneum activates the sympathetic nervous system, which stimulates the neurohypophysis to cause a release of anti-diuretic hormone. This release leads to water resorption in the kidney. Adrenocorticotropic hormone is released, which stimulates the adrenals to secrete catecholamines. This leads to vasoconstriction and a rise in SVR. These two mechanisms decrease the glomerular filtration rate (GFR), which results in oliguria. Reducing the GFR activates the renin-angiotensin-aldosterone system, which causes a further GFR reduction and diuresis. Following pneumoperitoneum, oliguria and even anuria may persist for 4 to 6 hours.

Anesthetic technique

A wide variety of anesthetic techniques have been used for laparoscopic surgery. General anesthesia is routinely used, possibly with epidural anesthesia, depending on the degree of anticipated postoperative pain (e.g. after laparoscopic nephrectomy). A loco-regional anesthetic technique can be used to diminish postoperative pain, for example, transabdominal plane blocks, rectus sheath blocks, or intraperitoneal wound infiltration (the “Oslo method”). A good neuromuscular blockade will help the surgeon. Continuous infusion may be beneficial in robot-assisted surgery. This situation should be monitored, and the neuromuscular blockade should be reversed when even the slightest residual block is measured. Again, invasive monitoring, e.g. an arterial line, cardiac output monitoring or trans-esophageal ultrasonography, can be used if the patient is cardiovascularly compromised.

Postoperative recovery

Postoperative monitoring

Postoperative monitoring includes continuous measurements of:

- Peripheral oxygen saturation
- Respiratory rate
- ECG
- Blood pressure

Advanced postoperative monitoring may be required for cardiovascularly debilitated or unstable patients and ASA III (a patient with severe systemic disease) and IV (a patient with severe systemic disease that is a constant threat to life) patients.

Postoperative agitation

Patients may be confused and/or agitated postoperatively due to elevated intracranial pressure and an extended time in the Trendelenburg position. This may necessitate re-sedation. Facial and cerebral edema is common, but it disappears within hours. Cerebral edema requires more time for recovery. Hypertonic solutions (NaCl 3%) and high-dose dexamethasone (0.5 mg/kg) can be used perioperatively to reduce cerebral edema and concomitant agitation and confusion.

Prevention of postoperative nausea and vomiting

The following medications can reduce postoperative nausea and vomiting medication is advised:

- 5-HT₃ antagonists (e.g. ondansetron, 4 mg i.v. or 8–16 mg orally at induction of anesthesia or postoperatively to a maximum of 32 mg/24 hours)
- Prophylactic dexamethasone, 4 mg i.v.
- Dihydrobenzperidol can be used as a last resort or for patients with a history of severe postoperative nausea and vomiting. It is advisable to infuse droperidol 0.015 mg/kg before opioids are given.

Prevention of postoperative pain

Medication is advisable to reduce postoperative pain. Combinations of different methods are often used:

- Local anesthetics (e.g. bupivacaine or ropivacaine infiltration of the trocar wounds, i.e. the “Oslo method”)
- Rectus sheath block, transabdominal plane block
- Paracetamol (Acetaminophen) (maximum of 4 times 1 g in 24 hours po/i.v.)
- NSAIDS (e.g. diclofenac, maximally 150 mg in 24 hours)
- Opioids
- Thoracic epidural anesthesia, especially after laparoscopic nephrectomy

2.4. Ergonomics

Irene Tjiam, Harrie Beerlage, Ivo Broeders, Ben Knipscheer

Surgeon surveys have shown that 80–100% of laparoscopic surgeons report surgery-related complaints including pain in the head, neck, back, shoulders, elbows, and hands, as well as eye strain.(23) Laparoscopic radical prostatectomy creates a stressful position for the surgeon due to the prolonged unnatural position of the spine.(24, 25) In contrast, during robotic radical prostatectomy, the surgeon sits at a console, which provides a more stable posture for controlling instruments during the procedure.(26)

Ideal ergonomic positions for laparoscopy:

- Neck: bent downwards 10° with the least possible torsion
- Shoulders: relaxed
- Spine: straight with the least possible torsion
- Arms: adducted, the upper arms flexed slightly forward and the elbows flexed at 100°
- Wrists: slightly bent (Figure 2.4.1)
- Fingers: relaxed
- Legs: in a symmetrical standing position in relation to the pelvis, with easy access to foot pedals
- Instruments: screen, operation field, camera trocar, and surgeon in a straight line (Figure 2.4.2)
- Trocars: The angle between the instruments should be at about 90°, with the camera trocar in between

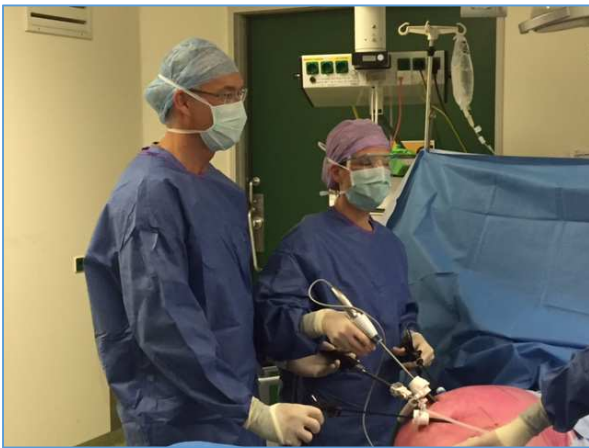

Figure 2.4.1. Relaxed position of the surgeon

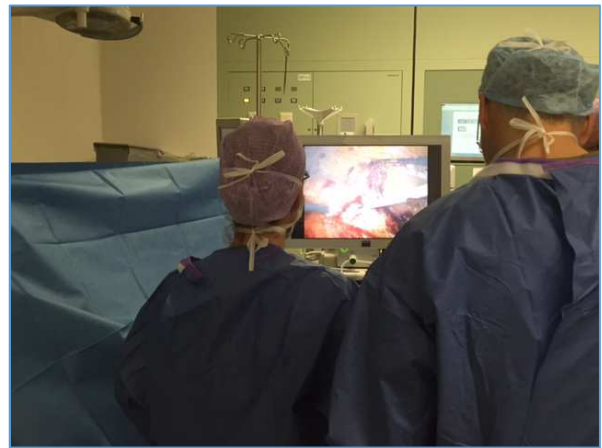

Figure 2.4.2. Screen in a straight line

Ideal ergonomic positions for robotic surgery (Figure 2.4.3):

- Neck: bent 10° downwards
- Shoulders: relaxed
- Spine: straight
- Wrists: relaxed at the console bar
- Knees: flexed at 100°
- Assistant trocars: at least 8 cm between the robot trocars and the assistant trocars

Operating room set-up for robotic surgery:

- Communication with the team: use microphone and speakers; create eye contact with the assistant
- Both the surgeon and the anesthesiologist are responsible for patient positioning

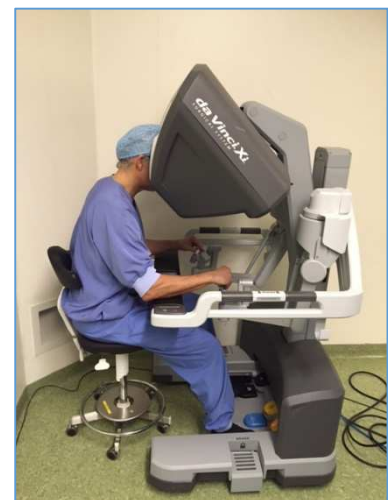

Figure 2.4.3. Ergonomic position for robotic surgery

2.5. Efficacy and efficiency

Jean-Paul van Basten, Mariska Tuut

Several national and international guidelines provide indications for laparoscopy and robotic surgery in urology.(4, 18, 27-36) Interested stakeholders have developed these guidelines, so that they may serve as indicators for effective care. This makes it possible to ascertain the efficacy of laparoscopic and robotic surgery with regard to survival and disease-free survival in oncological care, and to balance benefits and harms (including complications).

The efficiency of robotic surgery is still being discussed. A 2012 systematic review evaluates the economic characteristics and includes 11 reports with some form of cost analysis.(37) The authors conclude that robotic surgery is more expensive than laparoscopic surgery. This is not only because of high purchase, maintenance, and disposable costs, but also because of longer operating room times. However, there are indications that the disadvantage of longer times may fade out, since operating time decreases with experience using the robot.{Vickers, 2014 #356}

Liberman *et al.* assumed that robotic surgery for patients with clinically localized prostate cancer might be cost-effective, compared to other potential treatment modalities.(38) They state that, although robotic surgery is associated with high costs, other expanding technologies, including intensity-modulated radiotherapy, are expensive as well. Furthermore, they point out that the reduced length of hospital stay and potential earlier return to work must be taken into account, in the evaluation of cost-effectiveness. The researchers conclude that robotic surgery is expensive, but can become cost-effective in high-volume centers with high-volume surgeons. When a surgical robot is utilized to its maximum potential, it can become affordable. Another study reports that robot-assisted radical prostatectomy could be cost-effective in the United Kingdom with a minimum volume of 150 cases a year per robotic system.(39) Robot-assisted partial nephrectomy also tends to be cost-effective.(40)

The robotic system is particularly useful in difficult-to-perform laparoscopic surgeries because of the improved three-dimensional vision, ergonomics, and additional dexterity of the instruments. The outcomes for patients should be improved if we are to justify the use of the expensive robotic system. Therefore, more detailed information about the clinical and oncological outcomes, as well as about the incidence of complications after surgery with the robotic system, is needed.(41) The first results addressing better patient outcomes have been published. They show positive surgical margins for robot-assisted radical prostatectomy versus open and laparoscopic prostatectomy. This may result in a reduced need for adjuvant treatment, which may reduce further expenses. There is also evidence of an earlier recovery of functional outcomes, such as less urinary incontinence.(42) In addition, it is suggested that robotic surgery might be associated with shorter convalescence times and an earlier return to work.

Further studies are needed. These prospective studies should address the differences in patient important outcomes, including oncological outcomes, safety and quality of life. Future studies of efficacy should also focus on patients' 'out-of-pocket' expenses, and societal costs.

Recommendations

- Centralization of robotic surgery is an important factor which should be considered in cost-effectiveness.
- Patient outcomes should be monitored to provide more detailed insight into efficacy and efficiency.
- An evaluation of the costs and benefits of robotic surgery should take into account the surgical expenses, the added value of fewer complications, the potential of less adjuvant treatment, shorter convalescence times, and earlier return to work.

2.6. Implementation of new techniques

Arto Boeken Kruger, Fokko Wieringa

The introduction of new technologies brings uncertainties regarding benefits, harms, and additional costs. The implementation of new technologies should therefore be evaluated in a research setting.(43)

The categories are:

- Technologies. New diagnostic or therapeutic equipment, instruments, implants, etc.
- Techniques. Usually there are new surgical techniques regarding another surgical approach route, different pre- and post-treatments, etc., to be considered.
- Processes. New ways to organize, offer, and give healthcare, for example, a shift or expansion from one medical specialism to another for carrying out interventions.

Different levels can apply to each of these categories:

- New to the hospital. Proven technologies, techniques, or processes that are already being applied elsewhere in the country, without enough local pre-existing know-how and experience. Generally, this has to do with insured care.
- New in the country. Technologies, techniques, or processes that are already being applied abroad for which evidence and/or international guidelines are available. However, there is not enough national pre-existing know-how and experience. In such cases, insurance coverage generally requires negotiations.
- New in the world. Technologies, techniques, or processes in an experimental stage where medical evidence is lacking.

A guideline for the implementation of new techniques has recently been published in the Netherlands.(44)

Important recommendations in this guideline are:

- Prospective risk evaluation should be considered essential
- Education and training should be used to ensure safe implementation
- Effects should be monitored, and opportunities to adjust them should be created
- Efficacy and efficiency should be evaluated.

Applicable guidelines, standards, and laws

The Dutch national covenant on safe application of medical technology in hospitals offers additional guidance for medical technology (category A).(8) It is advisable to apply the Royal Netherlands Academy of Arts and Sciences (KNAW) report on evaluation of new technology in healthcare, especially for category A, levels 2 and 3 (medical technology new to the country or new in the world).(45)

Chapter 3. Safety

Cordula Wagner, Barbara Schout, Arto Boeken Kruger, Ad Hendriks, Fokko Wieringa, Lisanne Verweij

3.1. Introduction

Awareness of patient safety and risks during treatment is increasing. The Dutch Health Care Inspectorate and research institutions have written several reports on safety issues.(1, 2, 46-52) The quality of surgical procedures is affected by adequate equipment; adequate preparation, including the use of checklists; registration; evaluation; and of course the surgeon's good technical and non-technical skills. Multidisciplinary meetings are being increasingly integrated into daily care, and they are obligatory in urological oncology. They initiate open discussion and teamwork.

Ideally, a hospital is a safe environment for patients, but all humans make mistakes.(53) Several Dutch reports have shown that patients have been subjected to all kinds of unintended events.(54) Unintended events can be classified as adverse events and near misses. A commonly used definition for an "adverse event" is an unintended injury that results in temporary or permanent disability, death, or prolonged hospital stay, and it is caused by healthcare management rather than by the patient's underlying disease process. A near miss is usually defined as a mistake that does not reach the patient, or if it does reach the patient, it does not result in injury or harm. In the Netherlands in 2004, adverse events occurred in approximately 5.7% of hospital stays: approximately 2.3% of the adverse events were potentially preventable.(49, 52) More than 54% of the unintentional adverse events were associated with the surgical procedure, of which 34% were reviewed as preventable.

3.2. Checklists and time-out

3.2.1. Unintended events in the operating room: the Dutch situation

Safety checklists have been routinely used in aviation and other high-risk industries requiring complex human interaction since the 1930s. The purpose is to prevent accidents occurring as a result of human error.(55, 56) After the publication of several error reports in healthcare between 2000 and 2010, the awareness of patient safety increased. As a consequence, risk-reduction programs were set up in terms of standardization, checklist usage, and pointing out healthcare professionals' responsibilities. This was referred to as an "open culture".

3.2.2. Improving patient safety by introducing safety standards and protocols

The Dutch Health Care Inspectorate has been surveilling surgical processes and safety. They sent out warning signals about patient safety risks in 2006 and prepared a document for the preoperative, peroperative, and postoperative processes.(57)

The World Health Organization introduced a checklist called the "Safe Surgery Checklist" in 2008.(58) It was developed after extensive consultation aiming to decrease errors and adverse events, and it increases teamwork and communication in surgery (Figure 3.2.2.1).

Surgical Safety Checklist

World Health Organization
Patient Safety
A World Alliance for Safer Health Care

Before induction of anaesthesia	Before skin incision	Before patient leaves operating room
<p style="font-size: 0.8em;">(with at least nurse and anaesthetist)</p> <div style="background-color: #e0f2f1; padding: 5px; margin-bottom: 5px;"> Has the patient confirmed his/her identity, site, procedure, and consent? <input type="checkbox"/> Yes </div> <div style="background-color: #e0f2f1; padding: 5px; margin-bottom: 5px;"> Is the site marked? <input type="checkbox"/> Yes <input type="checkbox"/> Not applicable </div> <div style="background-color: #e0f2f1; padding: 5px; margin-bottom: 5px;"> Is the anaesthesia machine and medication check complete? <input type="checkbox"/> Yes </div> <div style="background-color: #e0f2f1; padding: 5px; margin-bottom: 5px;"> Is the pulse oximeter on the patient and functioning? <input type="checkbox"/> Yes </div> <div style="background-color: #e0f2f1; padding: 5px; margin-bottom: 5px;"> Does the patient have a: </div> <div style="background-color: #e0f2f1; padding: 5px; margin-bottom: 5px;"> Known allergy? <input type="checkbox"/> No <input type="checkbox"/> Yes </div> <div style="background-color: #e0f2f1; padding: 5px; margin-bottom: 5px;"> Difficult airway or aspiration risk? <input type="checkbox"/> No <input type="checkbox"/> Yes, and equipment/assistance available </div> <div style="background-color: #e0f2f1; padding: 5px;"> Risk of >500ml blood loss (7ml/kg in children)? <input type="checkbox"/> No <input type="checkbox"/> Yes, and two IVs/central access and fluids planned </div>	<p style="font-size: 0.8em;">(with nurse, anaesthetist and surgeon)</p> <div style="background-color: #e0f2f1; padding: 5px; margin-bottom: 5px;"> <input type="checkbox"/> Confirm all team members have introduced themselves by name and role. </div> <div style="background-color: #e0f2f1; padding: 5px; margin-bottom: 5px;"> <input type="checkbox"/> Confirm the patient's name, procedure, and where the incision will be made. </div> <div style="background-color: #e0f2f1; padding: 5px; margin-bottom: 5px;"> Has antibiotic prophylaxis been given within the last 60 minutes? <input type="checkbox"/> Yes <input type="checkbox"/> Not applicable </div> <div style="background-color: #e0f2f1; padding: 5px; margin-bottom: 5px;"> Anticipated Critical Events </div> <div style="background-color: #e0f2f1; padding: 5px; margin-bottom: 5px;"> To Surgeon: <input type="checkbox"/> What are the critical or non-routine steps? <input type="checkbox"/> How long will the case take? <input type="checkbox"/> What is the anticipated blood loss? </div> <div style="background-color: #e0f2f1; padding: 5px; margin-bottom: 5px;"> To Anaesthetist: <input type="checkbox"/> Are there any patient-specific concerns? </div> <div style="background-color: #e0f2f1; padding: 5px; margin-bottom: 5px;"> To Nursing Team: <input type="checkbox"/> Has sterility (including indicator results) been confirmed? <input type="checkbox"/> Are there equipment issues or any concerns? </div> <div style="background-color: #e0f2f1; padding: 5px;"> Is essential imaging displayed? <input type="checkbox"/> Yes <input type="checkbox"/> Not applicable </div>	<p style="font-size: 0.8em;">(with nurse, anaesthetist and surgeon)</p> <div style="background-color: #e0f2f1; padding: 5px; margin-bottom: 5px;"> Nurse Verbally Confirms: <input type="checkbox"/> The name of the procedure <input type="checkbox"/> Completion of instrument, sponge and needle counts <input type="checkbox"/> Specimen labelling (read specimen labels aloud, including patient name) <input type="checkbox"/> Whether there are any equipment problems to be addressed </div> <div style="background-color: #e0f2f1; padding: 5px;"> To Surgeon, Anaesthetist and Nurse: <input type="checkbox"/> What are the key concerns for recovery and management of this patient? </div>

This checklist is not intended to be comprehensive. Additions and modifications to fit local practice are encouraged.
Revised 1 / 2009 © WHO, 2009

Figure 3.2.2.1. Safe Surgery Checklist

The Dutch program of safety management started in 2009. The aim was to reduce preventable unintended events by 50%. The Dutch Society of Hospitals, the Dutch Federation of University Medical Centers, the Dutch Association of Medical Specialists, and the Federation of Nurses jointly initiated this program. The evaluation of the program has shown several improvements in patient safety procedures.(59)

The Dutch Association of Anesthesiology and the Dutch Association of Surgery had the Dutch guideline on the perioperative process published in 2011.(60) This guideline analyzes a patient's preoperative route and recommends stop-and-check moments.

The Dutch Health Care Inspectorate currently uses ten general safety standards for hospitals to indicate the minimum standard of care. Two of these general safety standards apply to medical technology. The second safety standard is about the use of checklists and time-out procedures. The fourth concerns the statement that only equipment of which the maintenance status is guaranteed may be used.

Safety standard 2. A time-out procedure is obligatory at the start of elective surgery

Enforcement began on January 1, 2011. The Health Care Inspectorate enforces measures against non-compliance to the obligatory time-out procedure. The time-out procedure consists of a checklist for checking patient and procedure details to get all the team members correctly informed. If the hospital board has not organized the time-out procedure adequately, the Health Care Inspectorate gives orders to have this procedure organized. The hospital is not allowed to carry out elective surgery until this has been done.

3.2.3. Evidence: the impact of checklists and TOPs

Using WHO's checklist for safe surgery reduced postoperative complication rates, and many hospitals have now adopted the time-out procedure (TOP) in the operating room. Nonetheless, operating staff, especially doctors, are far from actually embracing the idea.(55, 61, 62)

A study among 18 Dutch hospitals evaluated the compliance for the TOP before anesthesia in the operating room in 2011–2012.(52) The results showed a mean compliance of 71.3% with large differences between university hospitals (mean compliance rate 42.1%) and teaching or general hospitals (76.2% and 73.9%, respectively). In almost half the TOPS, the team did not focus on the TOP or the team was incomplete.

Although compliance is not yet optimal, several studies have already shown that postoperative patient outcomes improve when checklists and TOPs are used.(56, 63–65) Patel and colleagues included 16 articles in their systematic review.(64) Their selection was restricted to studies that used the WHO Surgical Safety Checklist. They observed a decrease in postoperative complications ranging from 11% to 36% and a reduction in mortality rates between 9% and 62%.

Russ and colleagues' systematic review assesses the impact of surgical safety checklists on the quality of teamwork and communication in the operating room.(56) They included 20 articles in their review. The results indicated that safety checklists are beneficial for teamwork and communication in the operating room, and they state that this may be one mechanism through which patient outcomes can be improved.

A Dutch study evaluated the impact of the surgical patient safety-system checklist SUR-PASS) in multiple hospitals.(66) This is a multidisciplinary checklist that follows the surgical pathway from admission to discharge. The total number of complications decreased from 27.3 per 100 patients (95% CI 25.9–28.7) to 16.7 per 100 patients (95% CI 15.6–17.9).

Recommendations

- Preoperative checklists are advisable.
- Just ticking boxes is not the ultimate goal here. Embracing a culture of teamwork and discipline is.(55)

3.3. Instrument surveillance

Reusable instruments wear, not only in mechanical functionality, but also in optical performance and electrical insulation properties. Visual inspection and checks of mechanical functionality are routine procedures within the central sterilization department. Routine testing of the equipment should be part of the regular work process.

3.3.1. Applicable guidelines, standards, and laws

International safety standard IEC 60601-1 contains an extensive number of safety tests (some of which are destructive) and conditions that manufacturers must satisfy before any medical equipment that uses electricity is approved for daily practice. Once equipment is approved, a more compact set of essential tests can be applied to monitor the condition of the equipment. Such essential routine tests are described in the standard IEC 62353 (<http://www.iec.ch/>).

IEC 62353 describes routine safety tests (e.g. tests for leakage of electrical current) on medical electrical equipment and systems (such as surgical robots) for the following points in time:

- Before the equipment is put into service
- During maintenance and inspection, as well as after repair
- During periodic testing.


IEC 62353 can also be applied to equipment that has not been built according to IEC 60601-1, provided that the safety standards for that equipment category are taken into account. The measurement methods of IEC 62353 can be applied regardless which IEC 60601-1 edition applies to the device. The standard is not intended to specify mandatory periodic testing intervals, but in case the manufacturer has not specified an interval, it can be determined from Appendix F. IEC 62353 offers methods to monitor the aging process of equipment with structured regular checks; for example, insulation checks.

Note: tests in IEC 62353 are more general than tests in IEC 60601-1, which specifies the heavy market approval “type test”, including potentially destructive tests.

Clause 201.7.9.2.14 of IEC 60601-2-2 requires equipment manuals to provide instructions for regular visual inspections (e.g. the use of a magnifying glass). Micro-cracks in the insulation material are hardly visible, but they can cause electrical breakthrough.

Recommendations

- Routine measurements of electrical insulation of electrosurgical equipment are not yet mandatory, but they are very useful, especially for endoscopic equipment. Such checks can prevent electrical burns outside the viewing area of the endoscope (Figure 3.3.1.1).
- Testing the light transmittance of connection fibers for cold light sources and the optical performance of endoscopes is advisable. The key optical endoscope parameters are: light transmission (LT), color correctness (CC), focus (FC), fiber transmission (FT), viewing angle (VA) and field of view (FV). The ScopeControl instrument, tested by six Dutch hospitals, can measure LT, CC, and FC with 5% precision, VA and FV with 2% accuracy, and FT with 10% precision.(67) The practical thresholds above which endoscopes are considered in good condition are VA: 75%; CC, FC, and FV: 70%; LT: 65%; and FT: 35% of new-state for the particular endoscope type.



The instrument is slowly passed through a measurement electrode that makes elastic contact around the entire instrument circumference. An alarm sounds when a weak spot is detected, so that one does not only test whether there is an insulation defect, but also tests for the location. A feed-through opening that matches the instrument diameter must be chosen for each test.

Figure 3.3.1.1. Routine insulation check with the high-voltage test (Photo: Blockland)

3.3.2 Tips and tricks

It is essential that routine safety tests themselves do not become the cause of defects. Electrosurgical equipment has a maximum tolerable voltage, and small instruments for delicate procedures often have a lower breakthrough voltage than larger instruments. Destructive testing, which keeps on increasing the voltage until the point of breakthrough, is counterproductive for routine checks. The point is to find clear weak spots from wear in insulation material. Such material, if undamaged, meets the safety requirements. Therefore, you should not use test voltages higher than the maximum voltage for the equipment to be tested unless you meet all the requirements as stated in clause 201.7.9.2.2.101c of IEC 60601-2-2.

3.4. Patient information and informed consent

It is important that the patient agrees to accept the treatment offered. It is essential for the patient to be fully informed so that he or she can make a decision about the treatment options. Providing the patient with information and the principle of the patient’s willing agreement is referred to as “informed consent” [KNMG, 2016].(68) The professional is responsible for the informed consent procedure and registration. The information for the patient should be understandable and should focus on:

- Diagnosis
- Prognosis

- Expected result of the suggested procedure
- Standard content of the suggested procedure (including type of incision, expected length of hospital stay, expected postoperative measures)
- Risks of the procedure
- Alternative treatment options

It is essential that the patient has understood the information and agrees with the suggested treatment, and that this is documented in the electronic patient files.

In the Netherlands, all rights which apply to the relationship between the doctor and the patient are described in the Dutch Medical Treatment Agreement Act. Some patients may be mentally incompetent, and some patients can be legally prevented from making medical decisions themselves.(69) In such cases, a legal representative of the patient makes the agreement.

The following categories apply to children:

- Less than 12 years of age: the parents need to agree, and while the child does not need to agree, he or she has a right to information
- 12 to 15 years of age: the parents and the child need to agree
- 16 to 17 years of age: the child has an independent right to information and to agree

For adults (at least 18 years old), the following persons can, in the consecutive order given here, act as the patient's representative:(69)

- A lawyer appointed "curator" or "mentor"
- A person who is authorized by the patient
- The spouse
- A parent, adult child, brother, or sister

Recommendations

- Patient information should be provided as set down in the Dutch Medical Treatment Agreement Act.
- In addition to information about the diagnosis, prognosis, and aim of the suggested treatment, three more items should explicitly be noted in the electronic patient file:
 - Information about the suggested procedure
 - The risks and possible complications
 - Alternative options

3.5. Multidisciplinary user meeting

Multidisciplinary user meetings are obligated to define hospital policies about minimally invasive surgery and to secure standards of quality.(70) All users should be invited to these meetings. This includes technical staff, ICT staff, operating staff, and staff from the sterilization department.

These meetings should include:

- Registration and training of the surgical team
- Training facilities
- Introduction of new materials and techniques
- Maintenance of uniformity in material and techniques
- Evaluation of safety and care quality

Applicable guidelines, standards, and laws

- The underestimated risks of minimally invasive surgery. In Dutch. (1)
- Follow-up to the assessment framework for minimally invasive surgery. In Dutch. (46)
- Inadequate precision in the introduction of surgical robots. In Dutch. (2)

Recommendations

- Multidisciplinary user meetings should take place at least four times a year
- A representative from each discipline should be present at these meetings
- The intention of these meetings is to minimize patient risks by means of continuous education, teamwork, and sharing knowledge. The meetings should include the following items:
 - There should be a formal procedure for introducing new instruments, equipment, and techniques
 - There should be relevant maintenance procedures and medical equipment checks
 - The hospital should evaluate outcomes, incidents, and complications, and it should provide regular annual reports evaluating all laparoscopic procedures carried out. The hospital should facilitate registration and discuss it at these meetings.

The hospital management should evaluate the management of certification and accreditation where applicable and according to the standards of practice of the national and international professional societies and regulatory bodies.

3.6. General and specific complications

Oncological and functional outcomes, as well as the number and severity of complications, determine the quality of the surgery. The categorization of complications in the Clavien-Dindo classification system is accepted internationally (Table 3.6.1). (71) This classification system focuses on the necessity of therapeutic interventions in the treatment of postoperative complications. The Clavien-Dindo classification system defines a complication as any deviation from the expected postoperative course. In this classification, complication grades I and II are usually considered minor, and grade III to V, major.

Problems solved during surgery are not mentioned in this complication registration system. Conversion to open surgery should be seen as “a sign of wisdom” rather than a mere complication.

Table 3.6.1. The international Clavien-Dindo classification system for surgical complications

Grade	Definition
I	Any deviation from the expected postoperative course without any need for intervention such as pharmacological, radiological, or surgical treatment. Non-registered interventions include anti-emetics, analgetics, anti-pyretics, diuretics, electrolyte infusion, physiotherapy, and superficial wound infections treated at bedside
II	Any required pharmacological treatment other than the one mentioned above, including antibiotics, blood transfusion, and parenteral nutrition
IIIa	Any intervention not requiring general anesthesia (e.g. lymphocele drainage and nephrostomy)
IIIb	Any intervention requiring the patient to be under general anesthesia (e.g. closure of wound dehiscence and double-J stenting)
IV	Life-threatening complications requiring intensive care management (e.g. myocardial infarction)
Iva	Single-organ dysfunction
IVb	Multi-organ failure
V	Death
Suffix d	If a patient still suffers from a disabling (d) complication at the time of discharge, the suffix ‘d’ should be added to the respective complication grade.

The Dutch Healthcare Inspectorate recommends registration of surgical outcomes, especially perioperative complications. The registration of complications may be useful for benchmarking with other organizations for the purpose of improving the quality of care.

3.7. Complications, outcome registration, and guidelines

- Complications in surgery are important causes of morbidity and mortality, and may result in an increased length of hospital stay, repeat surgery, additional medical treatment, legal issues, and increased costs.(72-77)
- The best way to prevent complications is by learning about all the possible pitfalls and developing the best strategy to avoid them, including good teamwork, preparation, and taking no unnecessary risks.
- When a complication occurs, try to recognize the first signs and prevent further deterioration.
- Uniform registration and definition of adverse events and mortality are advisable.(78-80)
- The registration of complications for the purpose of improving surgeons' performances can be distinguished from registration for the purpose of making outcome measurements public. Making the outcomes public promotes transparency, which in turn helps patients, policy makers and healthcare insurers make decisions.(81)

In the Netherlands, the following definitions of complications and outcomes are generally accepted:

- **Complication:** an unintended outcome during or following medical care that has a disadvantage for the patient and requires medical intervention or leads to irreversible harm
Note: a complication can be caused by an unexpected reaction of the patient, a calculated risk, or an event during care
- **Incident:** an unintended event during the care process that may cause, or may have caused, harm
- **Near miss:** an unintended event during the care process that does no physical, social, or mental harm because of early recognition and correction of the event
- **Adverse event:** an unintended harmful outcome caused by the professional or care system that results in temporary or permanent disability or death.
- **Avoidable adverse event:** an adverse event caused by omission
- **Emergency:** very severe adverse event

Although the volume of operations is not obviously related to the outcome of the uro-oncological procedures, there is consensus among the Dutch Urological Association, the Health Care Inspectorate and healthcare insurers about the minimum volume of procedures that must be performed annually to achieve good quality of care: 10 adrenalectomies, 20 radical prostatectomies, 10 radical or partial nephrectomies, 5 retroperitoneal lymph node dissections for testicular cancer, and 20 radical cystectomies (an average of 60 in 3 years).(82)

Recommendations

- Collect outcome data, including complications, conversions, incidents, and late results
- Evaluate the outcome data for each surgeon for benchmarking and improving the quality of care.
- Regularly discuss both the operation results and the complications with the complete operation team and propose actions to further improve the outcomes and prevent complications.

Chapter 4. Training and certification

John Rietbergen, Carl Wijburg, Barbara Schout, Henk van der Poel, Ben Knipscheer, Irene Tjiam, Nicole Dreessen, Willem Brinkman, Jean-Paul van Basten

4.1. Introduction

Many urology trainees have reported underexposure to formal training for laparoscopic skills in a survey among European trainees. Only 23% of the trainees rated their laparoscopic training as satisfactory.(83) The results of the European Basic Laparoscopic Urological Skills exam showed that only 39% of the trainees reported access to training. The skill levels measured were lower than the expected standard.(84)

4.2. Practical training leading to certification

While some skills are best learned in a clinical environment, a skills laboratory is probably the best learning environment for other skills. As Dankelman and colleagues point out, “Surgery and car driving are comparable in several aspects. Some of these skills can only be acquired in a very realistic situation, while others, like using surgical instruments and changing gears, can easily be taught outside the realistic environment.”.(85)

There is an ongoing discussion about whether training facilities such as the dry lab or the wet lab (with laboratory animals) contributes to improving clinical performance.(86) There are contradictory reports of such activities and their relevance to clinical performance.(87, 88)

Medico-legal concerns exist about the certification of laparoscopic and robotic skills.(89-91) Quality control and validation of training are essential.(92) Those who use a training program including simulators have to know its educational value and validity. The certification is actually an approval of the mastery of laparoscopic and robotic skills. Educational organizations cannot provide the certificates.

Individual countries have different certification organizations. However, such organizations rely on professional societies, such as the Royal College of Surgeons and the American College of Surgeons. These societies provide an educational curriculum that includes training and testing before certification.

4.3. The Dutch program on urological practical skills (D-UPS)

The D-UPS program consists of a series of training modules for mastering urological procedural skills. It is part of the Dutch urology curriculum. The D-UPS program combines acquisition and rehearsal of theoretical knowledge, which the program furnishes via practical training for urological skills and techniques (Figure 4.3.1).

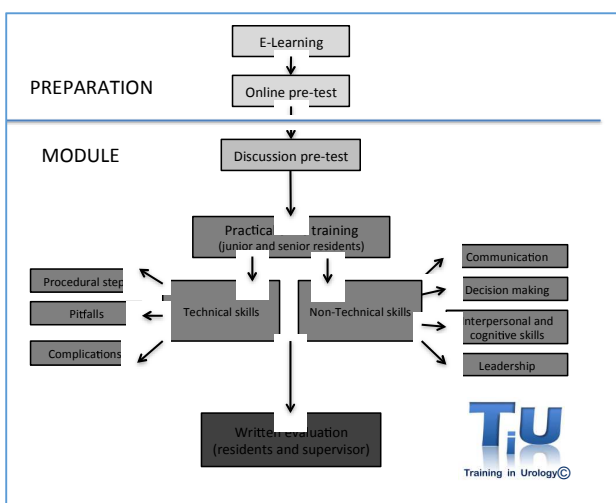


Figure 4.3.1. Outline of a module of the Dutch program on urological practical skills

4.4. The program for laparoscopic urological skills


The program for laparoscopic urological skills (PLUS) is an assessment program. In the Netherlands, surgical residents are obliged to participate and pass the tests included in the PLUS before they can start their residency in urology.(93, 94)

The proficiency standard of the PLUS is set for second-year residents in urology so that competent residents can be selected. The PLUS test is a starting point for further training in the next 4 years of residency. Therefore, the PLUS assessment cannot be interpreted as proof of full competency in procedural skills.

The PLUS consists of five basic tasks to train hand-eye coordination, intracorporal suturing, needle handling, and clip and cut skills. The training tasks were partially adopted from the Fundamentals of Laparoscopic Surgery (FLS, American College of Surgeons) and partially adapted for urological purposes. The tests are set up in a box with an endoscope and a light source connected to a screen. The examinee can only look at the screen.

The examinee can practice for 1 minute to get used to the instruments and the task. Each task is assessed twice. The examinee's performance is observed and rated. The assessment criteria are based on time and quality.

Task 1: transfer of objects. Transfer the objects one by one from one side of the board to the other side. Lift each object with a grasper in your non-dominant hand and transfer it to the dominant hand. Place each object on a peg on the other side of the board. Once all objects have been transferred, transfer them back to the original side in the reverse procedure. Grasp the object with your dominant hand and transfer it to your non-dominant hand. Place each object on a peg on the original side of the board with your non-dominant hand. If an object falls, do not grasp it. Each transfer must be done in mid-air, without the use of the pegs or block for assistance.



Score

- Time: starts when the first object is touched and stops when the last object is placed on the peg on the original side of the board
- Error: the number of objects dropped
- Target time: 112 seconds


Task 2: cutting a circle. Cut the circle between the two black lines. Only the first of two layers of the gauze has to be cut. You must start cutting somewhere between the circles, and the continuous outer and inner lines should not be crossed.



Score

- Time starts at the first cut and stops when the circle is loose from the rest of the gauze
- Error: cut in or beyond the outer or inner line of the circle
- Target time: 118 seconds

Task 3: knot tying for laparoscopic sutures. Place a single suture through the two dots. Place three knots on the suture: one double knot and two single knots. Make sure that the edges of the slit are approximated and that the knot will not slip. You finish the exercise by cutting



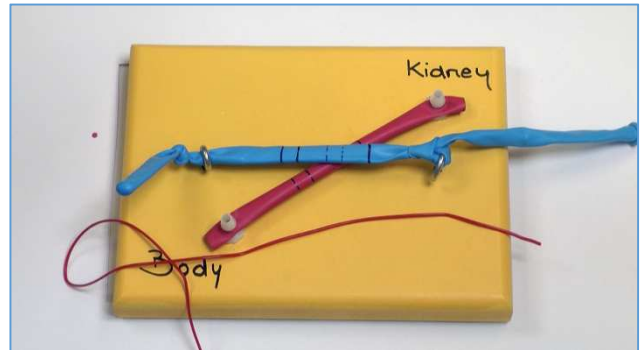
the suture approximately 2 to 3 mm above the knot.

Score

- Time starts when the needle is grasped and stops after the cutting of the suture.
- Error:
 - Stitch beyond 1 mm of the black dots in one or both dots
 - No approximation of the slit
 - A slipping knot
- Target time: 283 seconds

Task 4: clip and cut

- Loop: place a double loop in the middle of the blue tube. Then fix the loop outside the trainer box with a mosquito so that the red tube is free and visible.
- Red tube: apply three clips on the continuous lines on the red tube. Make sure the bottom tip of the clip is seen before you close the clip applicator. After the three clips have been applied, cut the red tube between the dotted lines. Then loosen the loop on the blue tube.
- Blue tube: apply three clips on the continuous lines of the blue tube. Make sure the bottom tip of the clip is seen before you close the clip applicator. After the three clips have been applied, cut the blue tube between the dotted lines.



Score

- Time starts when the loop is grasped and stops when the blue tube is cut.
- Error:
 - Not all six clips have been applied
 - The clips have been applied outside the continuous lines
 - The cutting is outside the dotted lines
- Target time: 251 seconds

Task 5: needle guidance. Guide the needle through the metal rings from 1 to 10 in the correct order. Be sure the ring is entered in the direction indicated by the black arrows. Make sure you do not bend the needle by using too much force; use rotation movements of the wrist to get through the rings.



Score

- Time starts when the needle is grasped and stops when the needle goes through ring number 10
- Target time: 218 seconds

4.5. Training and certification in robotic surgery

As most robot-assisted procedures are complex, it is essential to achieve competencies in the surgical steps of the procedure and not just in the operation of the device itself. In many countries, there is limited national experience in the provision of such training. Therefore, organizations such as the European Association of Urology (EAU) have an important role in providing structured training and in certifying training activities. The EAU Robotic Urology Section (ERUS) provides a robotic surgery curriculum, and a pilot fellowship program, in addition to master classes and live surgery demonstrations, all of which the EAU certifies.(95)

4.6. Transfer from training to daily practice

After the trainee completes the structured basic training, he or she is obliged to perform interventions under the supervision of an experienced urologist. A fellowship with the trainee operating under direct supervision for at least 6 months (usually 1 to 2 years) is advisable. Another way of teaching is to have an experienced urologist supervise in the trainee's hospital. The advantage of this method is that the whole surgical team can be trained. There are primarily three types of robotic training programs (table 4.6.1):(96)

Table 4.6.1. Three types of robotic training programs

Program	Surgeon training				Surgeon assessment	
	Duration	Training	Details/methods	Cost	Subjective	Objective
Fellowship	1–2 years	Simulation studies Clinical setting	Long-term one-to-one mentoring	NA	Proctoring by mentors	GEARS for simulation CUSUM for prospective learning curve evaluation*
Mini-fellowship	5 days	Simulation studies	Short-term mentoring, case observation Proctoring by mentor supervision	~\$ 3800	Proctoring by mentors	GEARS for simulation CUSUM for prospective learning curve evaluation*
Mentored skills course	2 days	Simulation studies	Short-term mentoring and teaching	NA	Proctoring by mentors	GEARS for simulation CUSUM for prospective learning curve evaluation*

*Not used currently, but could be used according to recent studies

GEARS, Global evaluative assessment of robotic skills; CUSUM, cumulative summation; NA, not available

A fellowship is the most comprehensive course that includes one-to-one mentoring and teaching in both simulated and clinical environments. The training usually takes 1 to 2 years. However, there is limited availability of fellowship facilities. A mini-fellowship or a mentored skills course may be an alternative. A mini-fellowship is a 5-day intensive training course with theoretical sessions, dry and wet lab sessions, and observation of and/or assistance in surgical procedures.(97, 98) The mentored skills course combines an e-learning program with a 2-day mentored course.(99, 100) Further, despite the short duration of the last two courses, 70-80% of the trainees were successfully introduced to robotic surgery, with a continuation of 3 years of post-training. The American Food and Drug Administration (FDA) mandates training in robotic surgery for all surgeons performing robot-assisted procedures.

To sum up, both novice and experienced open surgeons require training, mentoring, and supervision before they can be introduced to laparoscopic and/or robotic surgery. The Dutch Healthcare Inspectorate requires proven competence certificates to control the robot system in clinical practice. The robot producer offers an on-line training program, as well as a 2-day basic robotic course in a European training center for the surgical team (<http://www.intuitivesurgical.com/training/>). On-site clinical training is offered as well as on-site supervised training. The Dutch Healthcare Inspectorate has determined that the training provided by the robot producer is adequate for surgical assistance. The company provides the certificates at the end of the courses and training.

4.7. Operative assistants

Robot-assisted surgery and laparoscopy require team work, including collaboration of the surgeon, anesthesiologist, and operative assistants. Users of medical devices must be competent, and hospitals are obliged to secure such competency.(8)

Operative assistants in robot surgery have the following tasks:

- Positioning and connecting the different robot devices in the operating theater
- Sterile draping of the robot patient cart
- Positioning the robot arms
- Connecting the robot to the trocars
- Changing instruments during the procedure
- Disconnecting the various robot devices and storing them

In robot-assisted surgery, operative assistants need specific knowledge and skills:

- Knowledge of urological anatomy
- Knowledge of the procedures, including patient positioning
- Knowledge of the surgical robot and its instruments
- Knowledge of complications and risks
- Practice skills: eye-hand co-ordination, acquired in simulation models

The Dutch Association of Operative Assistants recommends training and certification of personnel before they assist in robotic and laparoscopic procedures. This includes an introduction track in the operating theater. Training in the following order is advisable:

- Assisting in circulating
- Assisting in instrumenting
- Instrumenting and assisting on one's own

Annual training is advisable after this initial training.

Recommendations

- The Program for Laparoscopic Urological Skills (PLUS) assessment is advisable in the selection of competent residents. It is a starting point for further training in the next 4 years of residency.
- The EAU Robotic Urology Section (ERUS) provides a robotic surgery curriculum, and a pilot fellowship program, in addition to master classes and live surgery demonstrations, all of which the EAU certifies [EAU, 2014]. This type of approved and structured training in robotic surgery is advisable
- After the trainee completes the structured basic training, he or she is obliged to perform interventions under the supervision of an experienced urologist. The advisable route is via a fellowship.

4.8. Laparoscopic suturing and knotting

Jean-Paul van Basten, Ben Knipscheer

Introduction

The most demanding acts in laparoscopic surgery are suturing and knot-tying. These techniques have to be mastered by those who are pursuing laparoscopy and requires a lot of training and dexterity.

Knotting techniques

The key issue of knotting is the tightness of the knot. The safety of the knot depends not only on the knot itself, but also on the type of suture material used. Any material that swells in contact with water increases its capacity of tying and tightening. Knots made of polyglactin (e.g. Vicryl) and lactomer can be considered safe, whereas those made from polydioxanone (e.g. PDS) or polyamide (e.g. Ethilon) are less reliable. Moreover, a knotless alternative suture is the barbed suture. The barbs on the surface penetrate into the tissue and prevent slipping of the suture, which eliminates the need for knots.

A laparoscopic knot can be made several ways:

- An intracorporal knot can be made with a needle holder and an assistant needle holder that reproduce the phases of a technique already known in traditional surgery.

- A slipknot or a preformed loop is made on the distal end of the suture. After having pierced the tissues with a needle, the needle is pulled through the preformed loop, and functions as a lock after it has been tied.
- The distal end of an interlaced suture can be pierced with its needle to create a loop.
- A reabsorbable clip can be placed at each end of the thread.

The ideal length of a suture for separate knots is 7 to 10 cm, a length that makes the knot-tying maneuvers easier than longer threads do. For a running suture, the suture thread should be 15–20 cm long, so that the final knot can be tied. Holding the thread 1 to 2 cm behind the needle makes inserting the suture easier. The easiest method of intracorporeal knot-tying consists of holding the needle with its concavity bent upwards. The curved and rigid structure of the needle allows the needle holder to act on it and makes it possible to wind around the needle holder. The end of the suture should not be longer than 2 cm (Figure 4.8.1).

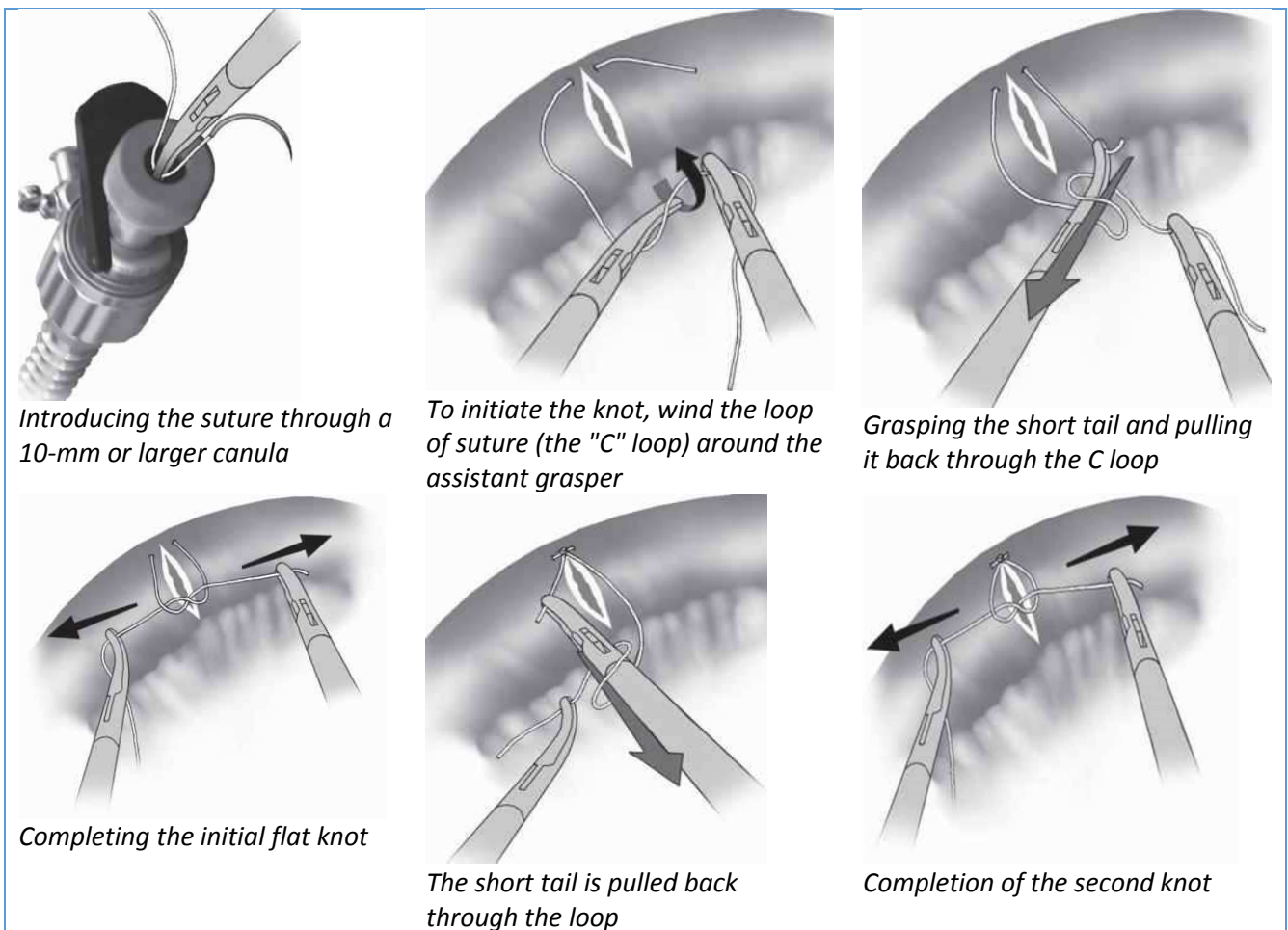


Figure 4.8.1. Suturing procedure

Slip knot. Use the needle holder to grasp the long tail and wind it three or more times around its axis. Then pull the short tail through the windings and tighten it to form the knot (Figure 4.8.2).

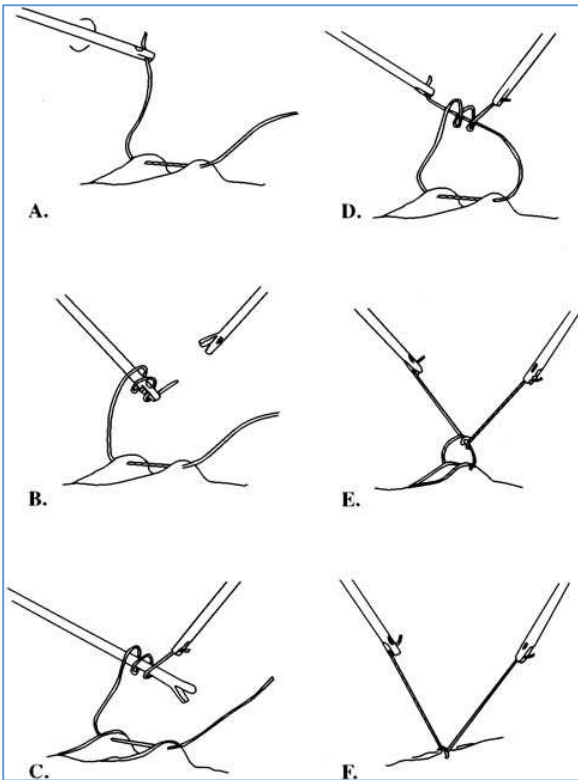


Figure 4.8.2. The slipknot procedure

Laparoscopic needle holders

There are several types of laparoscopic needle holder. The preference for the type of needle driver is depends on the user. The ergonomics of the needle holder influences the relaxation of the wrist, which is crucial for facilitating intracorporal maneuvers. The needle may have a curved handle or a straight handle, and a curved tip or a straight tip(Figures 4.8.3–4.8.5) There are also self-righting tips (Figure 4.8.6), which automatically right the needle co-axially to the tip.




Figure 4.8.3. A curved-handle needle driver and a straight handle needle driver




Figure 4.8.4. Straight-handle needle holder with curved tip



Figure 4.8.5. Straight tip



Figure 4.8.6. Self-righting tip

Suturing position

The ideal position for laparoscopic suturing is a triangular position with the laparoscope midway the working ports. The ideal angle between laparoscope and each handed instrument is 30 to 45 degrees. The target tissue (suture line) and the monitor should be positioned in line to maximize the surgeon's eye-hand coordination. To avoid causing any damage to the abdominal organs, it is important that the needle holders remain under the optic of the laparoscope, while the surgeon ties the knot (Figure 4.8.7).

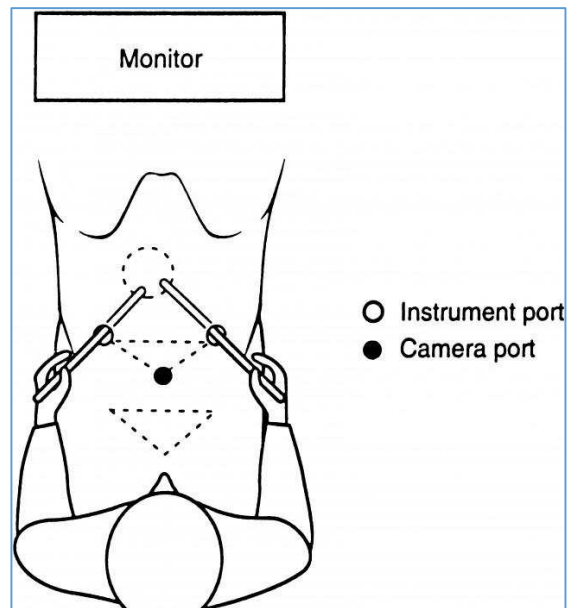


Figure 4.8.7. Ideal suturing position

Loop technique

It is possible to create a preformed loop as follows. Once the loop with the distal end of the suture around the final part of the suture thread is complete, introduce distal end a into loop c; then simultaneously pull the short tail and the needle end to tie the knot on the suture thread and to measure the length of the distal end that can be used as a suspension or retraction point (Figure 4.8.8).

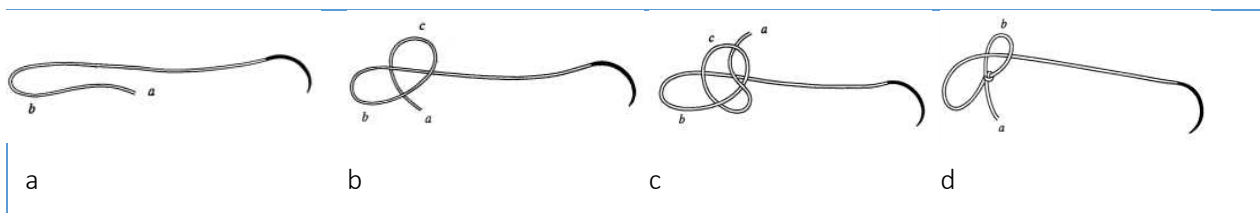


Figure 4.8.8. Creation of a preformed loop

Once the loop is complete, introduce the suture through the trocar and intracorporally create a second loop by pulling the needle end through the preformed loop d (Figure 4.8.8).

To prevent loosening or tying of the preformed loop during its passage through the trocar, grasp the preformed knot of the loop with the needle holder. Alternatively, insert the needle holder into the loop to prevent it from getting tighter. Barbed sutures have preformed loops (Figure 4.8.9).




Figure 4.8.9. Barbed suture with preformed loop (a), Intracorporal loop pulled through the preformed loop

Slip-loop

A slip loop can be made with three or four windings between the distal and medial ends of the suture. The result is a loop b through which the suture distal end a has been pulled (Figure 4.8.10). This generates a new loop d, through which the distal end of the suture a is pushed (Figure 4.8.10).

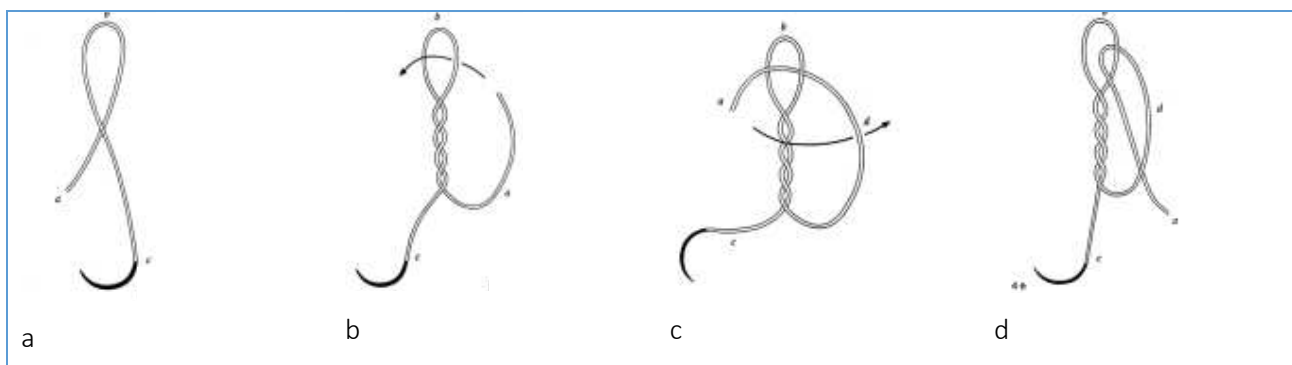


Figure 4.8.10. Creating a slip loop

Pull the distal end of suture a to tie the knot to make a slipknot. Pierce the tissues, then pull the needle through the slipknot. Tie the slipknot d by pulling the distal end of the suture or pushing on the knot itself (Figure 4.8.10).

An easier method to make a preformed loop is the following. When a braided thread is used, create a preformed loop simply by piercing the distal end of the suture with the needle a, exactly at its middle and at the required distance b (Figure 4.8.11). Then the needle is pulled through this newly formed loop to allow the tightening of the knot c (Figure 4.8.11). It is possible to measure the length of the final part of the suture, which can also be used as a retraction or suspension point.




Figure 4.8.11. A slip loop is created by piercing the distal end of the suture

Clip at end of the suture

A reabsorbable terminal clip can be placed at the distal end of the suture (Figure 4.8.12). The clip anchored to the suture thread functions as the initial knot and prevents the suture from rupturing through the tissue. This type of suture is recommended in partial nephrectomy. The clips prevent rupturing of the vulnerable renal cortex.

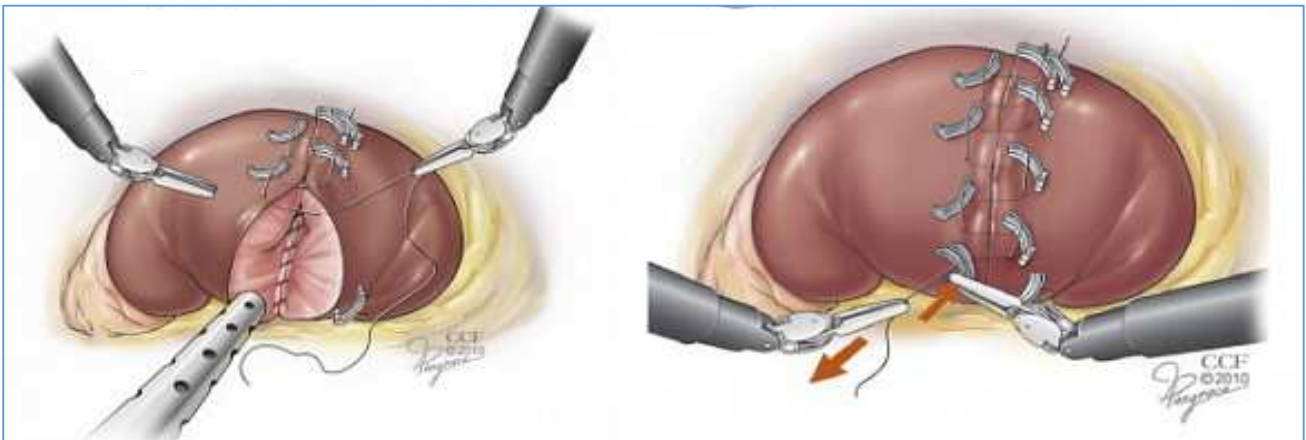


Figure 4.8.12. Suturing with reabsorbable clips in partial nephrectomy

Attach the second clip by pulling the suture and placing the clip at the tissue level (Figure 4.8.12). Interrupted stitches can be made in this way. Moreover, a continuous suture can be secured by placing a clip at the distal end of the suture (Figure 4.8.13). This technique is also useful if, at the end of the suture, the thread appears too short to make a final knot.

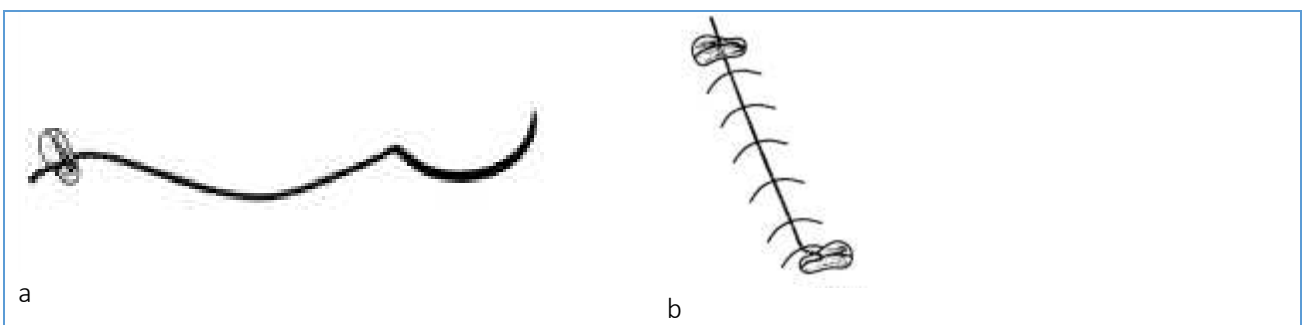


Figure 4.8.13 Continuous suture secured by clips

As alternatives, the final knot of a continuous suture can be made traditionally as in open surgery (two surgical knots in the same direction and a final one in the opposite direction). A final knot can be made by creating a loop. Keep this loop of the suture loose; then insert the needle holder into the loop by grasping the needle with the assistant needle holder. Grasp the suture thread at its middle and retract without allowing the grasper to drop the needle. Repeat this procedure twice. Let the needle guide the end of the suture through the last loop, and tighten the knot by retraction.

Recommendations

The surgeon must possess great manual dexterity to suture laparoscopically and tie a knot, since movement of the instruments and the intra-abdominal working space are limited. Suturing or making a knot in laparoscopy without the necessary experience and practice increases the duration of the operation. Attention should be paid to the ergonomics to facilitate suturing.

Adequate experience is achieved by practicing in a box (Chapter 4.4) or on a simulator, which must be done before one does any surgery in which these techniques are necessary. Every laparoscopic surgeon must learn these techniques.

Chapter 5. Procedure-specific aspects of laparoscopic and robotic surgery

5.1. Introduction

This chapter contains procedure-specific information. It provides consensus-based guidance for safe surgery. The standard preoperative work-up, including informed consent, is considered a standard of care and is therefore not described here.

5.2. Adrenalectomy

Hans Langenhuijsen, Frank d'Ancona

Indications

- Benign adrenal tumors
- Laparoscopic adrenal surgery for large (> 7 cm) and malignant tumors should be performed transperitoneally by experts only

The retroperitoneoscopic technique is feasible for patients with a BMI less than 35 kg/m² who either have tumors not greater than 7 cm or have previously had transperitoneal surgery. In the case of bilateral disease, the posterior retroperitoneoscopic approach makes repositioning the patient during surgery unnecessary. Posterior single-port adrenalectomy is feasible for very slim patients.

Contraindications

- Tumors greater than 10 cm (this is controversial)
- Medically unmanageable pheochromocytoma
- Adrenal cortical carcinoma (this is also controversial)

Preoperative preparation

- CT or MRI images must be available
- Alpha and beta blockades are required for pheochromocytoma patients
- A multidisciplinary approach achieved by a team including an endocrinologist, a specialist in nuclear medicine, an anesthesiologist, and a urologist

Preoperative instrumentation

- 30° Optic
- Balloon dilatation device – optional for the retroperitoneoscopic approach
- Ultrasonic dissectors
- Hasson or balloon trocar for the camera and one 10 mm or 12 mm trocar
- Endoclip device (5 mm or 10 mm), bipolar or Maryland grasper, Moynihan grasper
- Liver retracting device for the right adrenal gland
- Vicryl 0 suture (URS-6) for fascia, monocril 4-0 for skin

Preparation for surgery and positioning

- In transperitoneal surgery, the patient is in the lateral decubitus position on a vacuum mattress with extra lumbar support
- The lower arm is flexed; the upper arm is deviated cranially, and it rests on a leg support
- The knees and ankles are padded.
- In the posterior approach, the hips and knees are flexed at 45°, and the lower legs are resting on knee supports and gel pads
- A chest support device and a foam mask for the face are used
- Slight Trendelenburg position provides maximum stability of the patient

Retroperitoneoscopic surgery can be performed with the patient in the lateral decubitus position or in the prone jackknife position (Figure 5.2.1 and 5.2.2).

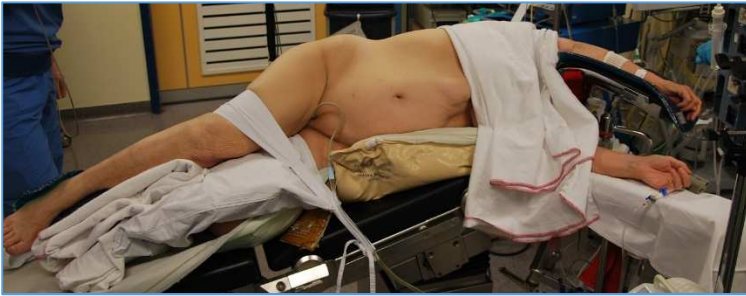

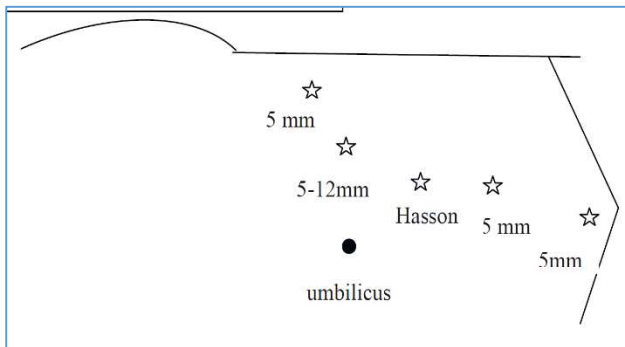
Figure 5.2.1. The lateral decubitus position for the right retroperitoneoscopic technique

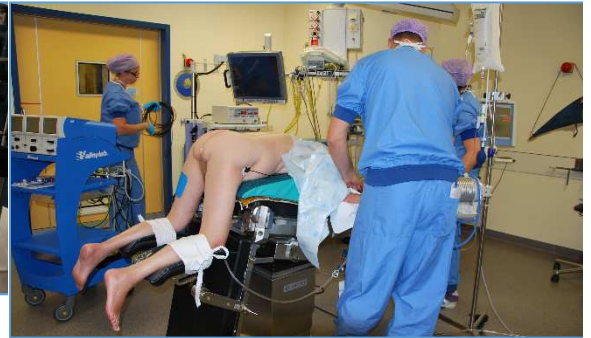

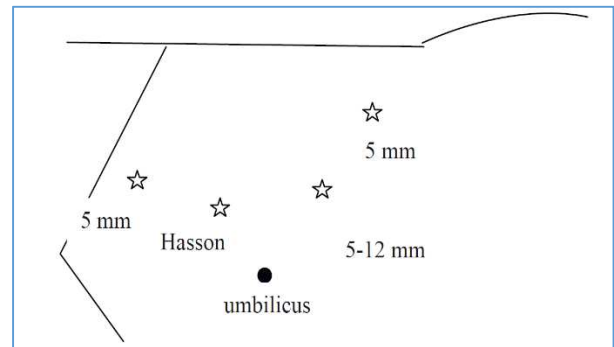
Figure 5.2.2. The jackknife position

Transperitoneal laparoscopy technique

- Skin incision for open Hasson trocar placement 2–4 cm cranio-laterally from the umbilicus (Figure 5.2.3a,b)
- Further trocar placements under direct vision
- Pneumoperitoneum at 12 mmHg
- Placement of a 5-mm trocar in the midclavicular line under the 12th rib
- Placement of a 5-mm trocar in the anterior axillary line above the iliac crest (optional)
- Placement of a 10-mm or 5 to 12-mm trocar between the iliac crest and the Hasson trocar
- On the right side, one extra 5-mm trocar is introduced below the xiphoid process for liver retraction.



a



b

Figure 5.2.3a,b. The lateral decubitus position for laparoscopic transperitoneal adrenalectomy: (a) right side and (b) left side

Right side

- Mobilize the liver by incising the peritoneum along the caudal liver edge. Dissect the triangular ligament, after which the liver is lifted with ratcheted grasping forceps attached to the diaphragm. Take an adequate bite to prevent rupture of the diaphragm
- Identify the ascending colon and open the white line of Toldt and the retroperitoneum
- Identify the kidney, duodenum, and caval vein
- Free the caval vein and release the duodenum. Direct preparation to the adrenal gland is often possible
- Find the renal capsule just above the renal hilum by identifying the renal artery and/or vein
- Identify the adrenal tissue, then dissect along the caudal plane of the adrenal gland with renal capsule. Use the no-touch technique in case of a pheochromocytoma
- Mobilize in a cranial direction by dissecting along the plane between the liver/peritoneum and the adrenal gland

- Identify and free the hilar adrenal vein on the medial side
- Critical view of safety: check the caval and adrenal veins
- Free and dissect the adrenal vein after double clipping
- Release the adrenal gland by dissecting along the dorsal plane towards the apex near the diaphragm
- Introduce the endobag and remove the specimen through the 5 to 12-mm trocar
- Check for hemostasis and leave a drain when necessary
- Release the diaphragm grasper and check for damage, then remove all trocars under vision
- Close the fascia incision for the 5 to 12-mm trocar with vicryl, and close the skin with monocryl

Left side

- Identify the descending colon, then open the white line of Toldt and the retroperitoneum
- Identify the kidney and mobilize the descending colon in the cranial direction from the lower pole of the kidney
- Use the splenopancreatic roll technique to mobilize the spleen and pancreas
- A spleen retractor is optional for the exposure to the left adrenal gland
- Identify the renal vein and the adrenal vein
- Critical View of Safety: check the renal and adrenal veins
- Free and dissect the adrenal vein after double clipping
- Dissect along the lateral plane between the adrenal gland and the renal capsule
- Dissect along the medial plane between the pancreas/spleen and the adrenal gland
- Lift the adrenal gland and dissect the dorsal adherences in the cranial direction towards the diaphragm
- Introduce the endobag and remove the specimen through the 5 to 12-mm trocar
- Check for hemostasis, and leave a drain when necessary
- Remove all trocars under vision
- Close the fascia incision for the 5 to 12-mm trocar with vicryl, and close the skin with monocryl

Retroperitoneoscopic technique with the jackknife position

- Skin incision under the tip of the 12th rib for open trocar placement (Figure 5.2.4)
- Open the thin fascia and the latissimus dorsi muscle layer with the finger to the point where it enters the retroperitoneal space
- Position the balloon dilatator or retract the peritoneum with the index finger
- After a space has been made, all the trocars are blindly placed on the internally positioned index finger
- Placement of a 5-mm trocar in the posterior axillary line under the tip of the 11th rib
- Placement of a 10-mm camera trocar at the lateral border of lumbar muscles, three fingers under the lumbocostal angle
- The last trocar is a balloon trocar under the tip of the 12th rib
- Pneumoretroperitoneum at 20 mmHg
- Create a space with the optic and identify the Gerota's fascia
- Open the Gerota's fascia and identify the kidney capsule
- Free the entire upper renal pole from lateral to medial
- On the medial side, pay attention to the hilum, and be aware of any upper pole arteries
- Identify the adrenal tissue after moving the upper pole of the kidney aside

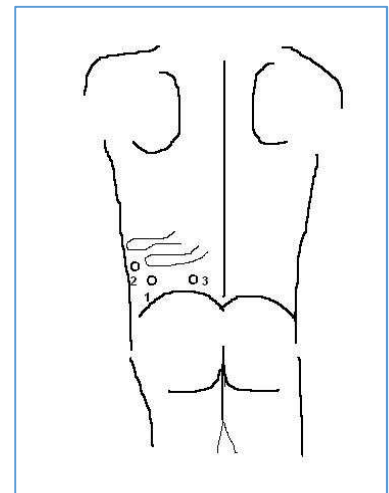


Figure 5.2.4. Trocar position in the left posterior retroperitoneoscopic technique
1 represents the 10-mm balloon trocar; 2 represents the 5-mm trocar; 3 represents the 10-mm camera trocar

- Dissect along the lateral (peritoneal) plane and the cranial (diaphragmatic) plane of the adrenal gland
- Free the medial plane of the adrenal gland and identify the caval vein on the right side and the adrenal vein
- Critical View of Safety: check the caval vein on the right side and the adrenal vein
- Free and dissect the adrenal vein after double clipping
- Dissect the dorsal adhesions of the quadratus lumborum and psoas muscles and remove the adrenal gland with the endocatch 10-mm device

Robot-assisted surgery

In adrenal surgery, the robot-assisted dissection technique is similar to the laparoscopic techniques, as already described.

Postoperative care

- Blood pressure and regular electrolyte control
- Consultation with the endocrinologist
- For pheochromocytoma, 24 hours of intensive care

Note that hypertensive crisis is a specific complication in pheochromocytoma. Careful consideration should be given to the fact that the learning curve for both the transperitoneal and retroperitoneoscopic approaches is about 20 cases.

Recommendations

- The no-touch technique should be used especially for pheochromocytoma and malignancies
- In the retroperitoneoscopic approach, mobilize the adrenal gland completely before dissecting the vein
- If the adrenal vein cannot be identified immediately in the transperitoneal approach, first mobilize the adrenal gland by dissecting along the plane with the kidney and/or with the liver/pancreas.

5.3. Nephrectomy

5.3.1. Laparoscopic partial nephrectomy

Geert Smits, Ben Knipscheer, Wout Scheepens, Patricia Zondervan

Indications

Partial nephrectomy is indicated for small renal tumors (≤ 4 cm), renal tumors in a solitary kidney, limited renal function, and Von Hippel Lindau disease. Partial nephrectomy can be considered for renal cell carcinoma >4 cm.(28, 31) However, partial nephrectomy is not suitable for:

- Locally advanced tumor growth
- Technical infeasibility (unfavorable location of the tumor)
- Impaired general health

Surgical technique

Retroperitoneal versus transperitoneal access

Whether retroperitoneal access or transperitoneal access is chosen depends on the tumor localization and the surgeon's experience. In general, lower pole tumors and interpolar tumors can be approached retroperitoneally. Upper pole tumors and more ventrally located interpolar tumors can be approached transperitoneally with more ease.

Robot-assisted partial nephrectomy versus laparoscopic partial nephrectomy

No difference in the oncological outcomes of these two types of partial nephrectomy has been reported so far. Two meta-analyses show comparable peri-operative outcomes, but a shorter warm ischemia time for robotic partial nephrectomy.(101, 102) Furthermore, there is no difference in the glomerular filtration rates between the two techniques.(103)

Hilar control

Hilar control is essential in partial nephrectomy. The hilar vessels can be temporarily clamped, but the warm ischemia time should not be more than 30 minutes to prevent irreversible loss of renal function.

The general technique for hilar control is arterial clamping of the renal hilum with laparoscopic bulldog clamps (Figure 5.3.1.1). Since the abdominal pressure is around 12 mmHg in laparoscopic surgery, venous clamping is not indicated. Non-clamping laparoscopic partial nephrectomy can be an alternative for superficial cortical tumors. If a long ischemia time (>30 minutes) is expected, cooling the kidney (e.g. with ice sludge) can protect it. Selective clamping is an alternative in this case.

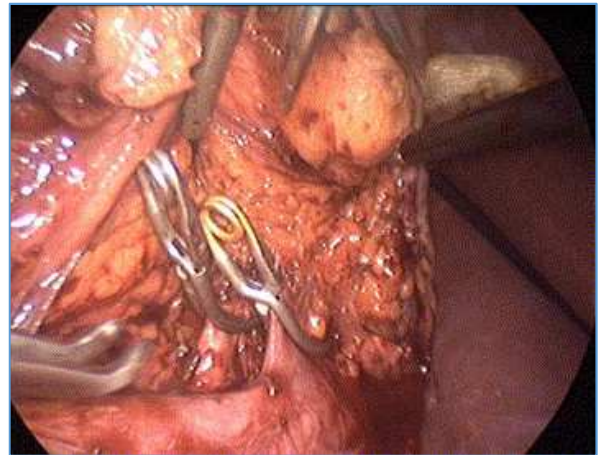


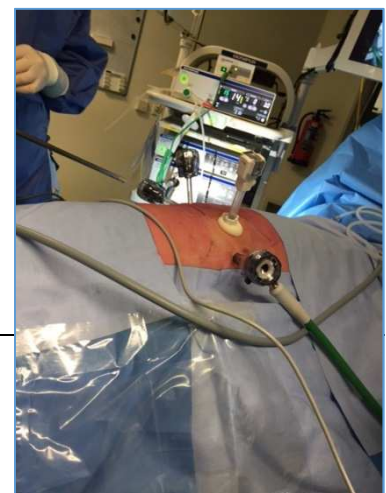
Figure 5.3.1.1. Hilar control

Extraperitoneal approach

Extraperitoneal partial nephrectomy

Here we describe the right extraperitoneal partial nephrectomy. The left extraperitoneal partial nephrectomy is identical except that it is mirrored.

Place the patient in the left lateral lumbotomy position on a vacuum mattress. Flex the operation table for maximum lumbar support to create space between the pelvic crest and the 12th rib. Place a pillow between the legs to prevent neuropraxy or decubitus. Flex the left hip and knee at about 90 degrees and see that the right leg is fairly straight to stabilize the patient.



Remove the posterior leg rest to make space for the surgeons. After secure positioning has been completed, activate the vacuum mattress, and place a security support against the pubic bone and the shoulders.

Make the first incision at the right Petit's triangle on the dorsal axillary line, about 2 cm below the 12th rib, just in front of the paraspinal muscles. Pass the four overlapping muscles (lattissimus dorsi, external oblique, internal oblique, and transverse abdominal muscles), which leaves a small space in between with only muscle fascia.

Perforate the subcutis and fascia with a clamp and spread until the index finger can pass through. Perform finger dissection of the extraperitoneal space. In general, the lower pole of the kidney, and sometimes even the renal artery, can be palpated.

Figure 5.3.1.2. Trocar

placement

Insert a dilating balloon trocar under vision with the 30° laparoscope (Figure 5.3.1.2). This expands the extraperitoneal space. Then the quadratus lumborum and psoas muscles, lower pole of the kidney, caval vein, gonadal vein, peritoneum, and ureter can be identified. The ilioinguinal and genitofemoralis nerves may also be seen.

Put a Hasson trocar or a blunt tip trocar in place, and insufflate with the maximum CO₂ pressure set at 12 mmHg. Place the other trocars under vision. Place a 5 to 12-mm trocar 1 to 2 cm above the iliac crest in the anterior axillary and mid-axillary line. Insert a 5-mm assistant trocar along the anterior axillary line below the 12th rib.

Identify the renal artery, place a vessel loop around it, and secure it with a clip.

To identify the tumor, remove the perirenal fat, as necessary depending on the localization of the tumor. Visualize the tumor and resect it with a margin of 0.5–1 cm. Resect the tumor and close the renal wound as described in the Section *Partial nephrectomy technique*.

Transperitoneal approach

Transperitoneal access makes anatomic structures more easily recognizable than extraperitoneal access.

Transperitoneal partial nephrectomy

We now describe the right transperitoneal partial nephrectomy. The left transperitoneal partial nephrectomy is identical except that it is mirrored.

Place the patient in the left lateral lumbotomy position with the shoulders turned about 200 degrees dorsally. Use a vacuum mattress. Only minimal flexion of the operation table, or none at all, is needed. Place a pillow between the legs to prevent neuropraxia or decubitus. Flex the left hip and knee at about 90 degrees and see that the right leg is fairly straight so as to stabilize the patient. After secure positioning has been achieved, activate the vacuum mattress, and place a security support against the pubic bone and the shoulders.

Make the first incision next to the rectal abdominal muscle on the right at 2–4 fingers cranially to the navel, depending on the patient's morphology. The more adipose tissue, the more cranially the first incision should be made. Place a 5 to 12-mm Hasson trocar or blunt tip trocar, and create the pneumoperitoneum at a maximum of 12 mmHg of CO₂ pressure.

Introduce the laparoscope, and place the other trocars under vision (Figure 5.3.1.3).

In the right-sided partial nephrectomy, place a 5-mm trocar below the xiphoid process used to introduce the liver retractor (small blue trocar at the right side of figure 5.3.1.4).

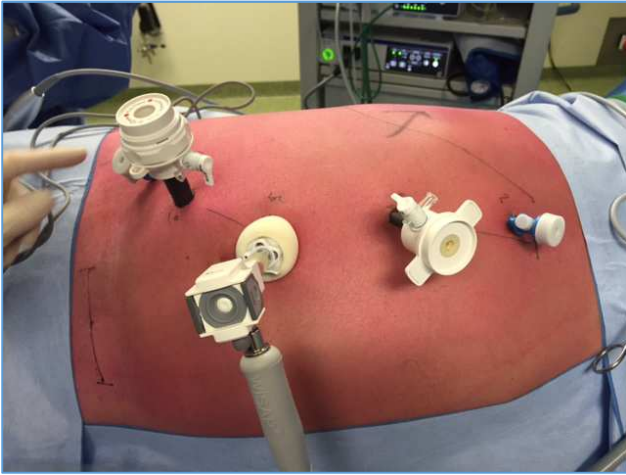


Figure 5.3.1.3. Trocar positioning

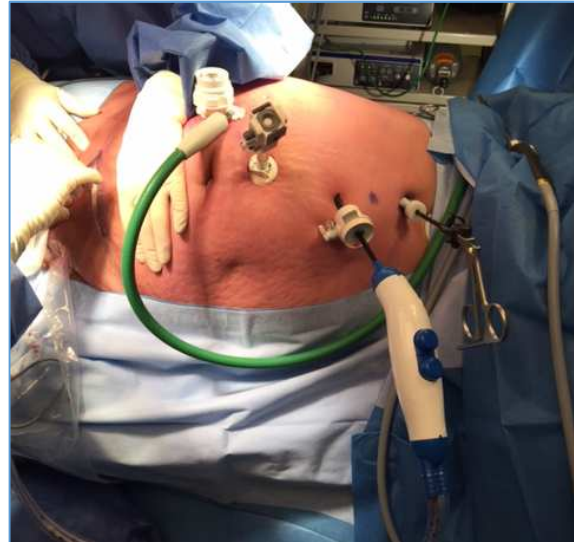

Figure 5.3.1.4. Trocar positioning in right-sided partial nephrectomy

Place a 5 to 12-mm trocar 1–2 cm subcostally next to the rectal abdominal muscle. Place a second 5 to 12-mm trocar in the lower abdomen on the right (between the camera trocar and the anterior superior iliac crest). Place a 5-mm trocar 8–10 cm laterally to the trocar in the lower abdomen.

During the right transperitoneal partial nephrectomy, the ascending colon and duodenum are medialized in the plane between Gerota’s fascia and the mesocolon and mesoduodenum. Now the caval vein and the renal vein can be located.

During the left transperitoneal partial nephrectomy, the descending colon is medialized in the plane between Gerota’s fascia and the mesocolon. Now the periaortic fat and the renal vein can be located.

Place a vessel loop around the renal vein. Then the renal artery can be located and looped as well.

Remove the perirenal fat to identify the tumor, depending on its localization. Visualize the tumor and resected it with a margin of 0.5–1cm. Resect the tumor and close the renal wound as described in the Section *Partial nephrectomy technique*.

Partial nephrectomy technique

Place a bulldog clamp on the renal artery. Then resect the tumor with cold scissors, starting medially to prevent blurring from blood flow. Remove the tumor and place the specimen in an endobag. To suture the resection site, use a 2.0 absorbable barbed wire with an 18-mm 4/8 needle and a clip. Secure it with a knot.

Place the first stitch through the renal capsule to achieve maximum support of the clip and to avoid non-absorbable clips near the collecting system. Then close the collecting system and the deep renal vessels with the barbed wire. Use the running suture technique for this purpose. Run the final stitch through the renal capsule again and secure it with a clip.

Tissue sealant can be applied. If so, place a wet gauze on it for 2–3 minutes, and remove the bulldog clamp. This is known as “early unclamping”, and it results in a limited warm ischemia time.

To close the parenchyma, introduce a second 2.0 absorbable barbed wire 25 cm with a 26-mm 4/8 needle, and a clip 10 mm at the end after a knot. Place every stitch through the renal capsule, and change the direction of the running suture after each step (right \geq left, left \geq right) to prevent diagonal traction of the suture through the renal tissue. Place a clip on the suture to prevent capsule rupture after each stitch through the capsule. Secure the final stitch with two clips to prevent sliding.

Remove any vessel loops and gauze. Check for hemorrhage and introduce a wound drain. Extract the specimen bag.

5.3.2. Radical nephrectomy

Paul Verhagen, Brunolf Lagerveld, Anko Kooistra, Geert Smits, Wout Scheepens

Applicable guidelines

- EAU guidelines on renal cell carcinoma(28)
- EAU guidelines on robotic and single-site surgery in urology(29)
- Laparoscopic Radical Nephrectomy(104)

Indications

- Renal cell carcinoma, other malignant tumors of the kidney, or strong suspicion of malignancy. A partial nephrectomy is advisable for renal cell carcinoma <4 cm
- A symptomatic afunctional kidney

Possible contraindication

Partial nephrectomy should be considered, irrespective of the tumor size, in the case of a renal tumor in a solitary functioning kidney.

Preoperative preparation

Mark the skin on the surgical side. A recent CT scan or MRI should be available in the operation room. Pre-operative Hb, irregular antibodies and contralateral kidney function should be checked. Anticoagulants, other than acetylsalicylic acid, must be stopped.

Instrumentation

Dilatation balloon (retroperitoneal approach), 0 or 30 degrees optic, bipolar grasper, scissors, fenestrated grasper, suction device, trocars, endobag, clip applier, stapler, ultrasonic device.

Preparation for surgery and positioning

Insert a bladder catheter. Place the patient on his/her side, flex the operation table (lumbar level), and stabilize the position with a bean bag. For the transabdominal procedure, position the abdomen of the patient at the edge of the operation table. For the retroperitoneal approach, position the back of the patient at the edge of the table (figure 5.3.2.1).

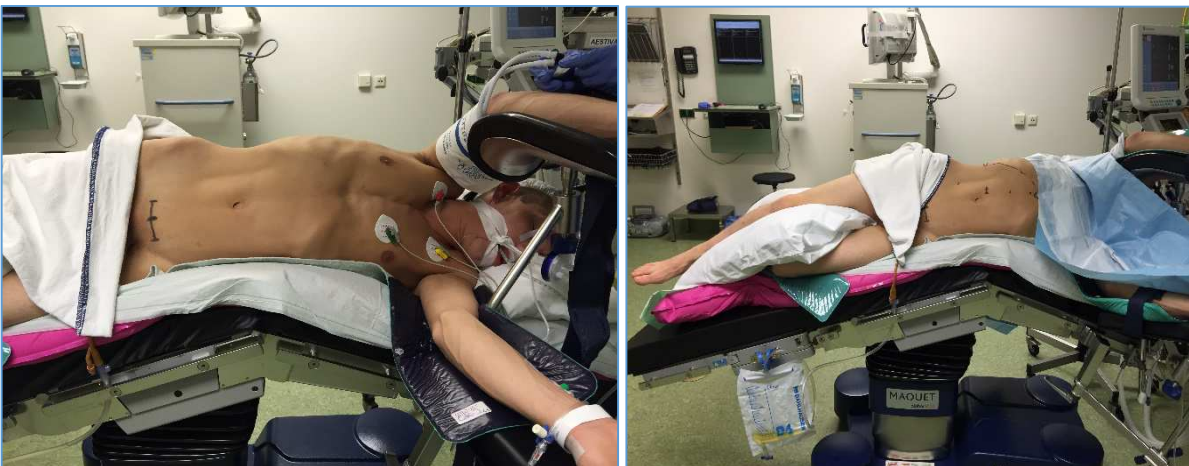

Figure 5.3.2.1. Patient positioning

Team check

Be sure that instruments and a retractor are quickly available in case unexpected conversion to open surgery becomes necessary.

Transperitoneal laparoscopic technique

Trocars. Usually, three trocars are placed for the dissection. We describe only one of the multiple ways trocars can be placed. With the Hasson technique, place the first trocar laterally to the rectus at the level of the

navel (12 mm). Place a second trocar caudally, and a third between the navel and the xiphoid process. Place all ports more laterally in obese patients, so that there is enough length for the laparoscopic instruments to reach the dorsal side of the kidney. The adrenal gland is standardly not removed with the kidney.(28, 105) Only if there is direct contact between the tumor and the adrenal gland, or if the appearance of the adrenal gland on preoperative imaging is abnormal, is the adrenal gland removed en bloc with the kidney. A standard lymphadenectomy is not performed. However, if enlarged nodes are present in the renal hilum, they are removed.(28, 106)

Mobilization of the colon: left side. Incise the white line of Toldt from the caudal side to the cephalad side. Start at the level of the iliac vessels and proceed to the spleen. Take care not to incise Gerota's fascia lateral to the kidney, otherwise the kidney will drop medially, making the dissection of the renal hilum more difficult.

Mobilization of the colon: right side. Push the liver away with a 5-mm instrument (Babcock or Ellis) inserted via an extra trocar near the xiphoid process. Incise the peritoneum over the white line of Toldt to above the hepatic flexure of the colon. This is done under slight medial traction.

Dissection of the ureter. After mobilization of the colon, the psoas muscle can be identified. The ureter and gonadal vessel can also be identified in this area. The ureter can be touched to check for peristalsis. Afterwards the ureter can be followed in the direction of the lower pole of the kidney and renal hilum.

Identification of the renal hilum. After the lower pole has been identified, it and the ureter are lifted together. Blunt dissection is used to identify the renal vessels.

Critical view of safety and renal vessels. The upward tension on the renal vessels is used to bluntly and sharply dissect the renal vein (ventral) and artery (dorsal). If a large renal vein is present, a vessel loop can be placed around the vein to expose the renal artery. Before the division of the renal vessels, an image showing the renal artery and vein entering the kidney (critical view of safety) must be stored. Then, transect the renal artery and vein after occlusion with clips or a stapling device. Self-locking clips can be used here, but double clips are necessary on the aortic and caval sides, and remaining a vessel cuff is crucial to prevent slipping of the clips. Alternatively, an endovascular stapler can be used. The artery and vein can be divided at once with a stapler. Ensure that the vessels are side by side and the tip of the stapler is free.

Mobilizing the kidney. After transection of the renal vessels, continue the dissection in the direction of the upper pole of the kidney. Only resect the adrenal gland if it is abnormal or attached to the renal mass. The ureter can be transected. After the kidney is totally free of all its attachments, place it in an endobag.

After the kidney had been bagged, check for hemostasis and intra-abdominal injuries. Remove the instruments under direct vision, and extract the endobag. Placing a drain is not standard procedure. Suture the trocar sites >5 mm.

Retroperitoneal laparoscopic technique

The retroperitoneal approach is preferable for a non-functioning kidney and for kidneys with small to intermediate tumors. The transabdominal approach is preferable for large tumors. First make an incision anteriorly and slightly caudally to the tip of the 11th or 12th rib. Push the peritoneum away from the abdominal wall. Use a balloon trocar to create a space between the kidney and the quadratus lumborum muscle. Place a posterior 5-mm trocar dorsally. Place a 10-mm trocar ventrally while taking care of the peritoneum. Medially, free the Gerotas connections to the quadratus lumborum muscle. Identify the ureter, the renal artery, and the renal vein. As in the transperitoneal procedure, an image of the critical view of safety (renal artery and vein are visualized entering the kidney) must be stored before transection. Transect the renal artery and vein. Self-locking clips can be used for this, but double clips are necessary for the aortic and caval side, and

remaining a vessel cuff is crucial to prevent slipping of the clips. When the kidney is completely free of its attachments, it is placed in an endobag and taken out via the enlarged anterior trocar site.

Robotic radical nephrectomy

The robotic procedure mimics the transabdominal laparoscopic procedure already described. Various systems for trocar placement have been reported: some use a three-arm approach, and some use a four-arm approach. Place the trocars in the following positions: a semicircular line extending from the anterior superior iliac spine to the xiphoid process. If three instruments are to be used, place two trocars caudal to the camera trocar, and place one trocar cephalad to the camera trocar (figure 5.3.2.2). It is not necessary to place an extra instrument on the right side to keep the liver in place because this can be accomplished with the right robotic instrument if the trocar placement is cephalad and below the costal arch. The renal vessels are closed by the assistant using a stapler or clips. According to the EAU guidelines, robotic assistance may be considered “technical overtreatment” because of the increased procedure time and costs without any clear benefit.(28)

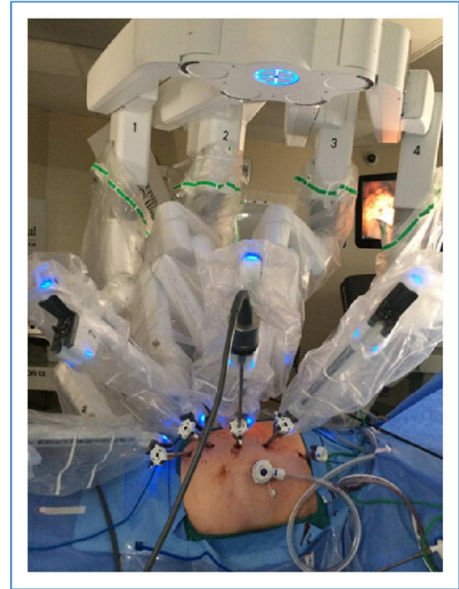


Figure 5.3.2.2. Trocar positioning

Postoperative care

Attention must be paid to anemia and the remaining kidney function on the first postoperative day. The risks of infection, missed bowel injury during the procedure, and postoperative development of wound herniation are low, but do sometimes occur. In the case of delayed recovery or persistent pain located at a trocar site, an intra-abdominal problem may be present, so that further lab investigations, imaging, or a laparoscopic exploration may be indicated.

General and specific complications

Complications are infrequent. They include hemorrhage, postoperative ileus, wound infection, trocar site hernias, wound dehiscence, and injury of abdominal organs (bowel, spleen, liver, pancreas, and adrenal gland).

5.3.3. Donor nephrectomy

Frank d'Ancona, Hans Langenhuijsen

Introduction

Living donor nephrectomy is an important alternative to hemodialysis for patients with end-stage renal disease. There is level 1 evidence that laparoscopic donor nephrectomy (LDN) is superior to open donor nephrectomy.(107)

Hand-assisted laparoscopic donor nephrectomy (HALDN) and hand-assisted retroperitoneoscopic (HARP) donor nephrectomy start with one of the incision techniques for the handport. In the HARP technique, the retroperitoneal space is created first. In the HALDN technique, the colon is mobilized and displaced medially. The vascular structures are then further dissected and prepared. *Pure retroperitoneal donor nephrectomy* is performed with the donor placed in the lateral decubitus position. Balloon dilatation or digital creation of the retroperitoneal space is performed to create a working space. *Robot-assisted donor nephrectomy* can be performed with or without hand assistance. The patient is placed in the lateral decubitus position for this surgery.

Most laparoscopic donor nephrectomies in the Netherlands currently employ the pure LDN procedure or the hand-assisted technique. Living donor nephrectomy is always performed by two qualified surgeons.

Indications

Eligibility for donation depends on many factors such as renal function and the calculated rest function after donation, age, and absence of comorbidity and urological pathology, as well as recipient factors.

The LDN technique is preferable in most cases since the donating patient population is healthy most of the time. The HARP procedure can be considered an alternative technique with the same outcome in terms of patient comfort and complication rate for patients with a history of abdominal surgery or pathology.

Pre-operative work-up

After the nephrologic work-up has been completed, a CT of the abdomen with iv contrast according to the vascular protocol or a magnetic resonance angiogram is performed. The decision on which side of the donor the nephrectomy is to be performed is based on the rule to leave the best kidney with the donor.

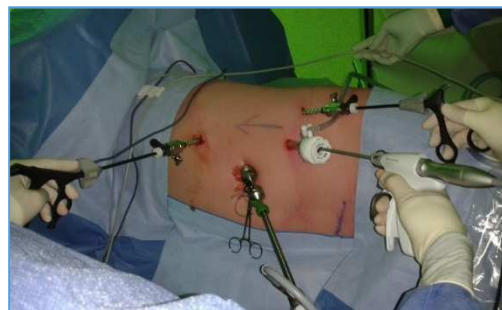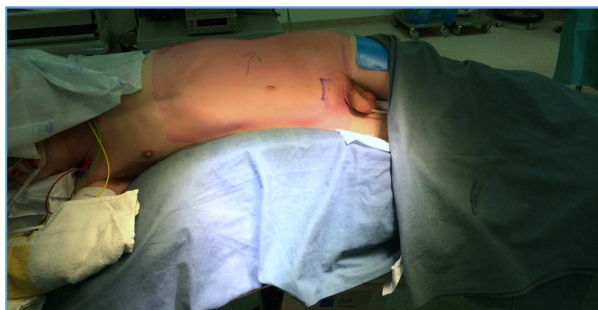Instruments required:

- 30° Optic
- Video monitoring and recording system
- Bipolar grasper
- Scissors
- Fenestrated atraumatic grasper
- Suction device
- 10-mm camera trocar, 5 to 12-mm trocar, two to three 5-mm trocars
- Endobag
- Clip appliers, 5 mm and 10 mm
- Stapler
- Ultracision
- Separate table ready for perfusion and transportation system with ice
- Gelport

Patient positioning:

- The adequately relaxed donor receives a gastric tube and transurethral catheter
- The Pfannenstiel incision is marked (7-8 cm) while the patient in the supine position (before the patient is placed in the decubitus position)

- The donor is placed in the lateral decubitus position with the table extended to accommodate the donor's anatomy (Figures 5.3.3.1 a and b)
- The donor's arms are placed in the cranial direction
- A bean bag and table supports at the back of the patient are used for fixation
- Adequate padding in the back, arm, and leg areas is the responsibility of the surgeon and anesthesiologist



a *b*
Figure 5.3.3.1 a, b. Patient positioning, for left sided donor nephrectomy

Team check:

- The briefing and time-out procedure are carried out according to hospital protocol. Both donor information and recipient information are important at this time
- The team should have experience with this procedure, and a conversion set should be available immediately
- Both surgeons should be able to convert to open nephrectomy

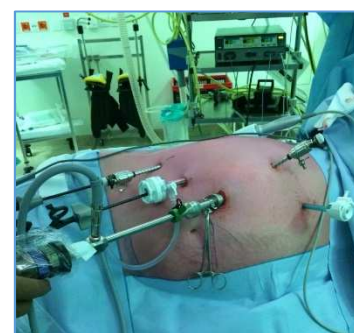

Figure 5.3.3.2. Example of right-sided donor nephrectomy

The transperitoneal donor nephrectomy technique

In LDN, a 10-mm trocar is introduced under direct vision. The abdomen is insufflated to a pressure of 12 mmHg with carbon dioxide. A 30° video endoscope and three to four additional trocars are introduced (figures 5.3.3.2, 5.3.3.3 and 5.3.3.4). The colon is mobilized and displaced medially. The ureter and the gonadal vein are identified and carefully dissected. Then the renal artery and vein are dissected in the cranial direction, and possibly the lumbar and adrenal veins as well. The renal artery and vein are dissected at the maximum length with 5-mm or 10-mm self locking clips. An ultrasonic device makes opening Gerota's fascia and the division of the perirenal fat easier. The ureter is transected and clipped at the level of the iliac artery; then a Pfannenstiel incision is made. An endobag is introduced into the abdomen and the kidney is pre-bagged. The renal artery and vein are divided with an endoscopic, non-cutting stapler to provide optimal vascular length. Then they are divided as medially as possible. Extraction follows directly through the Pfannenstiel incision. The kidney is then immediately perfused and the warm ischemia time is registered.

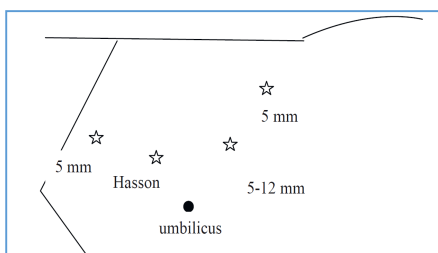


Figure 5.3.3.3. The procedure of laparoscopic donor nephrectomy for the left kidney

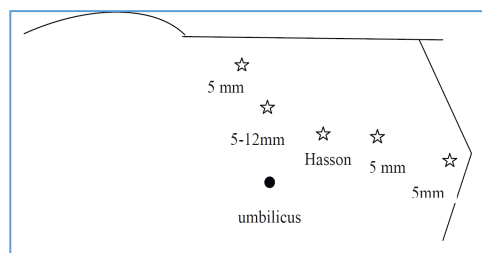


Figure 5.3.3.4. The procedure of laparoscopic donor nephrectomy for the right kidney

The technique for hand-assisted retroperitoneal donor nephrectomy

The HARP procedure starts with a 7 to 10-cm Pfannenstiel incision. After blunt dissection to create a retroperitoneal space, the gelport is inserted. The blunt introduction of the first trocar between the iliac crest and the handport is guided by the operator's hand inside the abdomen. Carbon dioxide is insufflated retroperitoneally to 12 mmHg pressure. A 5-mm trocar and a 5 to 12-mm trocar are inserted just outside the midline inferior to the costal margin and in the flank, to create a triangular shape. The kidney and renal vessels are dissected in a procedure similar to that of transperitoneal donor nephrectomy, but with hand assistance, and it is done from a slightly different angle. The kidney is removed manually.

Postoperative care

The gastric tube is removed immediately after surgery. The transurethral catheter is removed the moment the patient can be mobilized. This is usually on day 2 postoperatively. Except for heavy abdominal straining, there are no limitations for the patient. Renal function, blood pressure, and urine analyses by urinary sediment are routinely followed up.

Complications

The overall complication rate is low for donor nephrectomy, but 8% of the complications include mainly late postoperative wound infections, seroma in HARP, urinary tract infection, pneumonia, and postoperative port-site hernias. Theoretically, all the complications of regular nephrectomy can occur. The chance of conversion to open surgery due to major problems is less than 1%.

Tips and tricks

- The splenopancreatic roll at the left side can be helpful when the upper pole of the kidney is adherent and in a high position
- At the right side, the liver is lifted with the help of an extra 5-mm port introduced just below the xiphoid bone. Then a grasper is introduced just under the liver and the lower part of the liver is lifted to fix it to the lateral abdominal wall
- To approach the renal vessels, first the ureter and the gonadal vein are identified. They are pursued in the cranial direction. To speed the dissection, one can easily introduce a grasper and transect just behind the renal artery and vein. Then flip the kidney medially and the perirenal tissue can be dissected more easily just above the grasper
- Using the clips: a single clip can dislocate very easily. Try to use two clips at each vessel site.

5.4. Cryoablation

Pilar Laguna, Patricia Zondervan

Introduction

The current European Association of Urology guidelines and American Urological Association guidelines contemplate cryoablation for cT1a renal tumors as an alternative treatment to partial nephrectomy or as active surveillance of patients with a high surgical risk.(28, 31) Both guidelines advocate biopsy of the tumor before or during cryoablation. A percutaneous approach is currently more common than the laparoscopic cryoablation used in the past.(108, 109)

Cryoablation is based on the Joule-Thomson effect; for this purpose, argon is used for freezing and helium, for thawing.(110) Two consecutive cycles of freezing with active and passive thawing are recommended to achieve cellular death.(111) Gas is conducted through thin needles (1.47 mm or 17 Gauge). Both the tumor and a margin of at least 5 mm around the tumor should be frozen. The lethal temperature is below -40°C for the whole tumor mass and the surrounding healthy tissue. The temperature must be monitored and modulated throughout the procedure. Thawing is necessary before needle removal to avoid complications such as tearing, fracture, and hemorrhage.

Patient selection and indications

The candidates for cryoablation are patients with relative contra-indications for laparoscopic partial nephrectomy. Patients with familial syndromes such as Von Hippel Lindau and Birt-Hogg-Dubé are also candidates for cryoablation because of the increased risk of developing multiple synchronic or metachrone tumors. Cryoablation is highly effective in small tumors (cT1a). Percutaneous cryoablation is preferable, and usually CT guided; however, there are some indications for laparoscopic cryoablation:

- Anteriorly located tumors necessitating intestinal mobilization
- Tumors near the ureter
- Upper pole tumors

Contraindication. There is a relative contraindication for larger tumors ($>cT1a$), although cryoablation for larger tumors has been described.(112-114)

Preoperative preparation

A contrast-enhanced CT scan is needed to plan the procedure precisely and to determining the required number and size of needles (Figure 5.4.1).

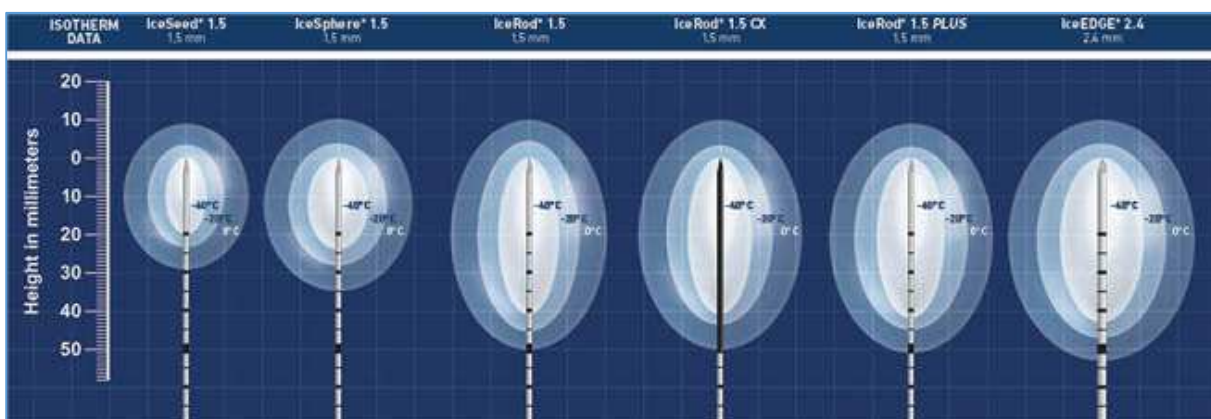


Figure 5.4.1. Different types and sizes of the available cryoneedles

In the case of an endophytic tumor, or a tumor close to the pyelocaliceal system or the ureter, consider putting in a JJ stent before starting the operation.

Preoperative instrumentation

- Full equipment for cryoablation
- Full bottles of argon and helium (Figure 5.4.2)
- Cryoneedles
- Laparoscopic equipment: 0 or 30-degree scope, trocars (5 mm and 10 mm), laparoscopic bipolar grasper, scissors, graspers, and suction device.

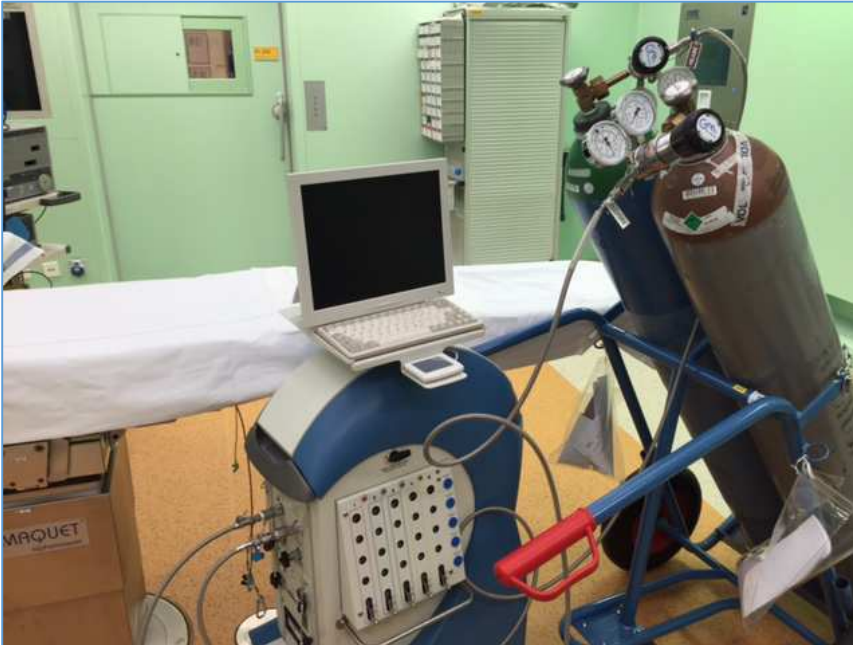

Figure 5.4.2. Helium and argon bottles connected to the cryo-device in the operating room

Preparation for surgery and positioning

The patient must be under general anesthesia. A bladder catheter is inserted, and the patient is placed on the lateral side. The operation table is flexed at the lumbar level, and the patient's position is stabilized with a roll and bands or a bean bag. The abdomen is positioned near the edge of the operation table (Figure 5.4.3) for the laparoscopic trans-abdominal procedure. The back of the patient is positioned near the edge of the table for the retroperitoneal approach.

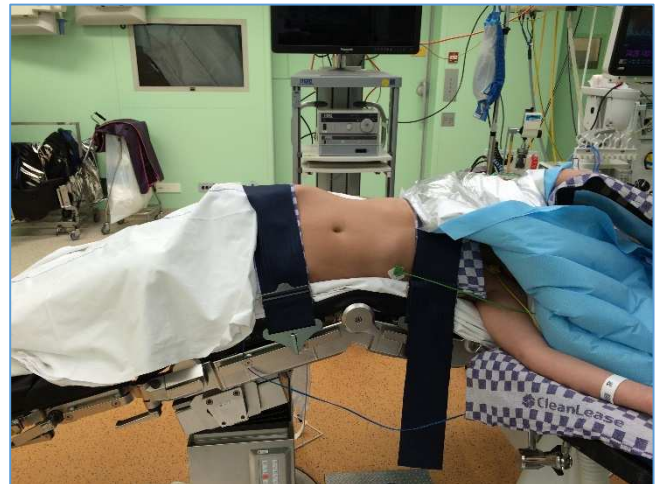

Figure 5.4.3. Positioning of the patient and the operation table

Team check

- Antibiotic prophylaxis 1 hour before surgery begins
- Special attention should be paid to the patient's temperature during the freeze-thaw cycle
- The necessary instruments and a retractor must be readily available in case conversion to open surgery becomes necessary.

Transperitoneal or retroperitoneal laparoscopic procedure

- Access to the kidney can be either transperitoneal (for anterior tumors) or retroperitoneal (for posterior tumors). However, the percutaneous approach is preferable for posterior tumors.

- Suggestions for trocar placement
 - Transperitoneal: use the Hasson technique to place the first trocar (12 mm) lateral to the rectus abdominis muscle and a few centimeters in the cranial direction to the level of the umbilicus. A second trocar (5 mm) is placed in the caudal direction in the fossa, and the third trocar (5 mm) is placed in the cranial direction to the first trocar, just below the ribs.
 - Retroperitoneal: the first trocar is placed 1 to 2 cm lateral to the 12th rib. A dilation trocar is used to create the retroperitoneal space, then a balloon trocar (12 mm) is placed. The second and third trocars (5 mm) are placed in the anterior and posterior axillary line.
- Exposure of the tumor: in the case of the transperitoneal approach, access to the retroperitoneum is achieved by incision of the white line of Toldt and mobilization of the colon. Gerota's fascia is opened to visualize the tumor, and perinephric fat is removed around the tumor. Fat on the tumor may be offered for pathologic examination.
- Cryoablation: percutaneous cryoneedles are placed with laparoscopic assistance (Figure 5.4.4).

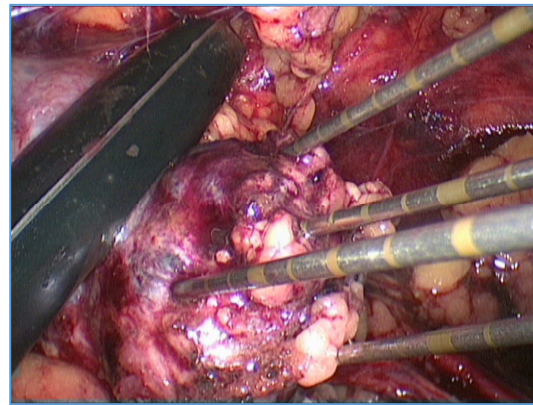
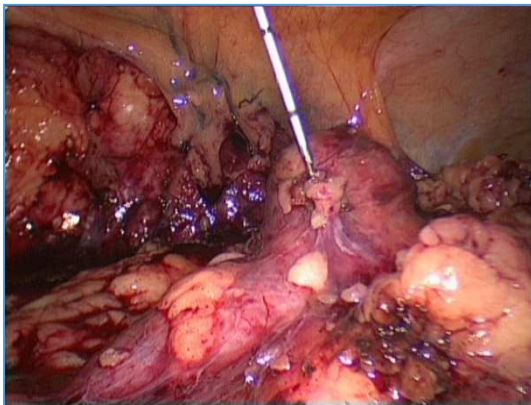
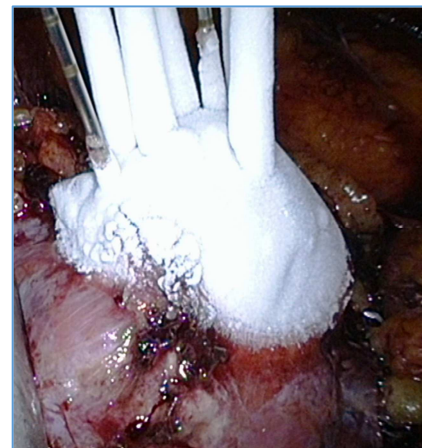


Figure 5.4.4. Laparoscopic placement of the cryoneedles under laparoscopic vision and ultrasonography (black probe)

- The needles should be placed 5 mm beyond the margin of the tumor. The laparoscopic ultrasound probe is used to measure exact tumor size and the correct placement of the needles. The thermo-sensor probe is placed a few centimeters outside the tumor (Figure 4.5.5).



the

Figure 4.5.5. The iceball, with a thermo-sensor (the needle not covered with ice), intra-operatively placed next to the tumor

- The initial freezing with argon lasts 10 minutes. This is followed by 5 minutes of thawing, which consists of 4 minutes of passive thawing and 1 minute of active thawing with helium. Then there is another 10 minutes of freezing, 5 minutes of passive thawing, and 4 minutes of active thawing. During the ablation, the iceball can be monitored by vision, temperature, and ultrasonography (Figure 5.4.6 a-c).

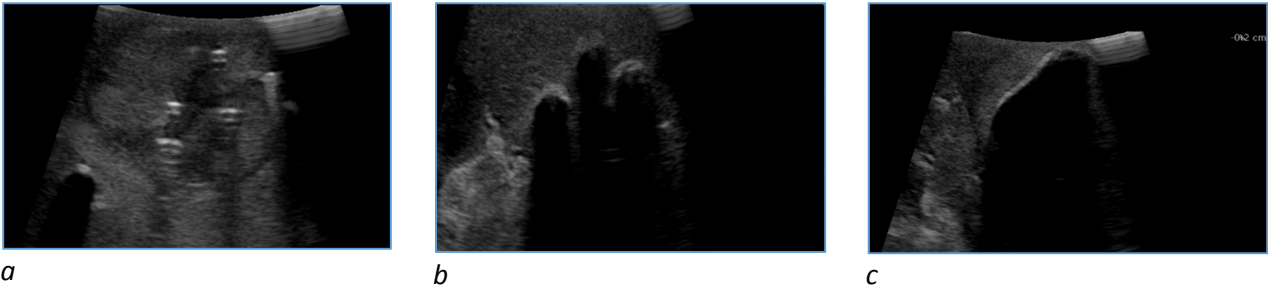


Figure 5.4.6a-c. Ultrasound assistance during laparoscopic cryoablation: (a) needles have been placed (white spots); (b) the beginning of the freezing process shows the beginning of the iceball (dark zone); (c) an iceball has been created

Care must be taken to prevent bleeding when the needles are removed. If needed, hemostatic agents can be used to stop bleeding from the tumor.

In postoperative care, check the hemoglobin and the serum creatinine. The bladder catheter can be removed 1 day postoperatively.

Complications

Complications related to cryoablation include infection, bleeding from the tumor, a burst iceball, and damage to the collecting system or ureter. Postoperatively, patients can have flank pain that is attributable to needle placement. In the case of the ablation of a huge tumor, there can be an episode of fever due to the release of endotoxins.

Follow-up recommendation

Three months after cryoablation, a contrast-enhanced CT should be performed to evaluate the effect of the cryoablation.

Recommendations

Successful cryoablation depends on:

- Correct and careful placement of the needles
- Completion of two freeze-thaw cycles
- Visual control of the iceball extension at least 5 mm beyond the tumor limits.

5.5. Pyeloplasty

Wout Scheepens, John Rietbergen, Ad Hendrikx

Introduction

Laparoscopic pyeloplasty has been the gold standard for the treatment of ureteropelvic junction (UPJ) obstruction for some years now, and it has fully replaced open pyeloplasty. It can be performed transperitoneally or retroperitoneally, as well as with robotic surgery.

Applicable guidelines

- EAU Guidelines on Pediatric Urology(34)
- EAU Guidelines on Robotic and Single-site Surgery in Urology(5)

Indications

Once the diagnosis of ureteropelvic junction (UPJ) obstruction has been made, the type of management depends on the severity. Indications for pyeloplasty are:

- Renal colic
- Recurrent urinary tract infections
- Ipsilateral nephrolithiasis
- Deterioration of renal function

Contraindications

If the renal function of the ipsilateral kidney is less than 20% and the other kidney is functioning well, consider nephrectomy instead of pyeloplasty.

Preoperative instruments

- Dilatation balloon for the retroperitoneal approach
- 0 or 30° Optic
- Bipolar grasper
- Scissors
- Selected graspers
- Suction device
- Trocars, bag, clip applier, and needle driver
- Ultrasonic or bipolar device.
- Suture material
- Double J stent
- Post-operative drain

Preparation for surgery and positioning

A bladder catheter and a nasogastric tube are inserted. The patient is placed in the lumbotomy position with the ipsilateral side up (Figure 5.5.1). The position is stabilized with a bean bag. The abdomen of the patient is positioned at the edge of the operation table for the trans-abdominal procedure. The back of the patient is positioned at the edge of the table for the retroperitoneal approach.

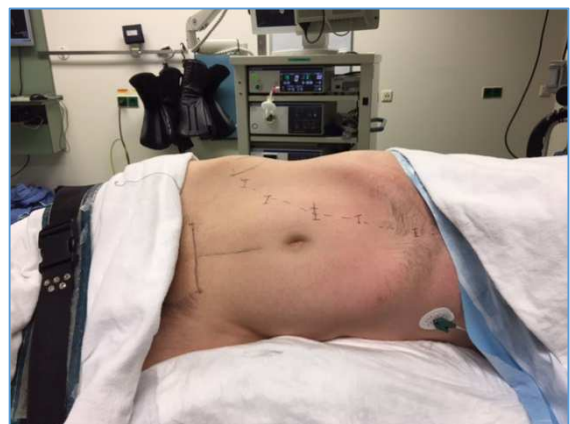

Figure 5.5.1. Patient and trocars positioning

Team check

The necessary instruments and a retractor must be available in case of an unexpected conversion.

Transperitoneal laparoscopy technique

Three trocars are usually placed for the dissection. There are multiple possibilities for trocar placement. We describe one here, but other approaches are possible. The Hasson technique is used to place the first trocar (12 mm) (Figure 5.5.2). It is placed laterally to the rectus abdominis muscle at the level of the umbilicus. A second trocar is placed in the caudal direction, and a third is placed between the umbilicus and xiphoid process. All trocars are placed more laterally in obese patients.

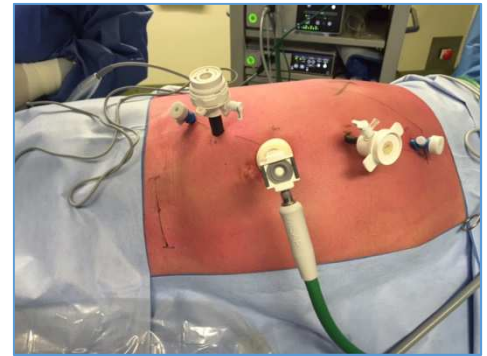


Figure 5.5.2. Positions of the trocars

Surgical steps:

- Medialize the colon to visualize the lower pole of the kidney
- Open Gerota's fascia to visualize the UPJ
- Transect the proximal ureter
- Resect the redundant pelvis
- Spatulate the ureter 1.5 cm at the lateral margin
- Create the anastomosis ventrally if crossing vessels are present
- Use a barbed wire for the dorsal anastomosis
- Insert a 7 Fr JJ stent in an antegrade fashion
- Complete the ventral anastomosis
- Close the pelvis
- Leave a drain at the site of the anastomosis

Retroperitoneal laparoscopy technique

Trocar placement (Figure 5.5.3)

- The first 10-mm trocar for the scope is placed at the extremity of the 12th rib
- The second 10-mm trocar is placed above the iliac crest in the mid-axillary line
- The 5-mm trocar is placed on the anterior axillary line midway between the two other ports
- A 10-mm optional trocar can be placed in the anterior axillary line just below the rib margin.

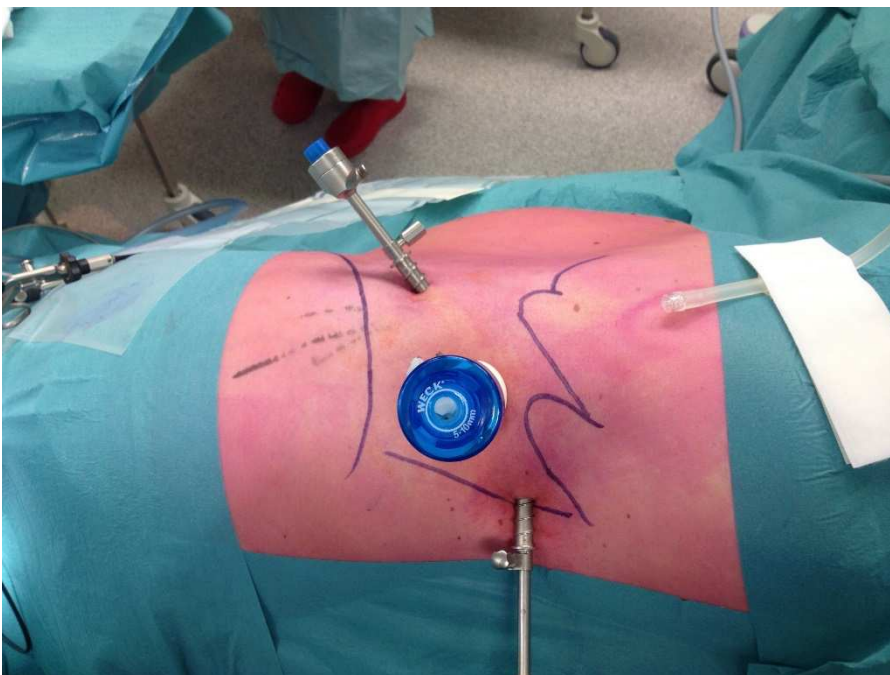


Figure 5.5.3. Trocar placement in retroperitoneal laparoscopic pyeloplasty

An open procedure is used to place the first trocar. Blunt dissection with the scope tip or with a space balloon trocar is used to develop the retroperitoneal space. The next trocar can be placed either (1) under vision or (2) with palpation with the index finger in the wound of the first port and blunt dissection of the retroperitoneal space. Then the other trocars can be introduced, also with palpation.

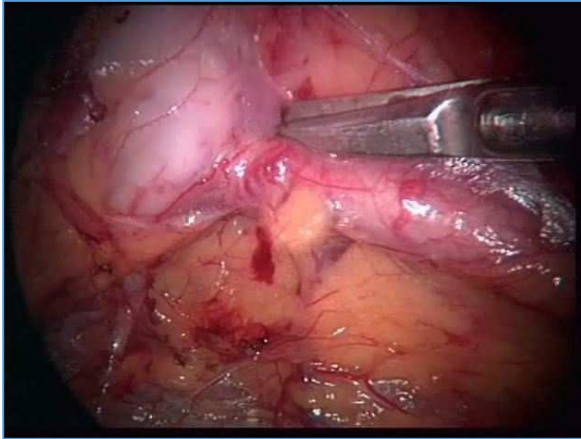


Figure 5.5.4. Visualization of the UPJ. The scissors point to the pyelum on the left side; the proximal ureter runs at the right side.

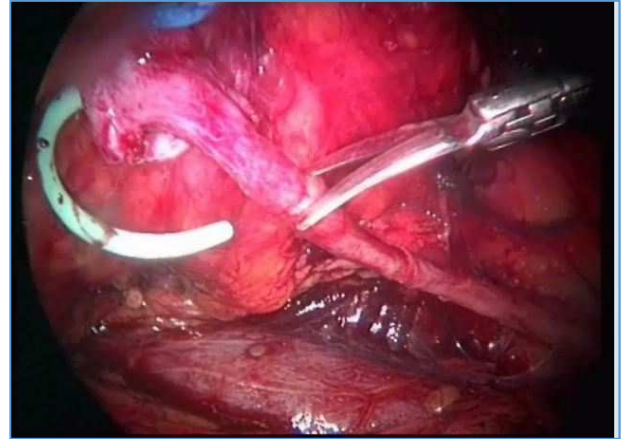


Figure 5.5.5. Excision of the UPJ stenosis with double J stent in situ

After trocar placement, the psoas muscle is the most important landmark. The kidney is approached posteriorly. The renal hilum can be observed. The renal pelvis is exposed. Complete mobilization of the UPJ and the pelvis is necessary before excision (Figure 5.5.4). Crossing vessels can complicate retroperitoneal pyeloplasty. If an Anderson Hynes pyeloplasty is performed, an anastomosis posterior to the crossing vessels is advisable. However, many surgeons omit the transposition of the anastomosis and achieve similar results.(115) The techniques for JJ stenting and drain placement are similar to the transperitoneal technique (Figure 5.5.5).

Robotic surgery technique

The patient is placed in a full-flank position with the ipsilateral side up (Figure 5.5.6). The operating table is then flexed to create a working space for the robot arm. The ipsilateral arm is placed as low as possible to allow the robot arm to work parallel to the body.

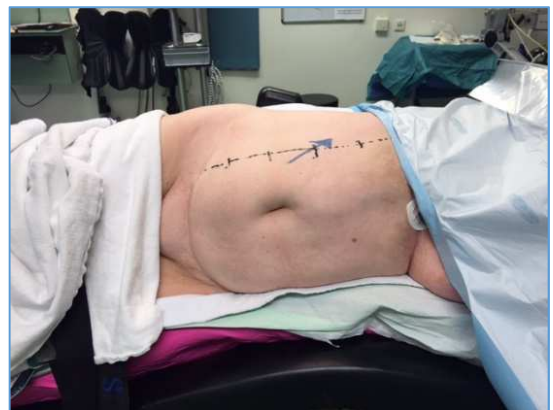

Figure 5.5.6. Patient and trocars positioning

The introduction of the camera trocar is through the umbilicus or slightly more laterally towards the UPJ. The distance between the camera port and the 8-mm ports is at least 8 cm to avoid collision (Figure 5.5.7).

The technique is similar to the technique in the laparoscopic transperitoneal approach. A retroperitoneal approach is feasible, but due to a small working space, it is technically challenging. Care must be taken in tissue handling since there is no tactile feedback in the robotic instruments.

Currently, no randomized trials have shown a difference in clinical outcome between the laparoscopic technique and the robot-assisted technique.(62) The robotic technique is more expensive. Ergonomic aspects are the main reason for the use of a robotic platform.

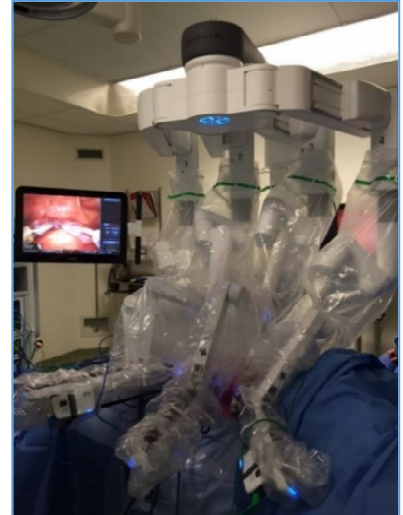

Figure 5.5.7. Connection to the robot

Postoperative care

The nasogastric tube is removed immediately after the surgery. After the catheter has been removed, the drain is observed for urinary leakage. If the drain production increases after removal of the catheter, a creatinine determination of the drainage fluid can distinguish between serum and urine. If the drain leaks urine, the indwelling catheter is replaced for 1 week. The JJ stent is usually left in situ for 6 weeks. Radionuclide renography is used for evaluation 3 months after surgery.

General and specific complications

The specific complications are similar to those of the open procedure.(116) Intraoperative incidents have been found to range from 2.0% to 2.3% in large series. Reported complications include ligation of a lower pole artery, bowel injury, bleeding, hypercapnia, loss of a needle, and transection of the JJ stent.(117)

Blood loss during the procedure is usually minor (less than 100 ml) and blood transfusion is rarely required.(118) The bleeding can be stopped with coagulation or clipping, depending upon the size of the vessel. Major bleeding originating from a hilar vessel should be stopped with suturing to prevent kidney ischemia. The conversion rate to open surgery has been found to range from 0.5% to 5.5%, mainly because of the inability to access the UPJ or to accomplish anastomosis.(117)

Postoperative complications occurred between 12.9% and 15.8% in large series. Grade III complications occurred in 5.4% to 10% of the cases; these complications included urine leakage, hematoma, bowel lesion, and stone formation.(117) Hematuria may occur; but it generally it subsides. If bladder tamponade occurs, rinsing with a 3-way catheter is advisable, and blood clots should be evacuated.

The JJ stent can cause colic pain, which can be treated with anticholinergics. Incisional hernias are rare when the fascia of the ports greater than 5 mm is closed. Recurrent UPJ stenosis requiring re-intervention occurred in 3.5% to 4.8% of the cases.(117)

5.6. Robot-assisted radical prostatectomy (RARP)

André Vis, John Rietbergen, Ron van den Brom, Sjoerd Klaver, Carl Wijburg, Jean-Paul van Basten, Ben Knipscheer

Introduction

Robot-assisted radical prostatectomy (RARP) is the most frequently performed robot-assisted procedure in the Netherlands and worldwide. Over 1600 RARP procedures took place in 16 hospitals in the Netherlands in 2015. Currently, 70% of the radical prostatectomies in the Netherlands are done robotically. Altogether, 573 robot systems have been installed in Europe to date, and an estimated 46,000 radical prostatectomy procedures were performed robotically in 2015.

RARP is technically challenging and requires specific surgical skills. An experienced urologist needs an estimated 20 to 40 procedures to master using the robot. Nonetheless, at least 500 procedures are required to achieve optimal clinical results with RARP.(119)

This chapter describes and illustrates the key surgical steps of RARP. However, a safe, uneventful, and successful RARP is not just a matter of “copy and paste”. It is essential to a successful RARP program to have a dedicated operating team and more than 50 procedures annually to overcome the steep learning curve.(120) In the Netherlands, a hospital must carry out a minimum of 20 procedures annually to be eligible for a contract with the healthcare insurers.(121) The Dutch federation of patients with prostate cancer recommends at least 50 procedures annually. An increase of the minimum volume of RARPs is expected.

Applicable guidelines

- Dutch Guideline for Prostate Carcinoma (33)
- EAU Guideline for Prostate Cancer(122)

Indications

The only indication for RARP is histologically proven and localized prostate cancer (PCa) in men with a life expectancy of at least 10 years. The aim of RARP is an oncologically safe cure with preservation of urinary continence and erectile function.

Men younger than 65 years with low-risk PCa (T1c-2a Gleasonsum < 7, prostate-specific antigen (PSA) < 10 ng/mL) may benefit from RARP, whereas men older than 70 years with low-risk PCa probably do not. Although an age of less than 70 years is generally accepted as the threshold for prostatectomy, there is no strict age limit. Weighing the threat of PCa death in relation to the estimated life expectancy is paramount in counseling for RARP.

RARP should be offered to men with an intermediate risk of PCa (cT2b or Gleasonsum 7 or a PSA of 10–20 ng/m) and a life expectancy of more than 10 years. RARP can also be offered to men with high-risk prostate cancer (cT2c-T3 or Gleasonsum > 7 or PSA > 20 ng/mL) as initial treatment, even when extra prostatic tumor is suspected.

According to the European Association of Urology guidelines, RARP for intermediate- and high-risk PCa should be combined with extended pelvic lymph node dissection if the estimated risk of lymph node metastasis exceeds 5% according to the MSKCC nomogram (<https://www.mskcc.org/nomograms/prostate>).

In the case of low- and intermediate-risk PCa, nerve sparing RARP can be attempted for men with little risk of extra prostatic disease and normal erectile function. A preoperative multiparametric MRI may be helpful for deciding whether to perform nerve-sparing RARP. Nerve-sparing RARP can be offered to selected patients with high-risk PCa and a minor risk of extra prostatic tumor extension, i.e. anteriorly located PCa.

Contraindications

Table 5.6.1 shows the specific contraindications for RARP, and Table 5.6.2 shows the relative contraindications. Neither obesity nor prior abdominal and prostate surgery is a self-contained contraindication. Urologists with experience in robotic surgery can perform RARP in these challenging cases. Table 5.6.3 shows the relative contraindications for novices in RARP. In table 5.6.4 the relative contraindications for a nerve-sparing procedure are listed.

Table 5.6.1. Absolute contraindications for RARP

Elevated intracranial pressure
Uncorrected elevated intra-ocular pressure
Unstable ischemic heart disease
Heart valve disease
Left-ventricular ejection fraction < 15%
Uncorrected coagulation and/or bleeding disorders

Table 5.6.2. Relative contraindications for RARP

Severe chronic obstructive pulmonary disease ($FEV_1 \leq 50\%$)
Prior major pelvic surgery or irradiation
Prior major pelvic trauma
Peritoneal dialysis
Morbid obesity ($BMI > 40 \text{ kg/m}^2$)
Expected operation time of more than 6 h

BMI, body mass index; FEV_1 , forced expiratory volume in 1 s

Table 5.6.3. Relative contraindications for novices in RARP

Prior inguinal hernia repair with use of mesh
Prior transurethral resection of the prostate
Prior high-intensity focused ultrasound or cryosurgery of the prostate
Salvage prostatectomy following brachytherapy
Large median lobe
Prostate size > 150 mL

Table 5.6.4. Relative contraindications for a nerve-sparing procedure

High risk prostate cancer (cT2c-T3 or Gleasonsum > 7 or PSA > 20 ng/mL)
Capsule contact of the tumor more than 15 mm on MRI
Fixation of the neurovascular bundle to the prostate
Positive intra operative frozen sections of the neurovascular bundles

PSA, prostate-specific antigen

Preoperative preparation and anaesthesia

There is no optimal time span between a biopsy diagnosis and surgery(123). No studies have demonstrated the biopsy-to-surgery interval to be an independent factor of positive surgical margin status, operative time,

or estimated blood loss. However, there is a study that advises an interval between prostate biopsy and RARP of at least 6 weeks.(124)

Patient history and physical examination

The risks and complications of the procedure are discussed with the patient. This discussion should at least include the perioperative or postoperative subjects of:

- Risks involved with general anesthesia
- Adjacent organ injury
- Blood loss
- Infection
- Conversion to open surgery
- Erectile dysfunction
- Urinary incontinence

For any extended pelvic-lymph-node dissection, the risks of vascular lesions (of the external iliac artery and external iliac vein), neural lesions (of the nervus obturatorius or nervus genito-femoralis), and ureteric lesions need to be addressed.

A medical history is taken and a physical examination, including digital rectal examination and abdominal inspection, is performed. Special attention is given to the presence of cardiopulmonary and other comorbidities, current sexual function, previous abdominal surgery, allergies, intoxications, and the use of medication (especially anticoagulants). The Charlson comorbidity Index can be used to estimate life expectancy.(125)

The anesthesiologist or urologist advises patients to discontinue anticoagulant medication 1 day to 1 week before surgery, depending on the type of anticoagulant medication. Continued use of non-steroidal anti-inflammatory drugs (NSAIDs) such as diclophenac is not associated with increased occurrence of bleeding. Continuation of the use of thrombocyte aggregation inhibitors is advisable because it helps prevent adverse cardiovascular and thrombotic events.

Bowel preparation and diet

Bowel preparation and rectal enemas are not given preoperatively in the Netherlands. There is a strict “nothing by mouth” policy on the day of surgery starting 6 h before RARP.

Antibiotic prophylaxis

Since RARP is a procedure with an open urinary tract (i.e. a clean-contaminated procedure), a single course of antibiotic prophylaxis with a second- or third-generation cephalosporin is recommended; for instance, cefazolin 1 g intravenously at the start of surgery.

Preparation for surgery and positioning

Patient positioning and prevention of sliding

Since both the anesthesiologist and the urologist are responsible for proper positioning, they must check and secure positioning on the operation table, once general anesthesia has been induced in the patient. Because patients are in a steep Trendelenburg position and the robotic arms are fixed, measures have to be taken to prevent sliding during surgery. Bean bags, anti-sliding mattresses, or yoke pillow can be used to prevent sliding.

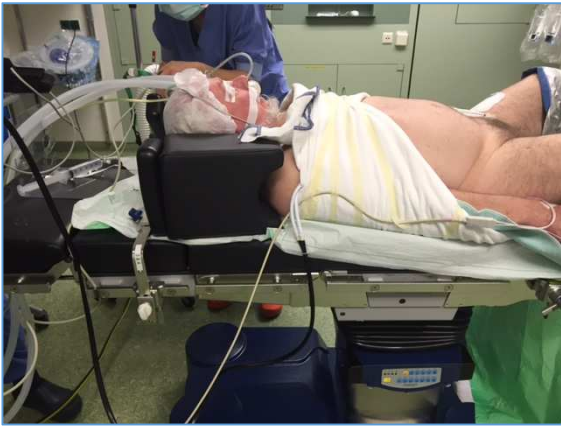

Figure 5.6.1. Fixation of the patient

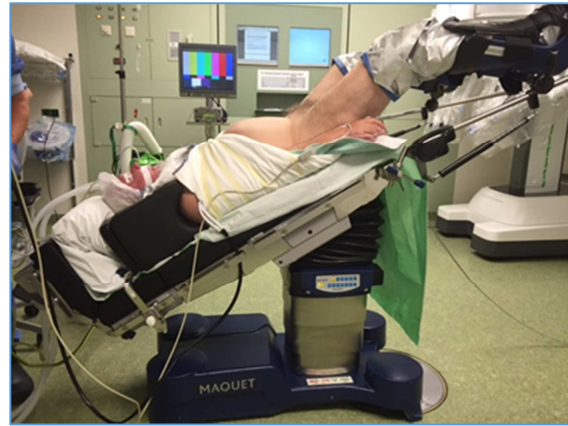

Figure 5.6.2. Steep Trendelenburg position

Padding the pressure points in arms and legs

Head, arms, and shoulders. The robotic scope can injure the face, eyes, and nose. Face protection such as a mask, a bar, and foam pads will reduce the risk of injury. The shoulders should be free of tension to prevent brachial plexus lesion.(126) Special attention should be given to the positioning and padding of arms and fingers because the robotic arms, operation table, and leg holders may clash and harm (Figures 5.6.3 and 5.6.4).

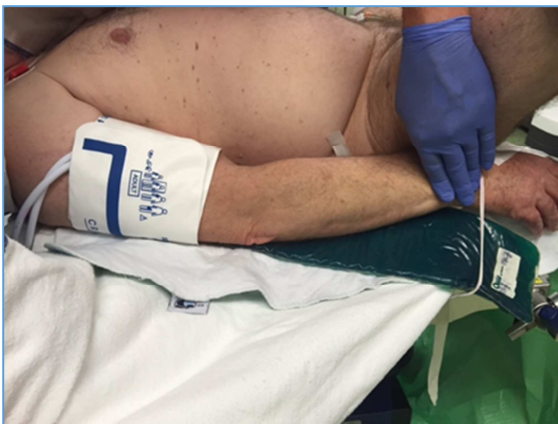

Figure 5.6.3. Padding of arms

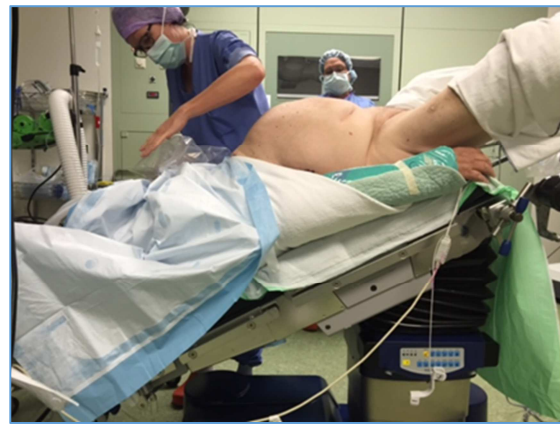

Figure 5.6.4. Padding of arms (2)

Anesthesiologic wires (e.g. intravenous support, arterial lines, and saturation devices) must be secured and passed upwards to the anesthesiologic devices.

Hips and legs. If the patient cart of the robot is positioned between the legs, the legs are placed and padded within the leg holders (Figure 5.6.5). Hips and knees are flexed slightly.

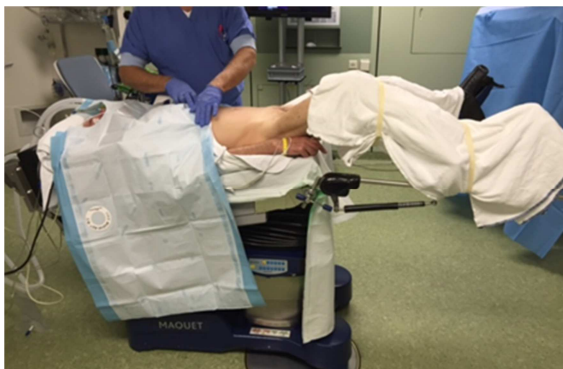

Figure 5.6.5. Legs within leg holders

Robot-assisted radical prostatectomy (RARP) technique

The RARP technique has evolved substantially in the last decade. Binder performed the first RARP in Germany in 2001, then Menon and colleagues refined the procedure.(127, 128) Other urologists have further developed the surgical technique on the basis of their own experience and preferences. Nonetheless, the different RARP techniques have similar oncological and functional outcomes. We now describe the “Ohio State University technique”.(129)

Step 1. Patient positioning: supine position, legs in leg holders, hips en knees flexed, arms alongside the body, head fixed (Figure 5.6.6). The Trendelenburg position must be tested to ensure stable positioning of the patient and to ensure ventilation if needed.

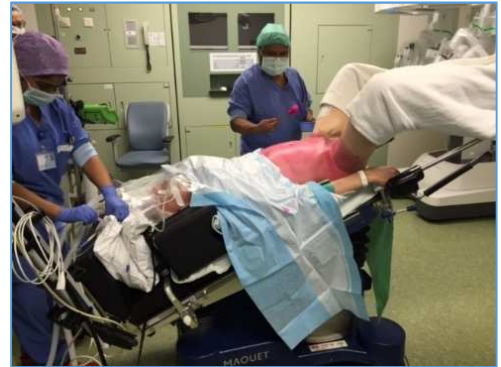

Figure 5.6.6. Final patient positioning

Step 2. Trocar placement and docking of the robot: An 8–12 mm camera trocar is placed approximately 3 cm cranial to the umbilicus. The Hasson open technique is preferable for inserting the camera trocar (Figures 5.6.7 until 5.6.9).

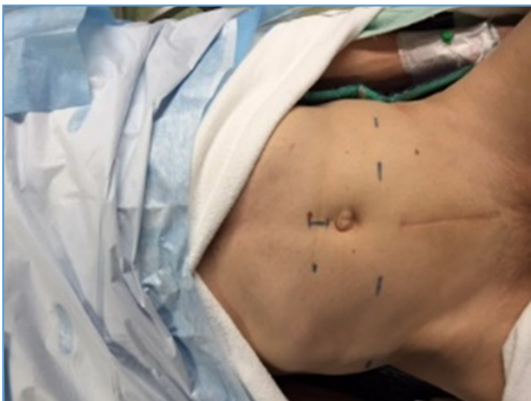

Figure 5.6.7. Trocar positioning

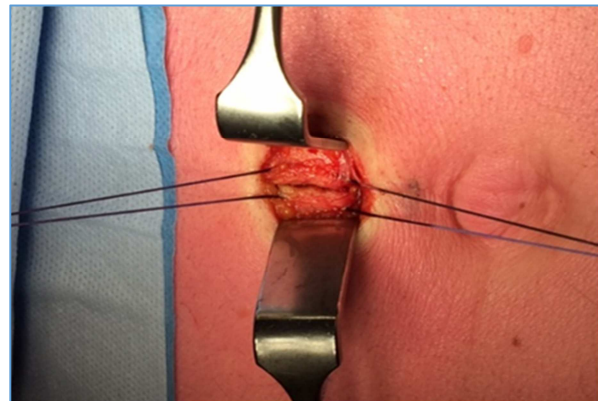


Figure 5.6.8. Hasson open technique, rectal fascia

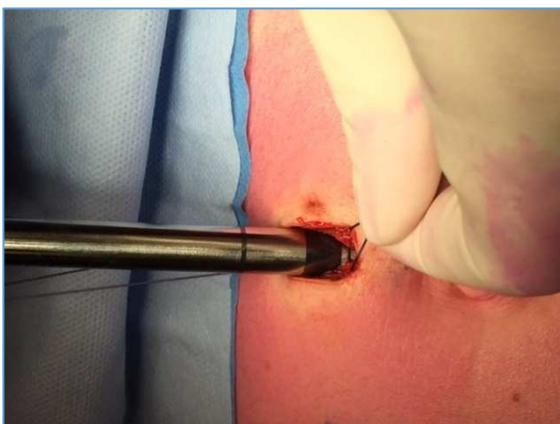

Figure 5.6.9. Open introduction of first trocar

Left lateral to the camera trocar, two 8-mm robot trocars are introduced (approximately at 8 cm - “a hand width” - intertrocar distance) (Figures 5.6.10 and 5.6.11).

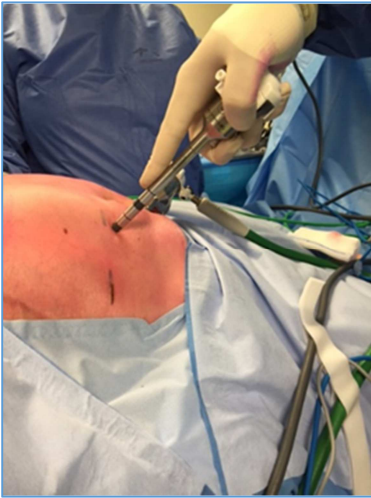

Figure 5.6.10. Safe introduction along index finger

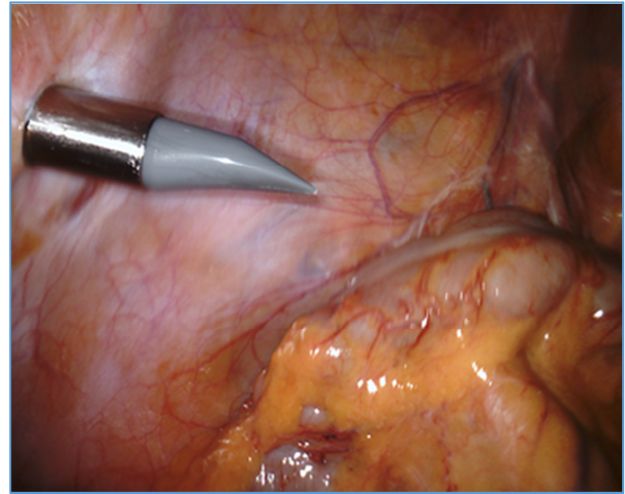


Figure 5.6.11. Intra-abdominal visualization while introducing trocar

The third robot trocar is placed on the right side, again approximately 8 cm from the camera trocar. Alternatively, two robot trocars (8 mm) could be placed on the right side and one 8 mm robot trocar on the left side, if the surgeon and his assistant prefer it. An assistant trocar (12 mm) is placed lateral to the single robot trocar. A 5-mm suction trocar is placed between the camera trocar and the first robotic trocar (on the assistant's side) (Figure 5.6.12).

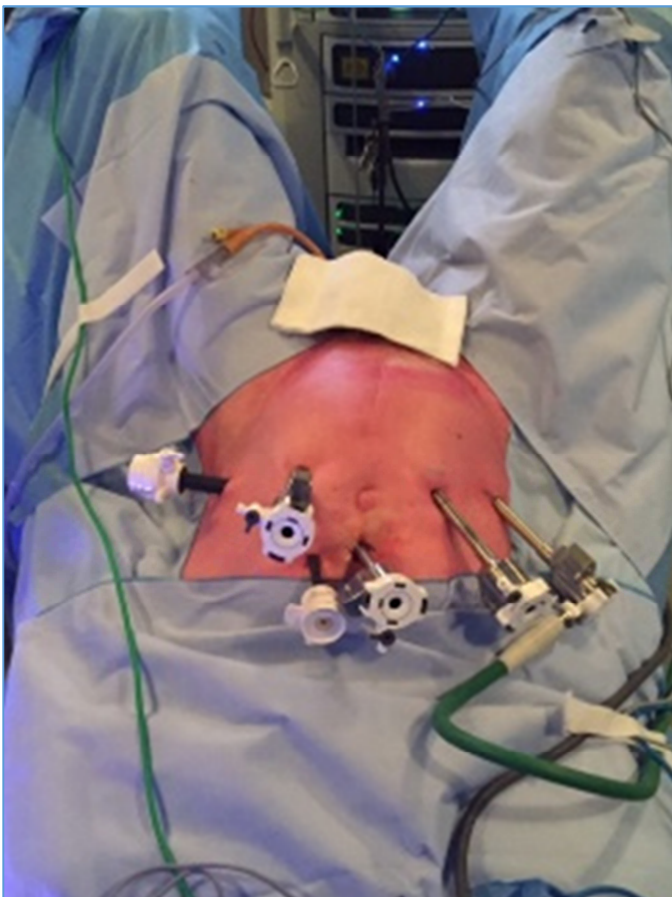


Figure 5.6.12. Final trocar positions

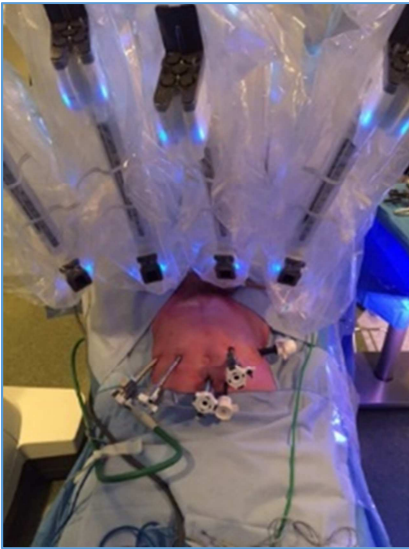

Figure 5.6.13. Robot arms in positioning for connection

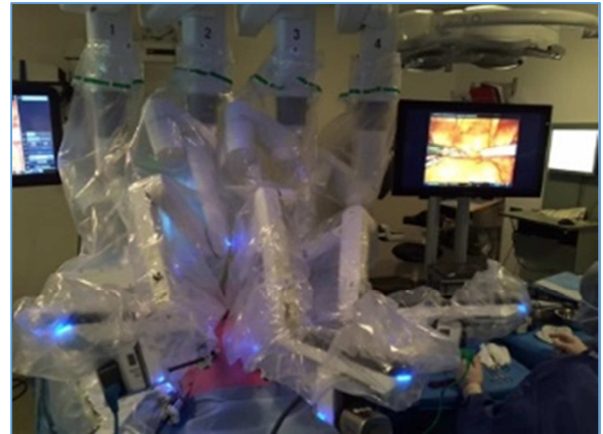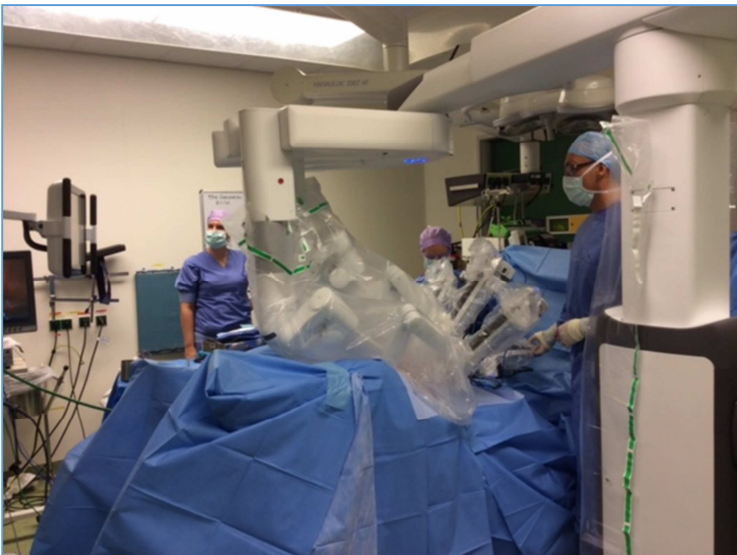


Figure 5.6.14. Robot arms connected

Figure 5.6.15. Connection of the robot

The patient is placed in steep Trendelenburg position (30°) and the robot is connected to the trocars (Figures 5.6.13 until 5.6.15).

Step 3. Incision of the peritoneum and entry into the Retzius space: The following instruments are used:

- Monopolar curved scissors (hot shears)
- Maryland or fenestrated bipolar forceps
- Prograsp
- Assistant fenestrated grasper, suction device, laparoscopic scissors, clips
- Camera: 0°

The camera is introduced first (Figure 5.6.16), then the surgical instruments are introduced under camera vision (Figure 5.6.17).

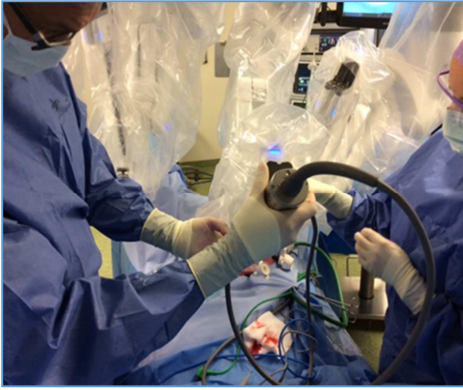


Figure 5.6.16. Introduction of the camera

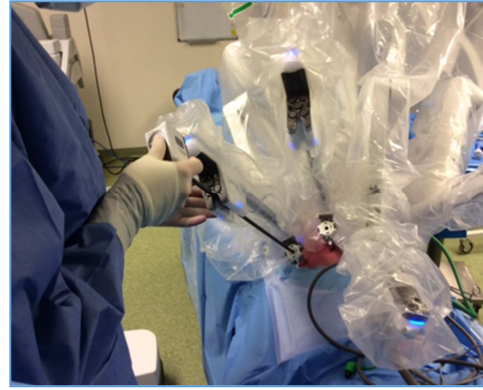


Figure 5.6.17. Introduction of surgical instruments under vision

The monitor must always be watched while the instruments are being inserted, even during automatically guided instrument changes. The surgeon takes his/her place behind the surgical console and the operating assistant stays beside the patient.

A peritoneal incision is made laterally to the medial umbilical ligament and is extended on both sides in inverted U fashion to the level of the vasa deferentia on either side (Figures 5.6.18 and 5.6.19). The Retzius space is developed until the level of the endopelvic fascia (Figures 5.6.20 and 5.6.21). Doing this causes the urinary bladder to drop down towards the Douglas space. The surgeon must stay medial to the vasa deferentia to prevent injury to the iliac vessels. The peritoneum must be dissected to the following anatomical planes: the pubic bone, the medial umbilical ligaments, and the vasa deferentia.

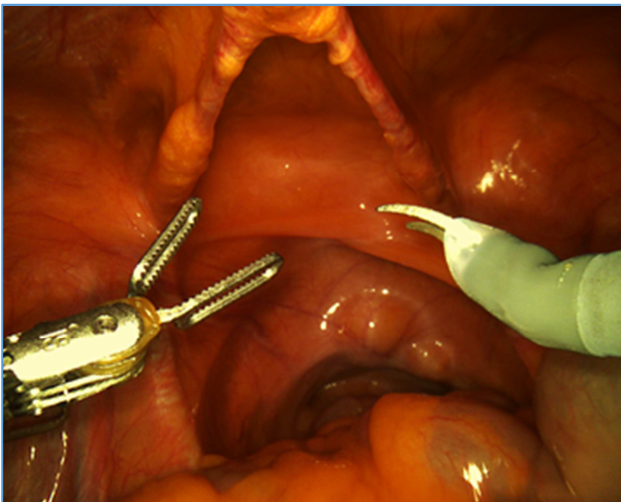


Figure 5.6.18. Medial umbilical ligaments

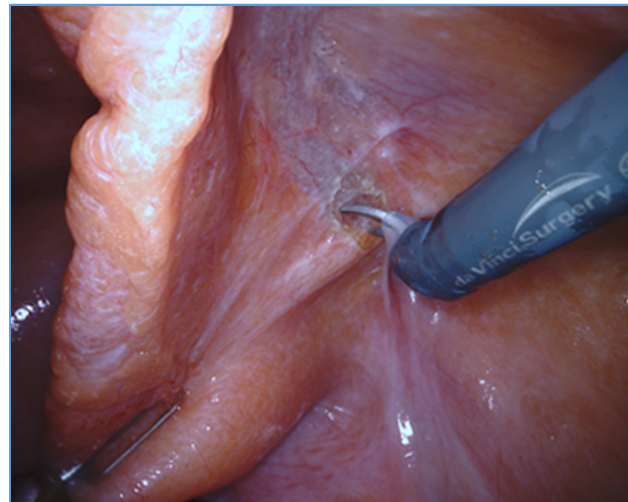


Figure 5.6.19. Peritoneal incision lateral to the right medial umbilical ligament

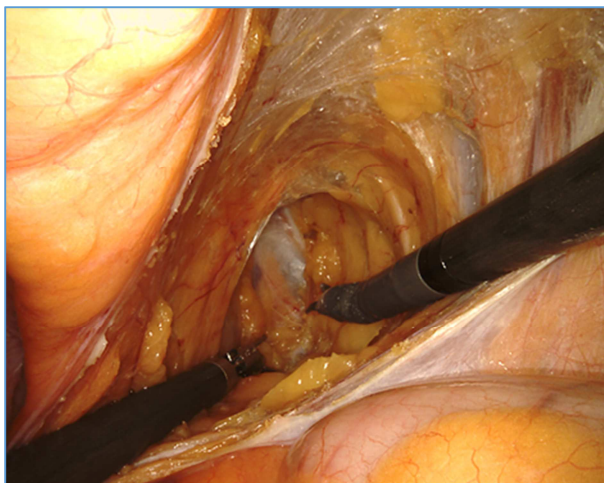


Figure 5.6.20. Opening the Retzius space to the endopelvic fascia

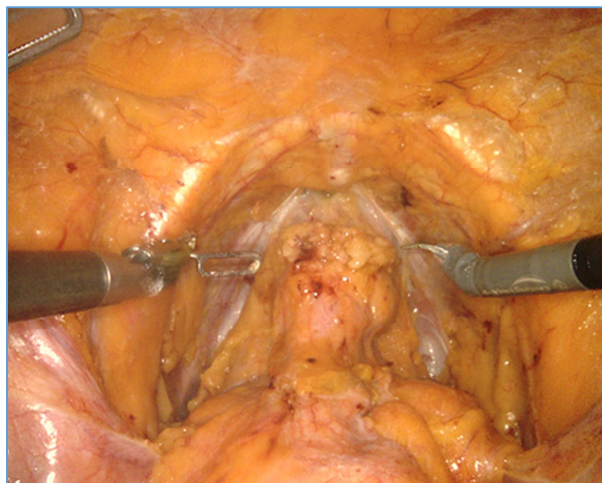


Figure 5.6.21. The bladder fully dropped

Step 4. Incision of the endopelvic fascia (EPF) and identification of the dorsal venous complex (DVC): The important landmarks are the bladder neck, base of the prostate, pelvic floor muscles, and apex of the prostate. The periprostatic fat is removed (or swept towards the bladder neck) (Figure 5.6.22). The fatty layer covering the endopelvic fascia (EPF) is swept laterally. The EPF is best opened at the base of the prostate with cold scissors and slight traction of the prostate to the opposite side (Figure 5.6.23).

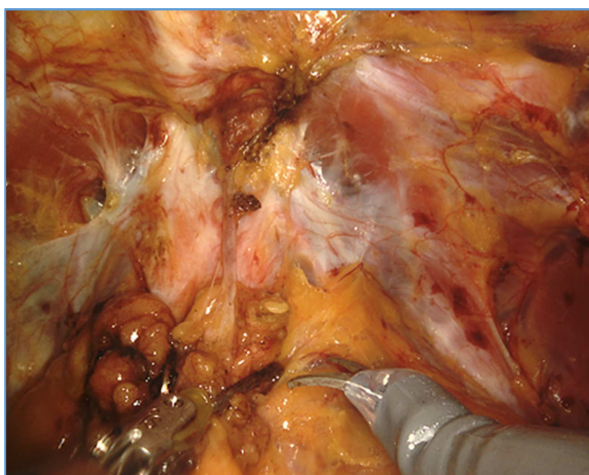


Figure 5.6.22. Removing the periprostatic tissue

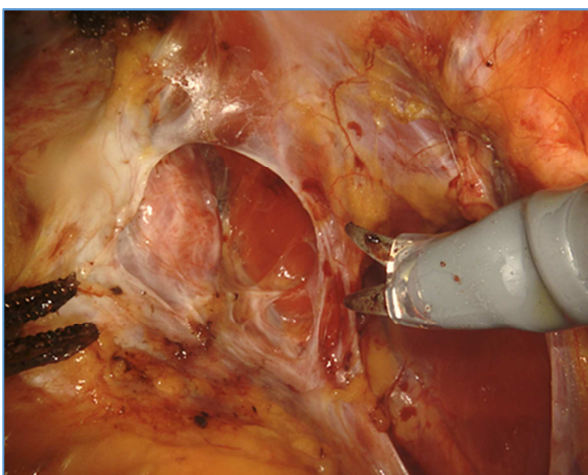


Figure 5.6.23. Endopelvic fascia opened at the base of prostate

Proceeding from the base to the apex, the pelvic floor muscle fibers are erased off the prostate so that the DVC and urethra become visible (the “notch”) (Figures 5.6.24 and 5.6.25).

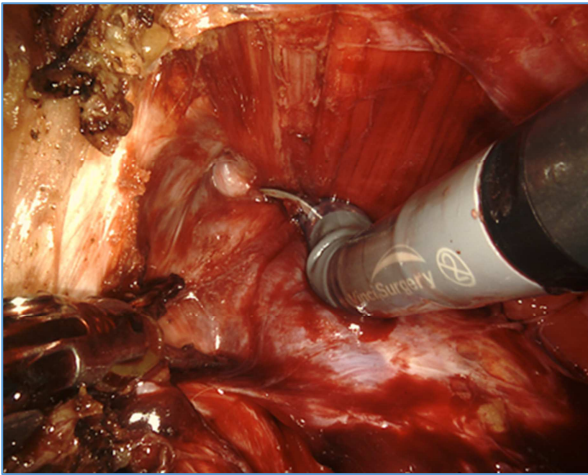


Figure 5.6.24. "Notch"

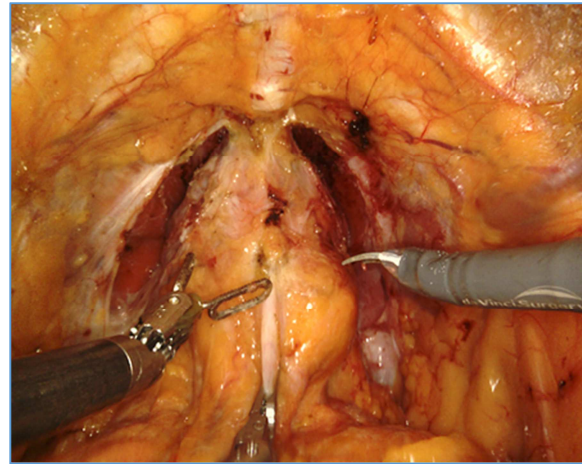


Figure 5.6.25. Endopelvic fascia opened left and right

In nerve-sparing surgery, it is necessary to keep a fascia on the musculus levator ani and the prostate (inter-fascial dissection).

Step 5. Ligation of the dorsal venous complex (DVC): The instruments are changed:

- Monopolar curved scissors (hot shears) and Maryland or fenestrated bipolar forceps are replaced with robotic needle drivers

The needle is placed in the notch between the urethra and the DVC, then pushed straight across at 90°. The suture needs to be strong enough to allow the needle holders to pull up tight and make a slip knot. A second suture is placed to suspend the urethra to the pubic bone and secondarily ligate the DVC. The DVC is thus encircled and is then stabilized to the pubic bone together with the urethra.

Step 6. Anterior bladder-neck dissection: The instruments are changed:

- The needle drivers are replaced with monopolar curved scissors (hot shears) and Maryland or fenestrated bipolar forceps
- The camera can optionally be changed to a 30° downward lens for bladder-neck dissection

The bladder neck is identifiable as a reversed V-form shape (Figure 5.6.26).

Another technique is to pull on the urethral catheter (from outside the patient) and visualize the balloon. However, this technique can be unreliable and misleading after transurethral resection of the prostate (TURP) or in patients with a median lobe or large prostate.

The bladder, or bladder neck, is dissected from the prostate in the midline in a sweeping motion of the monopolar curved scissors while the bladder neck fibers are visualized. The key is to stay in the midline to avoid opening of lateral venous sinuses. The dissection continues on either side of the bladder neck. Once the anterior urethra is opened and incised laterally, the Foley catheter is retracted upward to expose the posterior bladder neck.

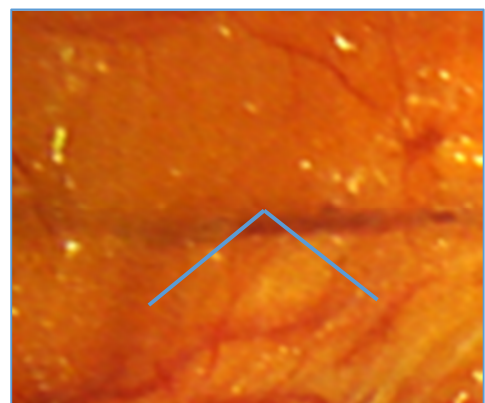


Figure 5.6.26. Reversed V-form shaped bladder neck

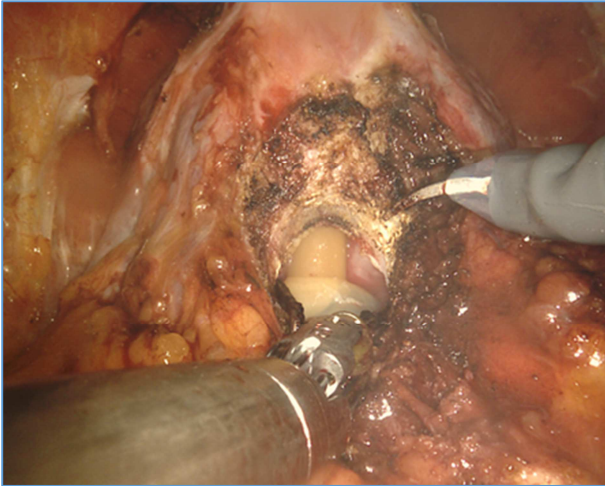


Figure 5.6.27. Opening of the anterior bladder wall

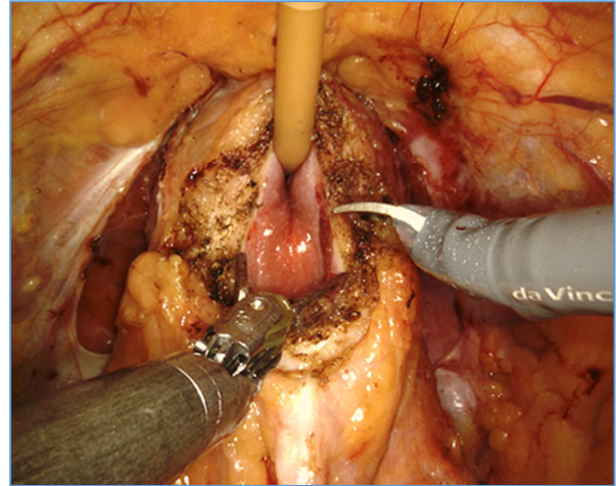


Figure 5.6.28. Opening of the posterior bladder wall

Step 7. Dissection of the posterior bladder neck: After the incision has been made in the anterior bladder neck, the posterior bladder neck is incised (Figures 5.6.27 and 5.6.28). Both ureter ostia should be identified, since they may be located close to the posterior bladder neck, especially after TURP. The posterior bladder neck is pulled gently in a dorsal cranial direction. The Denonvilliers' fascia (vesico-prostatic muscle) is visualized and becomes recognizable because of the vertical fiber alignment.

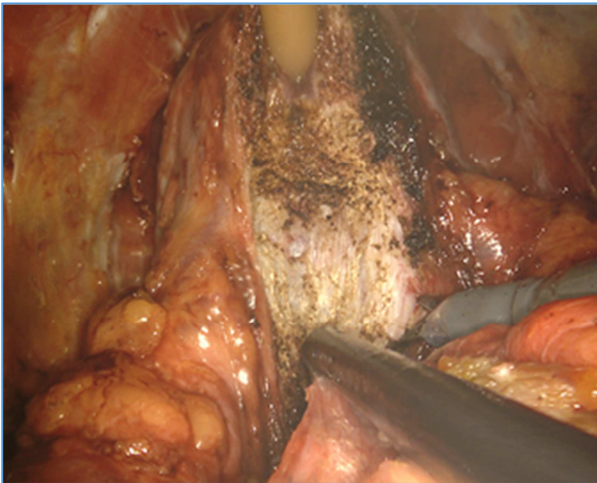

Figure 5.6.29. Denonvilliers' fascia

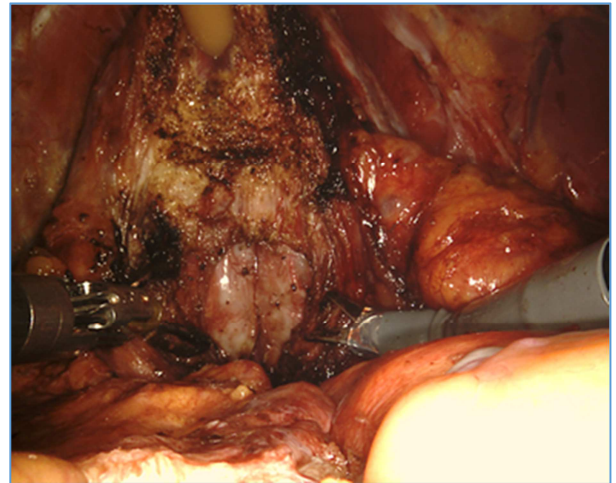

Figure 5.6.30. Exposure of the vasa deferentia

Denonvilliers' fascia is incised posteriorly and slightly cranially (towards the bladder) to expose the vasa deferentia and seminal vesicles (Figures 5.6.29 and 5.6.30).

Dissection towards the prostate must be avoided because the base of the prostate might be entered (between the peripheral and transitional zone of the prostate).

Step 8. Seminal vesicle dissection: The vasa deferentia are identified, clipped, dissected, and retracted cranially (Figure 5.6.31). The assistant applies countertraction with a suction device dorsally from the bladder neck. The vasa deferentia are then followed to the tip of the seminal vesicle. Then, the fascia around the vasa deferentia is incised. The seminal vesicles are bluntly dissected. The seminal vesicles have their own arterial blood supply from within the prostatic pedicle. The tips of the seminal vesicles can be spared with nerve-sparing surgery.

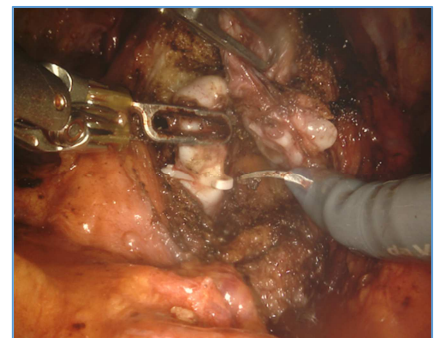

Figure 5.6.31. Clipping the vas deferens

Step 9. Denonvilliers' fascia incision and posterior dissection: Denonvilliers' fascia is incised at the base of the seminal vesicles. The correct plane can be identified by the white avascular tissue between the prostate and the rectum. When preparing dorsally from the Denonvilliers' fascia (such as in non-nerve sparing surgery), one enters the area with the yellow perirectal fat ventrally from the rectum (Figures 5.6.32 until 5.6.34).

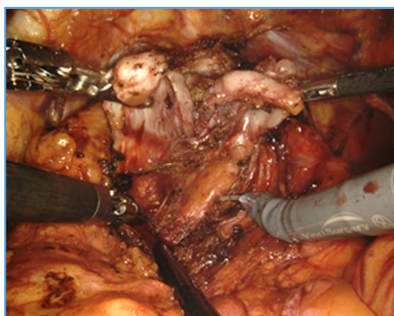


Figure 5.6.32. Elevation and traction of the seminal vesicles

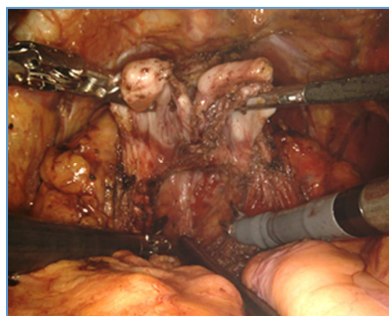

Figure 5.6.33. Opening the Denonvilliers' fascia posteriorly

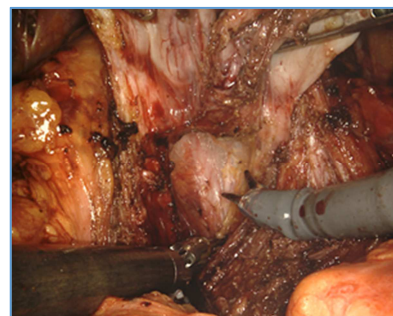


Figure 5.6.34. Rectum

The posterior plane between the prostate and the rectum is opened further to the apex of the prostate. This facilitates rotation during nerve sparing.

Step 10a. Nerve-sparing surgery and dissection of the prostatic pedicle: Once the fascia of the prostate has been opened laterally or more towards the apex, spreading the tissue will allow identification of the plane between the prostate and the neurovascular bundle (NVB). No thermal energy is used during the dissection of the NVBs or ligation of the pedicles. The NVB is released in a retrograde fashion towards the prostatic pedicle if possible. Otherwise, the dissection is carried out in an antegrade mode. The prostate pedicle is narrowed and the NVB is delineated (Figure 5.6.35). Elevating the prostate by holding up the seminal vesicle and applying contralateral traction to the prostate pedicle makes this possible. The prostatic pedicle is clipped and the NVB is completely released from the prostate.

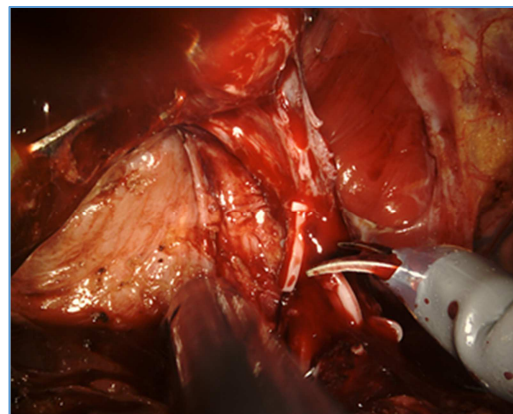


Figure 5.6.35. Release of the neurovascular bundle

Step 10b. Wide excision in non-nerve-sparing surgery: The dissection is carried out in an antegrade fashion. The prostate pedicles are identified and narrowed when the prostate is elevated by holding up the seminal vesicle and applying contralateral traction to the prostate pedicle. Clips are placed laterally while the NVB remains on the prostate. This can be done closer to the apex with cold scissors. Clips must not be placed in the apical region because of possible clip migration through the vesico-urethral anastomosis.

Step 11. Apical dissection: The anatomic landmarks are the ligated DVC, the urethra (if visible), the apex of the prostate, and the NVB when a nerve-sparing procedure is used. Bleeding of the DVC interferes with proper apical dissection and dissection of the urethra (Figures 5.6.36 and 5.6.37). If much bleeding occurs, a stitch (such as a V-lock suture) can be used to control the DVC before proceeding. During dissection of the DVC and the apex, suction must be minimized to prevent any decrease of the intraperitoneal pressure. Apical dissection with cold scissors is recommended to spare the urethra.

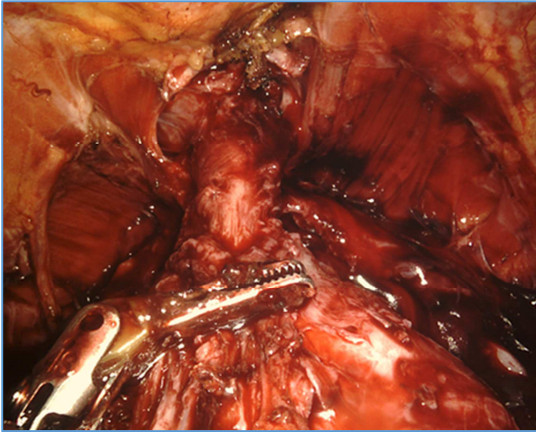


Figure 5.6.36. Urethra

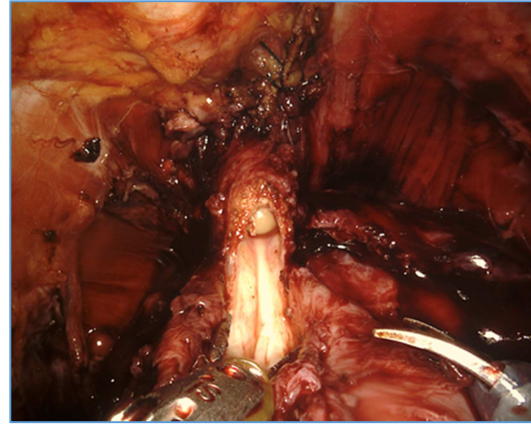


Figure 5.6.37. Posterior wall of the urethra

This facilitates the vesico-urethral anastomosis and contributes to the early recovery of urinary continence.

When the urethra is divided, the recto-urethral fascia and the Denonvillier's fascia are the only remaining structures holding the prostate in place. These fasciae are to be divided sharply and liberated from the underlying rectum to prevent rectal injury. The prostate is detached and placed in an endobag.

For safety reasons, digital rectal examination or the air bubble proof (rectal insufflation of air while irrigating the operation field with saline) following prostate dissection is advised as a standard procedure.

Step 12. Urethrovesical anastomosis: The scissors and forceps are replaced with large needle drivers.

The urethra and bladder neck are approximated with a continuous double-armed stitch.(130) A barbed suture or any other resolvable monofilament suture can be used for the anastomosis. The first two stitches are passed through the Denonvilliers' fascia and the posterior bladder neck (Figures 5.6.38 and 5.6.39).

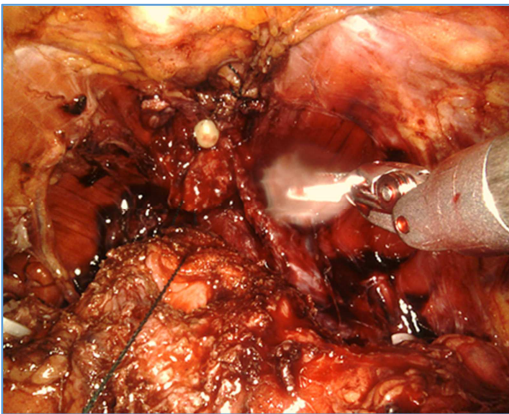


Figure 5.6.38. Reconstruction of Denonvilliers' fascia

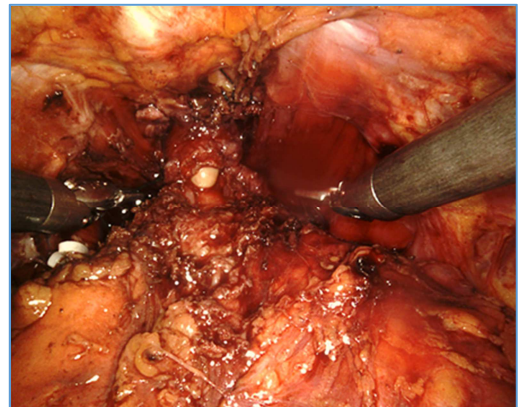


Figure 5.6.39. Anastomosis

When there is a difference in circumference of the urethra and the bladder neck, an anterior "tennis racket" reconstruction is required.

If it is not possible to bring the bladder to the urethra, a posterior "tennis racket" reconstruction can be used so that the posterior bladder wall can be mobilized more easily to the urethral stump. This also creates a tight bladder neck (Figure 5.6.40). The bladder should be filled with 100–150 mL of saline to test the water tightness of the anastomosis. A drain can be placed near the anastomosis site. The trocars are removed under direct vision.

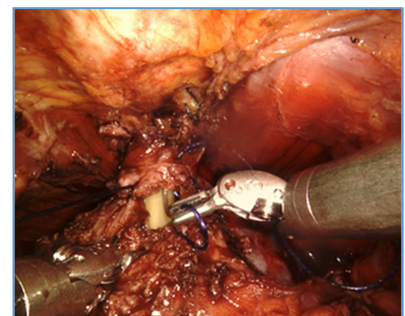


Figure 5.6.40. Closure anastomosis

In case of extended lymph node dissection, the dissection includes removal of the nodes overlying the external iliac artery and vein, the nodes within the obturator fossa located cranially and caudally to the obturator nerve, and the nodes medial and lateral to the internal artery.

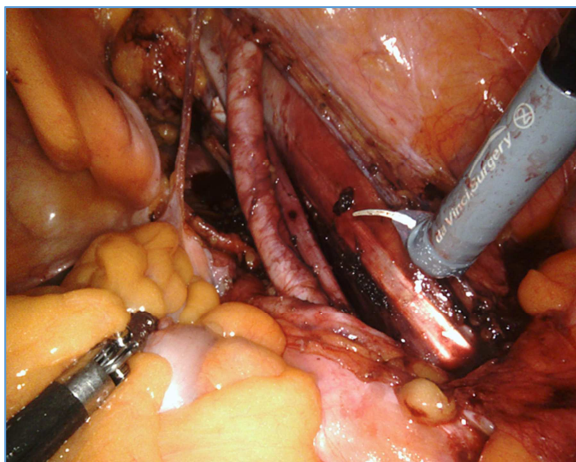


Figure 5.6.41. Template of extended pelvic lymph node dissection at the right side.

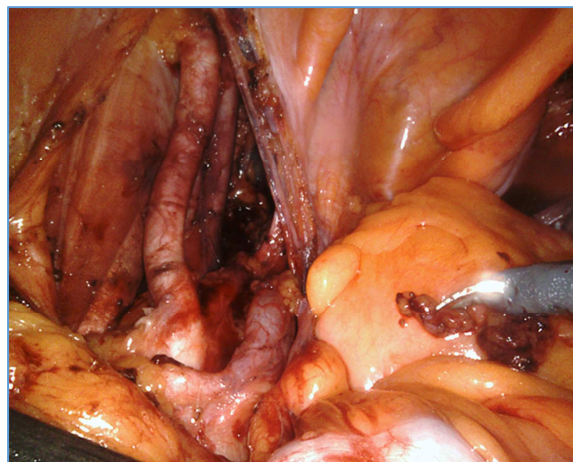


Figure 5.6.42. Template of extended pelvic lymph node dissection at the left side.

Postoperative care

The specific aspects following RARP that should be addressed are:

- Cerebral edema causing sleepiness, confusion, or agitation(131)
- Subcutaneous emphysema of the neck and trachea edema may hinder extubation
- Bladder contractions due to the indwelling catheter causing abdominal pain.(132) Oxybutynin, 5 mg sublingually, reduces this inconvenience
- Hematuria and blood clotting in the catheter. The catheter must remain patent to prevent acute urinary retention and a disruption of the vesico-urethral anastomosis.

The patients usually have an indwelling transurethral catheter for 5 days to 3 weeks. The urologist decides when the catheter can safely be removed. A cystogram can be done to check for anastomotic leakage before the catheter is removed. The need for a drain tube must be discussed. If drain output is high, creatinine determination of the drain fluid can differentiate between urine and lymph/peritoneal fluid.

General and specific complications

We can evaluate the quality of the RARP from the oncological and functional outcomes and the complications. The internationally accepted Clavien-Dindo system (Table 5.6.5) can be used to classify complications.(133) This system focuses on the necessity of therapeutic interventions in the treatment of postoperative complications. A complication is defined as any deviation from the normally expected postoperative course. Grades I and II are considered minor complications, and grades III to V are major complications. Problems solved during surgery, as well as conversion to open surgery, are not considered complications.

Table 5.6.5. The international Clavien-Dindo classification system for surgical complications

Grade	Definition
I	Any deviation from the expected postoperative course without a need for intervention such as pharmacological, radiological, or surgical treatment. Non-registered interventions include: anti-emetics, anti-algetics, antiphlogistics, diuretics, electrolyte infusion, physiotherapy, and superficial wound infections treated at bedside.

II	Requirement of pharmacological treatment other than that mentioned above, including antibiotics, blood transfusion, and parenteral nutrition.
III	Intervention without inducing general anesthesia in the patient (such as lymphocele drainage and nephrostomy)
IIIb	Intervention after general anesthesia has been induced in the patient (such as closure of wound dehiscence or double J stenting)
IV	Life-threatening complications requiring intensive care management (e.g. myocardial infarction)
IVa	Single-organ dysfunction
IVb	Multi-organ failure
V	Death
Suffix d	If a patient still suffers from a disabling (d) complication at discharge, the suffix 'd' should be added to the respective complication grade.

General complications

The overall complication rate after RARP is 5 to 10%, and less than 5% of the complications are major. Surgical experience and patient characteristics are related to the complication rate.(134)

Compartment syndrome may occur during extensive procedures (lasting more than 5 h), especially in obese patients and patients with atherosclerosis.

Trocar lesion

Introduction of the camera trocar bears the risk of a bowel injury or vessel perforation. Previous abdominal surgery often results in adhesions in which the bowel may be attached to scar tissue.

Vascular injury

In the case of vascular injury during the procedure, the first principle is to provide a tamponade. Maintenance of the pneumoperitoneum or even increase of the intra-abdominal pressure (IAP) reduces venous bleeding. In the case of arterial bleeding, elevating the IAP does not help and clamping is necessary. Once the bleeding site has been identified, a proper view of the injured area is needed. Failure to control the bleeding, as well as hemodynamic instability, is an indication for immediate conversion to open surgery.

The most common vessel injury concerns the epigastric vessels, which can be injured during trocar placement and during dissection of the bladder from the abdominal wall. To avoid this injury, trocars should be placed at least 6 cm from the midline. In slim men, transillumination of the abdominal wall can be useful for identifying and bypassing epigastric vessels (Figure 5.6.43).

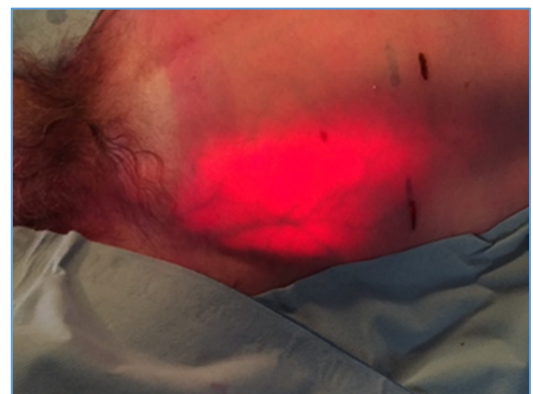

Figure 5.6.43. Illumination of the abdominal wall

At the end of the procedure, trocars should be removed under vision and inspected for bleeding.

The dorsal venous complex (DVC) is a feared bleeding site. Persistent bleeding after DVC ligation can be controlled by increasing the IAP to 20 mmHg and eventually packing with gauzes. After apical dissection, a transurethral retracted Foley catheter with inflated balloon may provide a tamponade as well.

Injury of the iliacal vessels must be sutured if narrowing of the lumen is prevented.

Use of sealants, precautious suturing, selective clipping, and bipolar cautery can control diffuse oozing from the prostate pedicles in order to prevent damage of the nearby neurovascular tissue.

Postoperative blood loss following robotic surgery that necessitates transfusions is estimated to occur at a rate of 0 to 3.3%.(30, 135)

Recommendation

If bleeding cannot be controlled and it compromises visibility, or if there is hemodynamic instability, the robotic procedure should be converted to open surgery.

Pelvic nerve injury

The most common nerve injury involves the obturator nerve. An incidence of 0.4% has been reported in RARP.(136) Injuries are caused by stretching of the nerve, but more commonly by thermal energy or complete transection during lymph-node dissection. Recovery of the obturator function from neuropraxia occurs spontaneously within 6 weeks. However, after a full transection, gait disturbance may persist due to atrophy of the adductor muscles.

Small-bowel injury

Small-bowel injuries have been reported in 0.13 to 0.9%.(136) Damage is often related to trocar placement, adhesions from previous surgery, intraperitoneal inflammation, or thermal injury from electrocautery. Most of the bowel lesions (estimated at 75% of the total lesions) are not recognized during surgery. The intestine should be meticulously inspected to identify as yet unrecognized bowel injuries before the operation is terminated.

A general surgeon should be consulted, during surgery, for treatment advice.

The clinical symptoms are pain at port sites, abdominal distension, diarrhea, and mild fever. If bowel injury is suspected, then either computed tomography with oral contrast should be obtained or direct laparotomy should be performed.(137) A plain abdominal radiograph is not specific enough to detect bowel injury because it reveals free air, which is normally present following pneumoperitoneum.

Postoperative paralytic ileus is reported in 0.7 to 2.4% following RARP.(136) Ileus is probably caused by urinary leakage, intraperitoneal hematoma, or fascia dehiscence. Conservative management with a nasogastric tube, drainage of the urinoma, and an indwelling catheter are usually sufficient. In rare cases, urinary diversion via nephrostomies is necessary.

If postoperative obstructive ileus occurs, a trocar port hernia should be suspected. A CT scan may help in the diagnosis. Trocar ports of 8 mm or less are at low risk of developing bowel herniation. The fasciae of ports more than 10 mm should be closed.

Recommendation

Before the RARP is terminated, the intestine and trocar ports should be meticulously inspected for bowel injury or unrecognized bleeding.

The clinical symptoms of bowel perforation following RARP are port pain, abdominal distension, diarrhea, and mild fever. A CT scan with oral contrast is recommended.

Rectal injury

The incidence of rectal injury during RARP varies from 0 to 2%. The risk of a rectal injury is greater in patients with a history of prostatitis, rectum surgery, or pelvic irradiation. These conditions obscure the anatomical plane between the rectum and the prostate. Furthermore, in wide salvage prostatectomies, the dissection of the prostate pedicles may lead to “tenting” and laceration of the rectum. Avoiding electrocautery at the dorsal plane dissection of the prostate reduces the risk of rectal injury. When rectal injury is suspected, the location of the perforation should be determined by digital rectal examination or by rectal insufflation of air while the operation field is being irrigated with saline. Primary closure of the rectum in two layers is normally sufficient (in the absence of gross fecal contamination). As in small bowel injury, intra-operative consultation with a general surgeon is encouraged. After the injury has been repaired, the bubble test must be repeated. The operation field should be thoroughly irrigated and drained. Then the vesico-urethral anastomosis can be done. The posterior stitches should not incorporate the rectal wall, which would increase the risk of a rectal-urethral fistula. After rectal injury, antibiotic therapy with anaerobe coverage for 7 days is recommended, as well as prolonged catheter placement and clinical observation. A cystogram is mandatory before catheter removal.

Recommendation

For safety reasons, digital rectal examination or the air bubble proof following prostate dissection is advised as a standard procedure

Thrombo-embolic events

The combination of pelvic cancer surgery, pneumoperitoneum, and the lithotomy position increases the risk of thrombo-embolic events during or after RARP. Therefore, prophylactic subcutaneous injections of low-molecular-weight heparin (LMWH) are recommended for every patient undergoing RARP. There is some debate about the duration of these prophylactic injections. The clinical effect of this regimen on postoperative blood loss is probably minimal. Early ambulation should be promoted to limit the chance of thrombo-embolic events, and the injections of LMWH are advised for a maximum of 4 weeks. Sound scientific evidence to support this recommendation is lacking.

There is lack of clear scientific evidence that compression stockings (during or after surgery) or sequential compression devices (during surgery) prevent thrombo-embolic events.

Recommendation

Prophylactic subcutaneous injections of LMWH are recommended after RARP for a maximum of 4 weeks

Neuromuscular injuries

Cutaneous neuralgias of the abdominal wall are likely related to direct surgical trauma at the trocar ports. Cutaneous neuralgias (neuropaxia) occur in as many as 3.6% of the cases.

Compartment syndrome occurs when excessive pressure builds up inside an enclosed space of the body, and in RARP, mainly the calf muscles. The dangerously high pressure in the legs impedes the blood flow. The risks of compartment syndrome and concomitant rhabdomyolysis are related to the lithotomy position with the legs in the leg holders and to increases in operation time and body weight. The steep Trendelenburg position increases the risk as well.

Compartment syndrome is suspected if a patient has pain in one or both calf muscles, while at physical examination the calf muscles are firm, swollen, and painful. Duplex ultrasonography is recommended, and it differentiates between compartment syndrome and deep venous thrombosis.

Recommendation

For procedures with prolonged elevation, it has been suggested that the legs should be lowered temporarily after 4 h

Anastomotic leakage

Urinary leakage at the urethro-vesical anastomosis is one of the most common short-term complications of RARP, with an incidence of 0.3% to 15.4%. The risk factors for urethro-vesical anastomotic leakage include obesity, a large prostate (> 100 mL), previous prostatic surgery or radiotherapy, difficulties in performing anastomosis, and urinary tract infection.

Whether reconstruction of the musculofascial plate, the Rocco stitch or double-layer anastomosis, decreases the risk of leakage is uncertain.

Urinary leakage causes paralytic ileus due to uremic peritonitis. It is diagnosed from imaging. Recommended imaging techniques are a cystogram or a computerized tomography cystogram with intravenous contrast.

Treatment of the leakage consists of leaving the indwelling catheter in place. For severe urinary leakage, nephrostomies are necessary for urinary diversion. A cystogram is recommended before considering catheter removal. Anastomotic leakage may cause long-term stricture and incontinence.(138, 139)

Recommendation

Peroperative flush of the vesico-urethral anastomosis to ensure its watertightness is recommended

Ureteral lesions

In wide bladder-neck dissection, the ureteral orifices can be injured. The incidence of ureteral injuries is less than 1%, and more than 70% of ureteral injuries are diagnosed postoperatively. If wide bladder-neck dissection is planned, double J stents can be placed to identify the orifices.

As an alternative, endoscopic delineation of the dissection plane can be marked. In previous TURP, the location of ureteral orifices may be aberrant. When opening the posterior bladder wall, both ureteral orifices should be identified. Intravenous indigo carmine can be helpful for identifying the orifices.

Ureters can be transected by coincidence, during extended pelvic lymph node dissection. The injured ureter should be stented in a retrograde fashion via the bladder opening. Partially or fully transected ureters can be repaired after stent placement with a 5-0 monocryl suture. If distal ureter transection occurs, the distal ureter can be directly implanted into the bladder.

If the orifices lie at the edge of the posterior bladder neck, a posterior tennis racket configuration will place the orifices deeper into the bladder. Eversion of the orifices may occur if they are on the edge of the bladder neck when the posterior anastomosis is created. Again, double J stents will prevent closure of the ureters.

Recommendation

When the orifices are near the bladder neck, insert double J stents

Hernia at the trocar site

The incidence of trocar-site hernia ranges from 0.04% to 0.5%. Hernias generally occur at the larger trocar ports. Therefore, fascial closure of all ports greater than 10 mm is recommended. Although rare, hernias have been described through 5-mm and 8-mm robotic trocar ports. Signs of trocar hernia are abdominal pain, ileus, nausea, and vomiting. Diagnosis is made from a CT scan with oral contrast.

Lymphoceles

Lymphoceles have an estimated incidence of up to 50% and are mostly asymptomatic. Symptomatic lymphoceles may cause pain, abdominal distension, thrombosis formation, and/or unilateral leg edema. Ultrasound or a CT scan confirms the diagnosis, and ultrasound-guided (or CT-guided) percutaneous drainage is

the recommended treatment. More than 90% of drained lymphoceles subside spontaneously. If lymphoceles persist despite drainage, laparoscopic fenestration of the peritoneum may be required.

5.7 Robot-assisted sacrocolpopexy

Steven Schraffordt Koops

Introduction

Prolapse after hysterectomy is common, with an incidence of 0.2% to 43%.⁽¹⁴⁰⁾ Sacrocolpopexy is the most successful treatment for prolapse after hysterectomy, with success rates ranging from 80% to 99%.^(141, 142) Gynecologist Lane initially described the procedure in 1962 [4].⁽¹⁴³⁾ At that time, sacrocolpopexy consisted of a nylon mesh attached with silk to the posterior side of the vagina top. It was suspended with silk at the anterior longitudinal ligament, just to the right of the midline, on the sacrum (Figure 5.7.1). Now polypropylene monofilament mesh is used for the suspension. A Y shaped implant or two separate meshes support both the anterior and posterior sides of the vaginal wall.

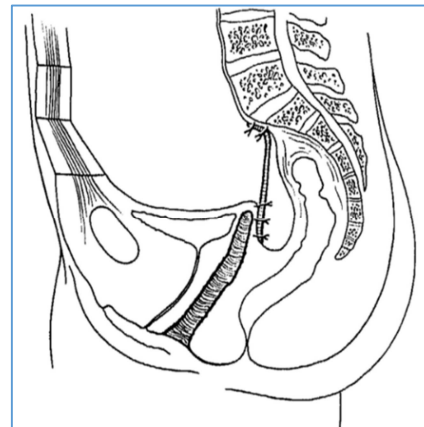


Figure 5.7.1. Sacrocolpopexy

Once the high risk of complications following the use of transvaginal mesh became evident, abdominal prolapse surgery became more prevalent. Open abdominal sacrocolpopexy has now been replaced with a laparoscopic or robot-assisted approach.⁽¹⁴⁴⁻¹⁴⁷⁾ Despite the benefits of minimally invasive surgery, laparoscopic sacrocolpopexy was not implemented on a large scale due to the long learning curve. The operation robot has facilitated sacrocolpopexy and boosted the use of this procedure.⁽¹⁴⁸⁻¹⁵⁰⁾

General facts

The learning curve. The surgeon reaches a plateau phase in operating time and surgical outcome in conventional laparoscopic sacrocolpopexy after about 60 procedures and in robot-assisted sacrocolpopexy after 10 to 20 procedures.⁽¹⁵¹⁻¹⁵⁵⁾

The surgical team. A qualified and trained team is advisable for these complex interventions to reach optimal care. Proctoring in laparoscopic sacrocolpopexy is recommended, and it is compulsory in robot-assisted sacrocolpopexy.⁽²⁾

National regulations. Mesh use is under strict regulation because of the high complication rates following vaginal mesh implantation. The Dutch Society of Obstetrics and Gynaecology (NVOG) has published specific guidelines.⁽¹⁵⁵⁾ The Dutch government has imposed criteria for the use of mesh.

Requirements for hospitals that implant mesh in prolapse surgery:

- Hospitals that offer mesh surgery must meet the criteria laid down in the NVOG subspecialty publication and the note about the gynecologist with the subspecialty urogynecology
- The Dutch Healthcare Inspectorate's quality inspection for the specific use of mesh is obligatory
- Registration of implants with the production number and registration of complications is obligatory, and the data must be traceable to the patient
- The patients, production numbers, and complications must be registered in a nationwide database

Indications

Indications and procedures have changed through the years. Initially, Lane only repaired a middle-compartment prolapse that occurred after a hysterectomy.⁽¹⁴³⁾ Now the indications are prolapse of the anterior compartment (cystocele), posterior compartment (rectocele or enterocele) or middle compartment (cervical or vaginal top). Sacrocolpopexy or hysteropexy can also be performed in the case of prior prolapse surgery, genetic gynecological prolapse, or other risk factors.

Contra-indications

Absolute sacrocolpopexy-specific contra-indications:

- Elevated intracranial pressure
- Uncorrected elevated intra-ocular pressure
- In the case of supravaginal hysterectomy: malignancy of the endometrium or uterus

Relative sacrocolpopexy-specific contra-indications:

- Retina detachment
- Severe pelvic adhesions
- Pelvic surgery or irradiation
- Pelvic trauma
- Peritoneal dialysis

Informed consent

The patient should be informed about the general aspects of the procedure (see section 3.4), and specifically about the possible consequences:

- Sexual dysfunction
- Urge and stress urinary incontinence
- Recurrence rates
- Mesh erosion and exposition shrinking and pain
- Risk of malignancy in case of morcelation with a supravaginal hysterectomy, even if hysterectomy is only performed for benign indications.

Patient history and examination

Previous pelvic surgery, allergies, medication use, and smoking are associated with a higher rate of mesh erosion.(156) Anticoagulant medication may be continued since the risk of bleeding is low, depending on the specific hospital protocol.

Pre-operative assessment

Prolapse may cause kinking of the urethra, resulting in urethral obstruction, and thereby masking pre-existent stress urinary incontinence. Therefore, prolapse surgery may unmask stress urinary incontinence. Pre-operative evaluation of micturition can determine the underlying presence of stress urinary incontinence.

After testing, patients can be informed about the possibility of worsening or de novo stress urinary incontinence. If there is severe stress urinary incontinence, a mid-urethral sling can be considered during prolapse surgery.(157-159) However, this bears the risk of obstructive micturition. The incidence of stress urinary incontinence is greater after open sacrocolpopexy than after laparoscopic sacrocolpopexy.(160) Preoperative ultrasound of the uterus, a PAP smear for cervical cytology, and endometrial biopsy are advised if a concomitant hysterectomy is performed.

Bowel preparation and diet. Bowel preparation and rectal enemas are not standard. There is a strict “no oral intake” policy for the 6 hours immediately preceding surgery. When the sacrocolpopexy is combined with a concomitant anterior rectopexy, bowel preparation is advisable.

Antibiotic prophylaxis. Since sacrocolpopexy is a “clean” procedure, with the use of mesh, a single dose of antibiotic prophylaxis with a second- or third-generation cephalosporin is advisable, for instance, cefazolin 1 g intravenously and metronidazole 500 mg, just before surgery.

Team check

In case of unexpected conversion, instruments and a retractor must be quickly available.

Patient positioning

Once the patient is under general anesthesia, positioning on the operation table must be checked and secured. Both the anesthesiologist and the surgeon are responsible for proper positioning. Because patients are placed in a steep Trendelenburg position (20–35 degrees) and the robotic arms are fixed, measures have to be taken to prevent sliding during surgery. Foam blocks for the head, bean bags, anti-sliding mattresses, or a yoke pillow can be used to prevent sliding.

Tight belts over the patient's thorax need to be avoided during the time while thorax compression may reduce ventilation. The pressure points of the arms and legs should be padded. The shoulders should be free of tension to prevent brachial plexus lesion. Special attention must be given to the positioning and padding of the hands and fingers as the leg holders are nearby. The hands should be in an anatomically neutral position. Improper fixation could cause the hand to drop laterally and hyperextend, which could lead to radial nerve injury. Anesthesiologic lines (e.g. intravenous support, arterial lines, and saturation devices) are secured and passed upwards to the anesthesiologic devices. The legs are placed and padded in the leg holders. The hips and knees are flexed slightly (Figure 5.7.2). Avoid hyperextension at the hips, which risks stretch injury of the femoral nerve. Compartment syndrome may occur during procedures that last more than 5 hours, especially in obese patients and patients with atherosclerosis. The face, eyes, and nose can be injured by the robotic scope. Face protection such as a mask, a bar, and foam pads will reduce the risk of injury.

The steepness of the Trendelenburg position needs to be established precisely; the bowel must be kept out of the smaller pelvis without compromising ventilation. The Trendelenburg position should be tested before the robot is connected.

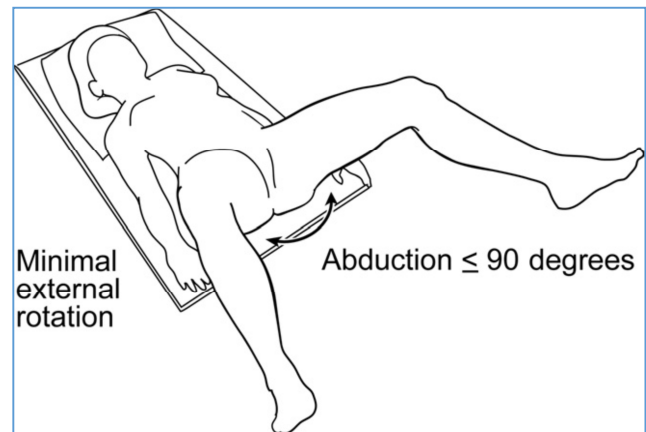


Figure 5.7.2. Patient positioning

Instruments needed for robotic sacrocolpopexy:

- Catheter
- Stomach drain
- Veress needle
- 30° endoscope
- Three robotic trocars
- One assistant blunt-tip trocar, preferably with a balloon
- Vaginal probe or speculum
- Conventional laparoscopic graspers for manipulating the intestine before docking
- Tenaculum grasping forceps and robotic bipolar fenestrated forceps in case of uterus in situ (Figure 5.7.3)
- Cadiere forceps, grasping retractor or ProGrasp forceps
- Curved scissors
- Suture-cut needle driver
- Two pieces of polypropylene mesh, of which one piece at least 3 cm wide and 20 cm long, and one piece 3 cm wide and 10 cm long. Otherwise, a pre-fabricated Y mesh can be used
- Smoke suction device (optional)
- Protack tacking device (optional)



Figure 5.7.3. Instruments

Operative technique for robot-assisted sacrocolpopexy, hysteropexy, and supravaginal hysterectomy with cervicopexy

1. Create pneumoperitoneum, after draping and placing the urinary catheter. Advice: drape in such a way that the rectum and vagina are accessible
2. Perform side docking from the left -side (the operation assistant is on the right side)
3. Trocar placement:
 - Sub-umbilical placement of the camera trocar
 - Two 8-mm robot trocars are introduced (approximately 8 cm apart, “a hand width”) left laterally to the camera trocar
 - An 8 mm assisting trocar is placed on the right-hand side 8 cm to the right of the first trocar
 - The third robot trocar is placed on the right side, again approximately 8 cm from the assisting trocar. (Figure 5.7.4)

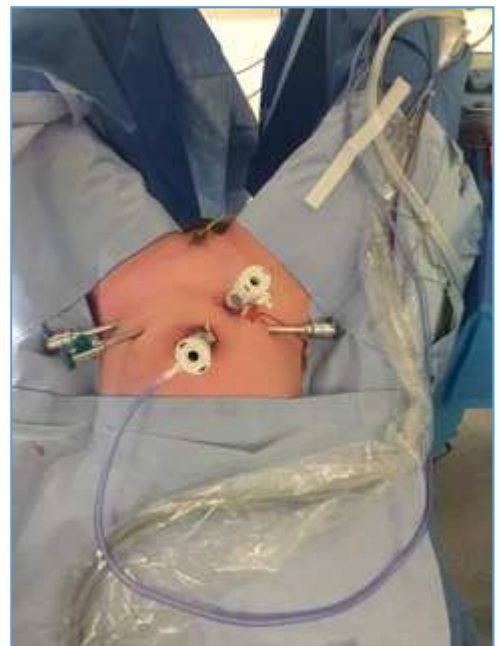


Figure 5.7.4. Trocars positioning

4. Instruments:

- Right arm (robotic arm 1): monopolar curved scissors (hot shears)
- Left arm (robotic arm 2): Maryland or fenestrated bipolar forceps
- Left arm (robotic arm 3): Cadierre or ProGrasp forceps or a tenaculum for concomitant supravaginal hysterectomy
- Assistant trocar: fenestrated grasper and suction device
- Camera: 30° binocular lens

Advice: place the instruments in direct endoscopic view. Always use left-side docking, otherwise the assistant port will not be above the promontory.

5. In the case of concomitant supravaginal hysterectomy and tubectomy left and right, bipolar coagulation (robotic arm 2) and monopolar curved scissors (robotic arm 1) are used. The uterus is manipulated with a tenaculum (robotic arm 3). The cervix is cut monopolar (robotic arm 1). The uterus is left intra-abdominal, to be morcelated or retracted at the end of surgery. A 12-mm or 15-mm trocar is then needed. Advice: take care not to lose the uterus intra-abdominally; place a long suture through the uterus for anchoring.
6. Dissection of the promontory: use robotic arm 3 to mobilize the intestine from the dissection area to the left side. Dissect with robotic arms 2 and 3. Dissect until a proper area where suturing or tacking in the anterior longitudinal ligament is possible. It is crucial to identify the bifurcation of the aorta, caval vein, right iliac vein and artery, right ureter, superior rectal artery, and the small nerves running over the promontory.

Advice: this is one of the most crucial stages of this procedure. Take care of the venous plexus in the sacrum, which may bleed heavily. If there is bleeding in this area, do not convert directly to laparotomy. First increase the intra-abdominal pressure to 25 mmHg. Then compress the bleeding area with a gauze for at least 3 minutes. Place hemostatic sutures.

7. Dissect from the promontory to the base of the posterior vagina, open the peritoneum with monopolar scissors (robotic arm 1). The opening must be sufficient to pass the 3-cm wide mesh. Be careful of the right ureter.
8. Dissect the posterior vaginal wall down to the pelvic floor. Use a vaginal probe and, if necessary, a rectal probe. Be aware of the rectum. If there is an intestinal lesion, close it in a double layer, and do not place the mesh because of the risk of mesh infection.
9. Open the peritoneum of the vesicovaginal septum over the vaginal probe. This can be difficult due to adhesions from a previous hysterectomy. In this case, filling the bladder with saline 150 ml may help. The dissection needs to be distal until the bladder neck in order to repair a cystocele or to prevent a cystocele from recurring. Avoid coagulation if possible to prevent a vesico-vaginal fistula forming. A lesion of the bladder dome can be sutured in one layer. Cystoscopy may be needed to identify the lesion. Then complete the rest of the procedure. Leave the indwelling catheter for at least 3 days.
10. Fix the posterior mesh (20 cm x 3 cm) to the posterior vaginal wall, being careful to avoid perforation. Non-absorbent sutures are usually used here. Change the curved scissors in robotic arm 1 to suture with the needle driver.

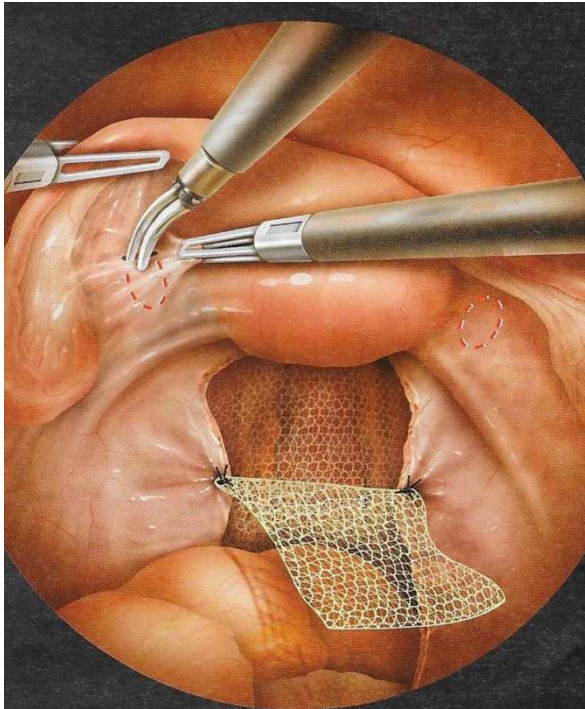


Figure 5.7.5. Fenestration of the broad ligaments

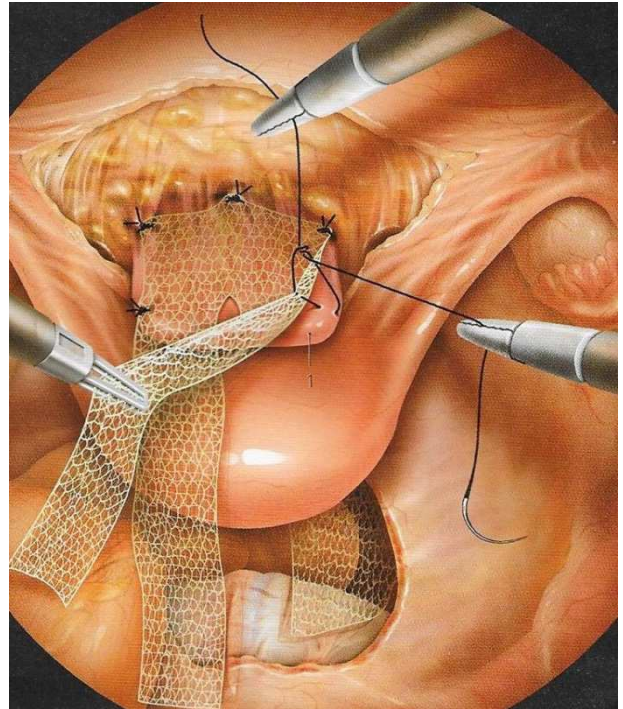


Figure 5.7.6. Mesh fixation of the anterior vaginal wall

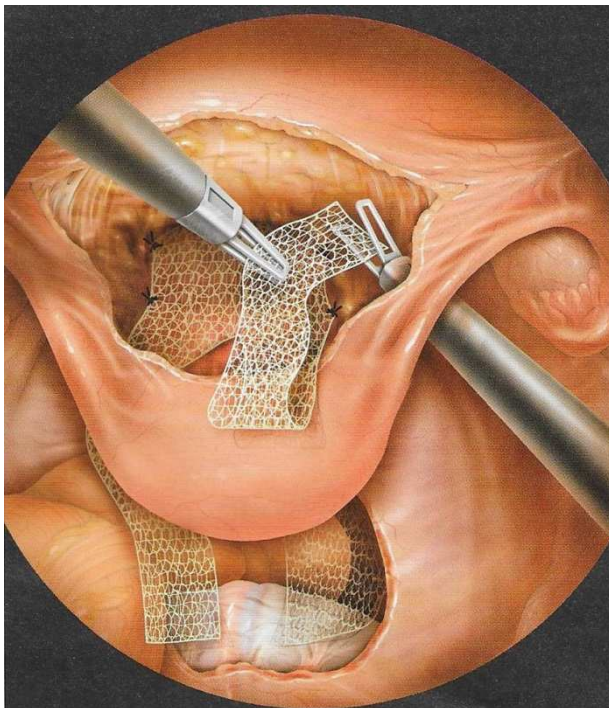


Figure 5.7.7. The two tails of the anterior mesh are pulled through the window in the broad ligaments

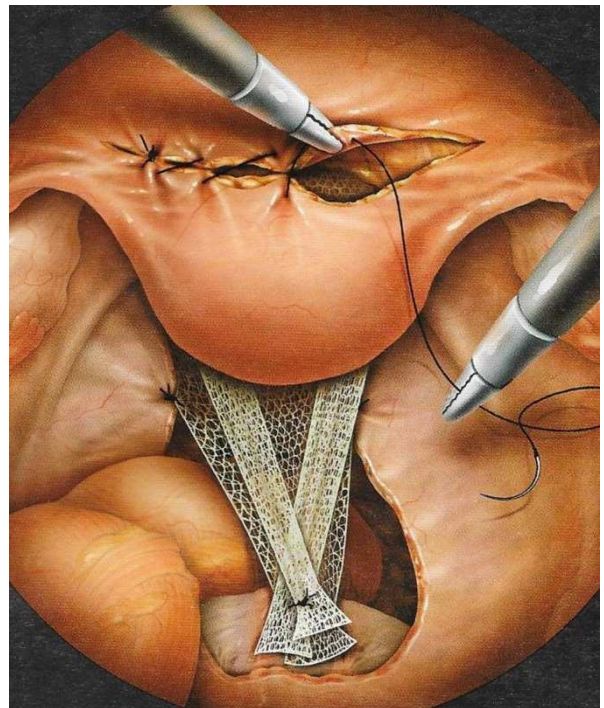


Figure 5.7.8. Fixation of the anterior and posterior mesh to the promontory and closure of the peritoneum

11. Fix the mesh (3 cm x 10 cm) to the anterior vaginal wall with four to six sutures. Then connect both mesh parts proximally just above the top of the vagina with two or three sutures (Figure 5.7.9). Cut off the excess material as is suitable. In a hysteropexy, the anterior mesh should be cut in the median line to create two separate parts that need to pass through the broad ligament of the uterus before being fixed to the posteriorly placed mesh (Figures 5.7.5 until 5.7.8(161)).

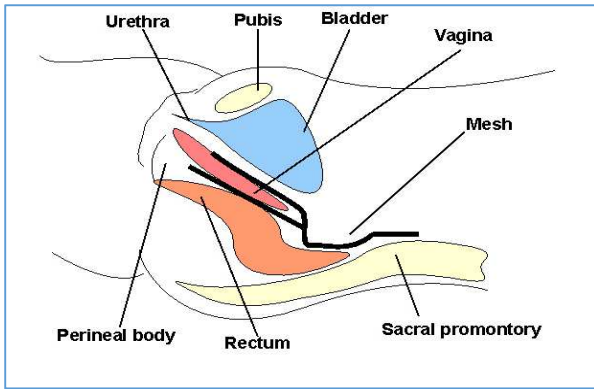


Figure 5.7.9. Fixation of the mesh

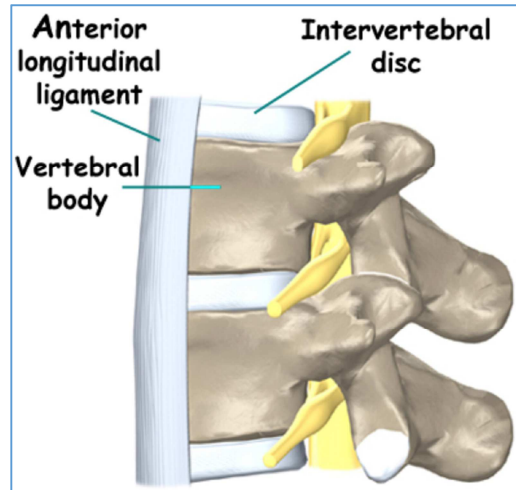


Figure 5.7.10. Anatomy of the longitudinal ligament

12. Fix the proximal mesh to the longitudinal ligament of the promontory with tacks or sutures (Figures 5.7.10 and 5.7.11). Do not place any traction on the mesh because of possible shrinking.

13. Cover the mesh with peritoneum to prevent adhesions and entrapment of the bowel. Prevent entrapment and/or kinking of the right ureter. The peritoneum can be closed with a running, absorbable, barbed suture.

14. In a supravaginal hysterectomy, morcelate or remove the uterus with endocatch.

15. A wound drain is not strictly necessary.

16. Check the hemostasis, remove the instruments and trocars under vision, and close the fascia incisions that are larger than 10 mm to prevent incisional herniation.

17. Note any specific surgical complications in the patient's file.

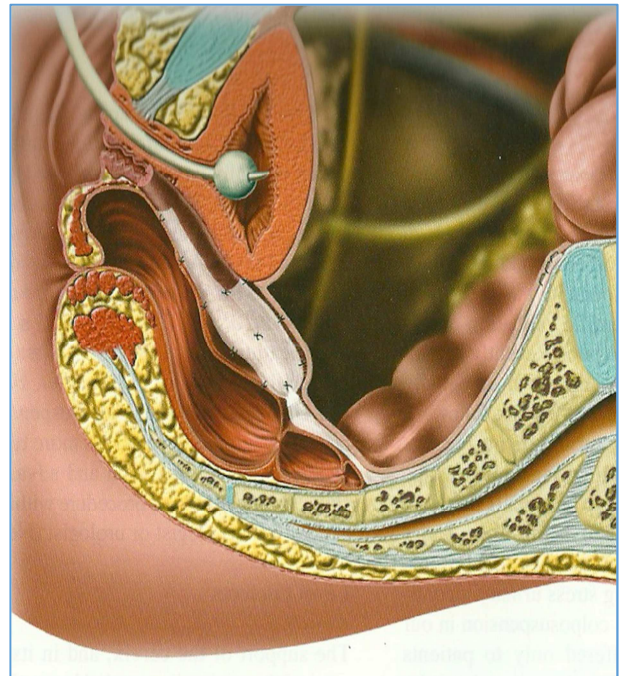


Figure 5.7.11. Position of the mesh

Post-operative care

Laxatives should be given postoperatively as a standard. Postoperative pain scores are usually low. A hospital stay of 1 to 3 nights can be expected. Leave the urinary catheter in for one night. Advise the patient not to lift more than 1 to 3 kg for 6 weeks.

Complications

Specific sacrocolpopexy complications:

- Lesions of the common iliac artery, aorta, vena cava, superior rectal vein, ureter, bladder, vagina, and/or rectum
- Morcelation increases the risk of such lesions
- Mesh erosion or exposition

Postoperative erosion or exposition of mesh is a complication unique to the use of synthetic mesh and its tendency to erode through adjacent tissue. Erosions are generally defined as visible portions of surgical material, usually mesh or suture, which has become exposed through the epithelium of the vagina or into adjacent visceral organs. The incidence of mesh erosion following sacrocolpopexy is 3.4%.⁽¹⁶²⁾

The consequences of erosions range from negligible to severe. Modifiable risk factors associated with mesh erosions include smoking, concomitant hysterectomy, and mesh type. Patients must be advised to quit smoking.

The use of biomaterials is discouraged because of the high prolapse recurrence rates.⁽¹⁶³⁾ Polypropylene should be used instead.

Because of the increased risks of erosion and exposition, sacrocolpopexy should not be combined with hysterectomy.^(156, 164-166) The alternative is hysteropexy or supravaginal hysterectomy, which have low erosion and exposition rates (0–0.5%).^(164, 166) Erosion and exposition are registered according to the ICS/IUGA joint definition and classification (Figure 5.7.12).⁽¹⁶⁷⁾


CATEGORY				
General Description	A (Asymptomatic)	B (Symptomatic)	C (Infection)	D (Abscess)
1 Vaginal: no epithelial separation Include prominence (e.g. due to wrinkling or folding), mesh fibre palpation or contraction (shrinkage)	1A: Abnormal prosthesis or graft finding on clinical examination	1B: Symptomatic e.g. unusual discomfort / pain; dyspareunia (either partner); bleeding	1C: Infection (suspected or actual)	1D = Abscess
2 Vaginal: smaller ≤ 1cm exposure	2A: Asymptomatic	2B: Symptomatic	2C: Infection	2D = Abscess
3 Vaginal: larger >1cm exposure, or any extrusion	3A: Asymptomatic 1-3Aa if no prosthesis or graft related pain	3B: Symptomatic 1-3B (b-e) if prosthesis or graft related pain	3C: Infection 1-3C /1-3D (b-e) if prosthesis or graft related pain	3D = Abscess
4 Urinary Tract: compromise or perforation Including prosthesis (graft) perforation, fistula and calculus	4A: Small intraoperative defect e.g. bladder perforation	4B: Other lower urinary tract complication or urinary retention	4C: Ureteric or upper urinary tract complication	
5 Rectal or Bowel: compromise or perforation including prosthesis (graft) perforation and fistula	5A: Small intraoperative defect (rectal or bowel)	5B: Rectal injury or compromise	5C: Small or Large bowel injury or compromise	5D = Abscess
6 Skin and / or musculoskeletal: complications including discharge pain lump or sinus tract formation	6A: Asymptomatic, abnormal finding on clinical examination	6B: Symptomatic e.g. discharge, pain or lump	6C: Infection e.g. sinus tract formation	6D = Abscess
7 Patient: compromise including hematoma or systemic compromise	7A: Bleeding complication including haematoma	7B: Major degree of resuscitation or intensive care*	7C: Mortality * (additional complication - no site applicable - S 0)	
TIME (clinically diagnosed)				
T1: Intraoperative to 48 hours	T2: 48 hours to 2 months	T3: 2 months to 12 months	T4: over 12 months	
SITE				
S1: Vaginal: area of suture line	S2: Vaginal: away from from area of suture line	S3: Trocar passage Exception: Intra-abdominal (S5)	S4: other skin or musculoskeletal site	S5: Intra-abdominal
N.B. 1. Multiple complications may occur in the same patient. There may be early and late complications in the same patient. i.e. All complications to be listed. Tables of complications may often be procedure specific. 2. The highest final category for any single complication should be used if there is a change over time. (patient 888) 3. Urinary tract infections and functional issues (apart from 4B) have not been included.				
CODE <input type="checkbox"/> <input type="checkbox"/> <input type="checkbox"/> <input checked="" type="checkbox"/> T <input type="checkbox"/> <input type="checkbox"/> <input type="checkbox"/> S <input type="checkbox"/>				

Figure 5.7.12. ICS/IUGA complication classification

5.8. Children

Rafal Chrzan, Fred van der Toorn, Piet Calleweart

Introduction

Laparoscopy for children requires specific expertise and awareness of the physiological difference between children and adults.(168-172) Laparoscopy is safe regardless of the patient's age, although there is hardly any evidence that laparoscopy is superior to open surgery in terms of results, complications, or costs.(173-175) Knowledge of the pathophysiology of congenital anomalies is very important.

Whether every surgeon specializing in pediatric urology should perform laparoscopy is a subject of debate. Success depends on skills, experience, and training.(175-177) Currently, no validated training programs are available. There are no guidelines on urological laparoscopic procedures for children either.

This chapter only describes specific aspects of laparoscopy and robot-assisted surgery in children. General recommendations are described in the other chapters.

Anatomy and physiology

The intra-abdominal working space in children is limited and decreases geometrically in relation to decreasing body size.(168) A shorter distance between organs is related to an increased risk of injury of the surrounding tissues during surgery. The affected structures (e.g. the ureter or testis) are small and extremely fragile. This requires gentle tissue handling and the use of fine instruments.

Because of their higher peritoneal permeability and lower elimination ability, children are more likely than adults to develop hypercapnia due to pneumoperitoneum. The Trendelenburg position limits ventilation, which decreases CO₂ elimination and may worsen hypercapnia.(178, 179) Its severity is related to the duration of the procedure and the intra-abdominal pressure.(180-183) Keeping the intra-abdominal pressure as low as possible and increasing the ventilation rate help minimize the side effects of hypercapnia. High metabolism and fast decrease of body temperature in children must be monitored and regulated (e.g. by insufflation of warm CO₂ and draping). Therefore, an anesthesiologist with specific pediatric expertise must be involved.

Equipment and preparation

Instruments used for children are available in various sizes (range: 2 mm – 10 mm) and lengths (range: 20 cm – 43 cm).(168, 183-186) The 3-mm scope can be used in minor pediatric procedures (e.g. gonadal biopsy or an undescended testis). Urological procedures usually necessitate a 5-mm or 10-mm telescope.

The basic equipment (dissecting and grasping forceps, scissors, and needle holders) are available in the 2-mm size, but are rarely used in pediatric urology. Coagulating and sealing devices are available from the 3-mm size up; 3-mm or 5-mm instruments are used for reconstructive procedures. One should be aware that thinner instruments are less rigid so that 3-mm instruments are not recommended for ablation. The instruments should be as short as possible, but long enough to enable safe surgery.

Pneumoperitoneum and trocar insertion

As in adults, open introduction of the first trocar is advisable.(177, 186, 187) The intra-abdominal pressure in children should be as low as possible for an adequate working space with maxima of:

- Infants (< 12 months old): 8-10 mmHg
- Small children (2 to 10 years old): 10-12 mmHg
- Children (> 10 years old): 12-15 mmHg

The insufflation rate should not exceed 3 L/min. Blunt or sharp trocars can be used, depending on the surgeon's preference.

Indications and contra-indications

Almost every possible pediatric operation of an intra-abdominal urologic nature has already been performed laparoscopically.(180, 188-200) Robot-assisted laparoscopy is now being widely introduced for children. There are no specific contra-indications regarding laparoscopy for children versus adults. However, congenital cardiopulmonary anomalies require extra attention.

Training and certification

There are no guidelines for training in pediatric laparoscopy. The European Society of Pediatric Endoscopic Surgeons established a primary strategy on this topic in 2015.(201) However, this document has no official status yet. The authors suggest a training program with the following steps:

- Theory
- Simulation program
- Internship in training centers for pediatric laparoscopy
- Personal experience with the stepwise extension of the operating procedures

Training for laparoscopic pyeloplasty

Laparoscopic pyeloplasty is the pediatric reconstructive procedure that is most frequently performed. Laparoscopic suturing to obtain a watertight anastomosis is challenging. Improper anastomosis leads to complications requiring re-intervention at a rate of 20% or conversion to open surgery at a rate of 18%.(202-204) A training model for laparoscopic suturing might reduce the complication and conversion rates.(205)

Certification

The Dutch Urological Association is now working on certification criteria for complex operative procedures for children. Pediatric laparoscopic surgery should also be included.

Pediatric robot-assisted surgery

It is unclear whether the pediatric surgical outcome of robot-assisted surgery is better than that of laparoscopic or open surgery.(206, 207) Both the transperitoneal approach and the retroperitoneal approach are possible.

The robot surgical system uses 5-mm and 8-mm instruments. Due to different articular mechanisms (Figure 5.8.1a,b), the 5-mm instruments need more intracorporal working space than the 8-mm instruments, which paradoxically leads some surgeons to prefer 8-mm instruments for small children. There are no robotic 5-mm bipolar cautery instruments at this time.




Figure 5.8.1a,b. The different articular mechanisms of (a) 8-mm instruments and (b) 5-mm instruments

Transperitoneal or retroperitoneal robot-assisted pyeloplasty according to Anderson-Hynes

Retrograde pyelography before pyeloplasty is advisable.(208, 209) The purpose of the retrograde pyelography is to optimize trocar placement and identify any congenital ureteral anomalies. In the transperitoneal approach, the colon has to be mobilized for visualization of the ureteropelvic junction (UPJ). Alternatively, at the left side, the UPJ can be approached through the mesocolon, which limits the peritoneal incisions. A ureteral stent at the end of the procedure is advisable. Ureterocalicostomy can be performed for children whose ureters are too short (due to fibrosis or unavoidable resection) and severely dilated lower-pole calices.

Vesicoureteric reflux and ureterovesical obstruction

Both intravesical pneumovesicoscopic and extravesical ureteral reimplantations are possible.(169) Pneumovesicoscopy involves insertion of a 5-mm trocar into the dome of a saline-distended urinary bladder under cystoscopic guidance. The saline is then drained and the bladder is insufflated with CO₂ to create the working space. Two lateral trocars are then inserted under visual guidance for surgery.

The functional results of laparoscopic ureteral implantation are comparable to the results of open surgery, with success rates greater than 95%. However, there are fewer irritative bladder complaints following intravesical laparoscopy than following open surgery. Compared to open surgery, less urinary retention occurs following robot-assisted extravesical ureteral reimplantation.

Heminephrectomy in duplex systems with ureterocele, ectopic ureters, and/or reflux

Heminephrectomy is most commonly performed for afunctional hydronephrotic moieties associated with ureterocele or ectopic ureters (upper pole) or severe reflux (lower pole).(169, 208) The advantage of the robot-assisted procedure over open surgery is the limited kidney mobilization and easy identification of the vasculature.

5.8.1. Nonpalpable testis (NPT)

Rafal Chrzan

Introduction

The undescended testis is the most common anomaly of the urogenital tract in children. A congenital undescended testis may or may not be palpable. Diagnostic laparoscopy is indicated for unilateral or bilateral NPT to determine the position of the testis or confirm its absence.

Applicable guidelines

- Dutch Guideline for Nonpalpable Testis(210)
- EAU Guidelines on Pediatric Urology(34)

Indications

Laparoscopy is the gold standard for NPT. It should preferably be done when the patient is 6 to 12 months old. Laparoscopy is not only a diagnostic procedure; it may also be therapeutic as well. A testicular remnant or hypoplastic testis should be removed or, in the case of a vital testis, a laparoscopic orchidopexy (one-stage or two-stage Fowler-Stephens procedure) can be performed.

Contra-indications

There are no specific pediatric contra-indications.

Preoperative instrumentation

- Basic laparoscopic pediatric set
- 30° Optic, 3 mm or 5 mm
- 3-mm or 5-mm instruments: 2 dissectors, 1 diathermy electrode, 1 pair of scissors
- A 6-mm trocar for a 5-mm telescope or a 3.5-mm trocar for a 3-mm telescope as well as two 3.5-mm working trocars or two 6-mm working trocars (Figure 5.8.1.1).

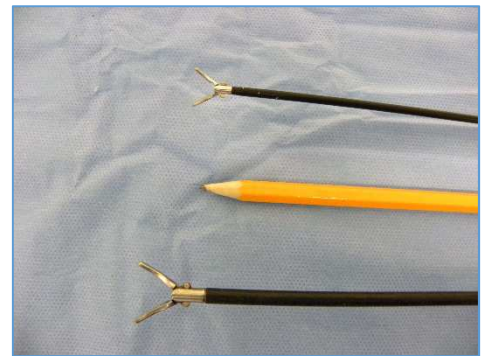

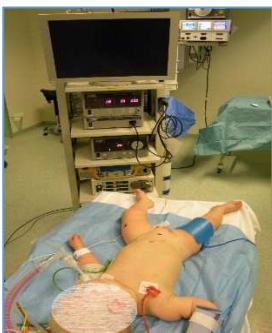Figure 5.8.1. 1. 3-mm instruments (top) and 5mm instruments (bottom)

Preparation for surgery and positioning

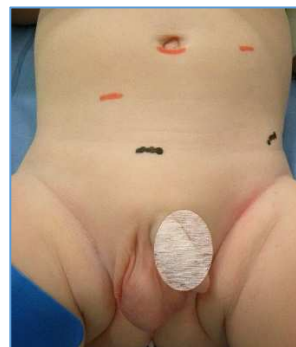First check the groin and scrotum with the patient under general anesthesia (look for the testis, nubbin, spermatic cord, and contralateral testis). With the patient in the supine position, check the bladder and, if necessary, empty it in a single catheterization.

Disinfect the surgical field; that is, the lower abdomen including the umbilicus and scrotum.

The monitor should be placed at the footboard, and the surgeon stands at the head. The assisting surgeon and the scrub nurse stand opposite the surgeon (Figure 5.8.1.2a,b).



a



b

Figure 5.8.1.2a,b. Nonpalpable testis on the left side: (a) laparoscopic setting; (b) location of the trocars (red lines)

Team check

The time-out procedure is carried out according the local hospital rules.

Laparoscopic technique

The first trocar (3.5 mm or 6 mm) is put into the umbilicus (the open Hasson introduction is preferable). CO₂ is insufflated at a rate of 1–2 L/min at a pressure of 6–8 mmHg). A Trendelenburg position may be helpful to keep the bowel out of the surgical field. Both internal inguinal rings are visually inspected for the presence of the testis, testicular vessels, and ductus deferens. In the absence of the testis or testicular vessels on the affected side, the procedure is terminated (Figure 5.8.1.3a,b).

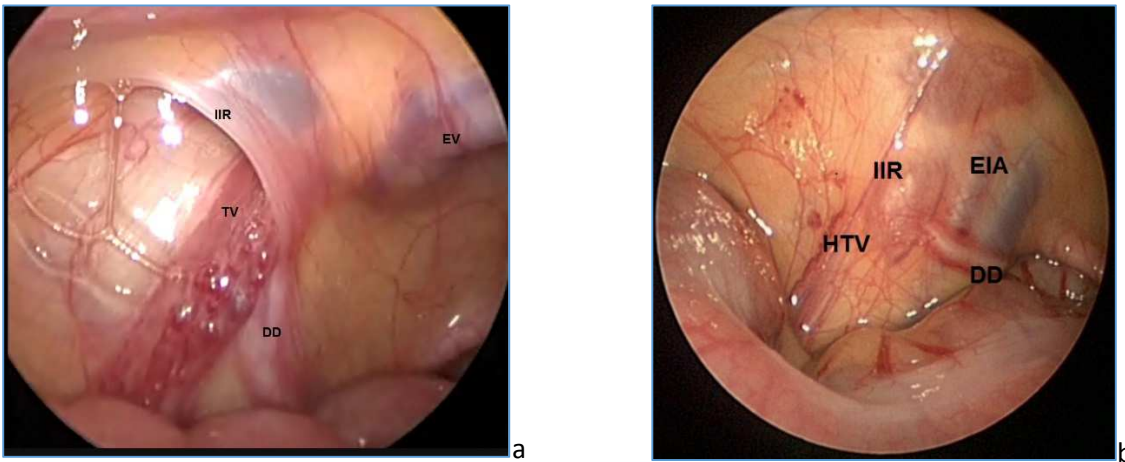


Figure 5.8.3.3a,b. Laparoscopic view of the left inguinal region: (a) the open internal inguinal ring (IIR), testicular vessels (TV), and ductus deferens (DD) are present; (b) the hypoplastic testicular vessels (HTV) and the blind end of the DD.

EV, epigastric vessels; EIA, external iliac artery

If the testis or testicular vessels are present, additional trocars (3.5 mm or 6 mm) are introduced under direct vision into the lower abdominal quadrant of the contralateral side and at the level of the umbilicus ipsilateral. In the case of a hypoplastic testis, the testicular tissue is removed. In the case of a well-developed testis, it must be decided which procedure can be applied before mobilization of the testis (Figure 5.8.1.4).

If possible, one-stage orchidopexy, without transection of the vessels, is performed. The testis is mobilized into the scrotum, medially to the epigastric vessels (which is the shortest distance).

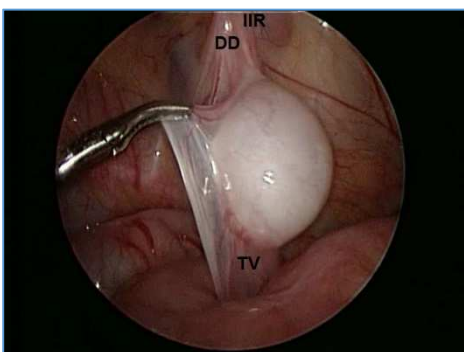


Figure 5.8.1.4. Intra-abdominal testis on the right side
DD, ductus deferens; TV, testicular vessels; IIR, internal inguinal ring

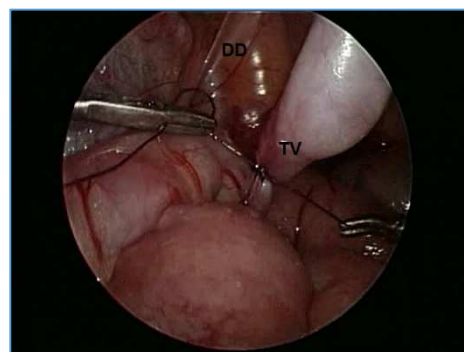


Figure 5.8.1.5. Stage 1: ligation of the testicular vessels

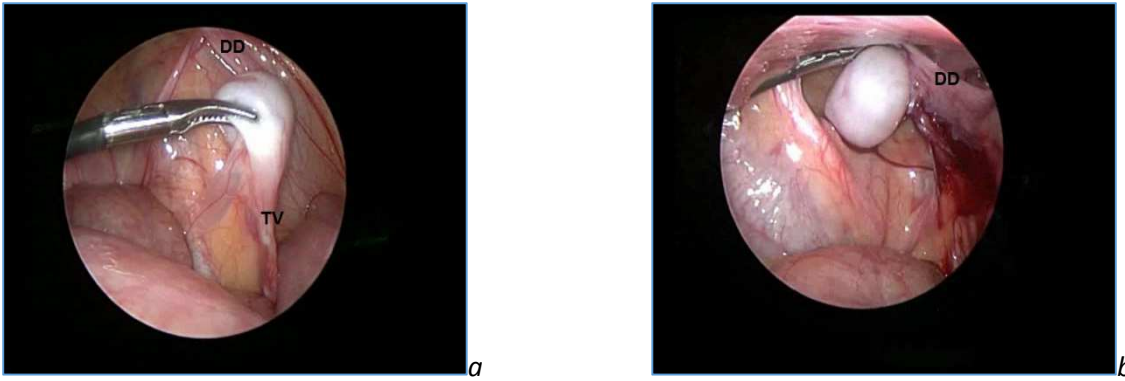


Figure 5.8.1.6 Stage 2: (a) before and (b) after transection of the testicular vessels

If the spermatic vessels are too short, they are ligated or clipped in the Fowler-Stephens procedure, and the testis is left inside the abdominal cavity (Figure 5.8.1.5). At this stage, further mobilization should be avoided to spare the collateral vasculature running along the ductus and at the caudal side of the testis. Three months after the surgery, the second stage of the procedure is performed laparoscopically. The testicular vessels are transected, preferably with scissors (Figure 5.8.1.6). Sealing devices should be avoided to minimize the risk of damage. The testis is mobilized into the scrotum.

The trocars are removed under vision. Inspect for bleeding sites at low intra-abdominal pressure.

Postoperative care

Children usually leave the hospital the same day.

General and specific complications

- Testis atrophy
- Organ injury caused by trocar placement or dissection.

Ergonomics

20-cm long, 3-mm instruments are adequate.

Recommendations

- Before laparoscopy, assess the groin with the patient under general anesthesia; this is necessary to confirm the diagnosis of nonpalpable testis
- Laparoscopy starts with inspecting both the internal inguinal rings
- Sealing devices must be used with caution to minimize the risk of damage to the testis, ductus deferens, and small collateral vessels
- When the two-stage Fowler-Stephens procedure is performed, the testicular or spermatic vessels should be transected during the second stage.

5.8.2. Laparoscopic pyeloplasty

Rafal Chrzan

Introduction

Ureteropelvic junction (UPJ) obstruction is the most common cause of hydronephrosis in children, and it may lead to deterioration of the renal function. Open dismembered pyeloplasty is safe and effective in 90% of the cases. Laparoscopic pyeloplasty in a child was first reported in 1995.

Transperitoneal and retroperitoneal approaches to laparoscopic pyeloplasty have comparable success rates of approximately 95%. The transperitoneal approach provides more working space than the retroperitoneal approach; more space facilitates intracorporeal suturing. If crossing lower pole vessels are present, the transperitoneal approach facilitates the anastomosis of the ureteropelvic junction anterior to the crossing vessels (Figure 5.8.2.1). The retroperitoneal approach minimizes the risk of damage to intra-abdominal organs and the risk of urinary leakage into the abdominal cavity.

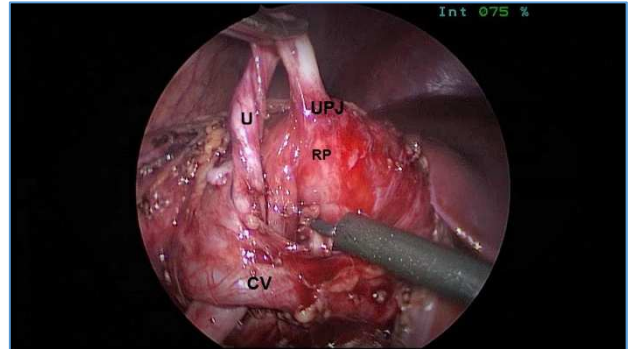


Figure 5.8.2.1. Right-sided hydronephrosis: crossing vessels UPJ, ureteropelvic junction; RP, renal pelvis; U, ureter; CV, crossing vessels

Applicable guidelines

- Guidelines on Pediatric Urology(34)

Indications

The indications for surgical intervention are pain, urinary tract infections, stones, impaired renal function (< 40%), a decrease of renal function of more than 10% in subsequent tests, and an anteroposterior renal pelvic diameter greater than 40 mm or an increase in subsequent ultrasound studies.

Contra-indications

There are no specific pediatric contra-indications.

Preoperative instrumentation

- 30° Optic; 3 mm, 5 mm, or 10 mm
- 3-mm or 5-mm instruments: 2 dissectors, 1 pair of scissors, 1 or 2 needle holders, optionally 1 assistant-needle holder (5 mm)
- A coagulating instrument: a monopolar or bipolar diathermy electrode or any sealing device
- An 11-mm trocar for a 10-mm optic, a 6-mm trocar for a 5-mm optic, or a 3.5-mm trocar for a 3-mm optic
- Two 3.5-mm trocars or two 6-mm trocars

Team check

- Verify the local hospital rules for the time-out procedure
- Prepare for surgery and positioning
- Insert a transurethral catheter before surgery
- Assure that the patient is placed in a lumbotomy or semi-lumbotomy position and then fixed to the table to prevent sliding
- Verify the hospital rules for peri-operative antibiotic prophylaxis

Transperitoneal laparoscopic technique

- Use the Hasson procedure for open introduction of the first trocar (11 mm or 6 mm) at the umbilicus and two 6-mm trocars or two 3.5-mm trocars. The maximum intra-abdominal pressure depends on the age of the child

- Mobilize the colon on the left side. A transmesocolon approach is optional
- Free the pelvis and the proximal ureter from the surrounding tissue
- After excising the stenotic UPJ, spatulate the ureter
- The required JJ stent is usually Ch 4.7, but the size and length are age dependent. The stent is passed through a trocar over a guidewire into the ureter
- Do the ureteropelvic anastomosis with interrupted and/or running 5.0 or 6.0 sutures made of polyglactin or poliglecaprone
- If crossing lower pole vessels are present, mobilize the vessels to the ureteral-pelvic anastomosis anterior to these vessels
- A wound drain is not indicated

Retroperitoneal laparoscopy technique

- The instruments are the same ones used in the transperitoneal approach
- The patient is in the lumbotomy position
- Use the Hasson technique for the open introduction of the first trocar, then develop the retroperitoneal space with an expanding balloon
- If crossing lower pole vessels are present, mobilize the vessels and do the ureteral-pelvic anastomosis posteriorly to these vessels
- Do this anastomosis as it is described in the transperitoneal approach

Postoperative care

The anesthesiologist manages post-operative pain in children.

The patient is discharged after micturition. Advice is given for frequent voiding and for avoiding heavy exercise until the JJ stent has been removed. The JJ stent is removed 3 to 4 weeks after surgery with cystoscopy while the patient is under general anesthesia. The stent is removed on an outpatient basis.

The outcome of the pyeloplasty is evaluated with ultrasonography 6 to 10 weeks following surgery and again at 3 to 6-month intervals during the first year. Evaluation is repeated less frequently after the first year until puberty, depending on local protocols. MAG-3 renography is performed for symptomatic patients and/or patients who present with persistent dilation of the collecting system.

General and specific complications

General complications. The intra-abdominal organs can be injured by trocar placement or dissection.

Specific complications. These include obstruction of the JJ stent, dislocation of the JJ stent, urinary tract infection, irritative bladder complaints caused by the JJ stent, urinary retention, anastomotic leakage, and re-obstruction of the UPJ.

Recommendations

- A transmesocolon approach can be used for left-sided pyeloplasty
- Spatulation of the ureter is necessary to obtain a wide anastomosis
- The purpose of inspecting the pyelum is to identify the presence of any crossing vessels, which must be given careful attention

5.9. Radical cystectomy

Carl Wijburg, Sjoerd Klaver, André Vis, Richard Meijer, Laurent Fossion, Jorg Oddens

Introduction

Radical cystectomy with urinary diversion is a complex, time-consuming procedure associated with substantial morbidity and mortality.(211-214) Open radical cystectomy (ORC) is the gold standard in the treatment of muscle-invasive, organ-confined, and recurrent,high-grade bladder cancer that is non-muscle-invasive. However, minimally invasive techniques [laparoscopic radical cystectomy (LRC) and robot-assisted radical cystectomy (RARC)] have been developed. Minimally invasive procedures are related to faster convalescence and fewer complications. Studies comparing LRC and RARC with ORC show comparable oncological outcomes.(215-218)

LRC is a complex procedure with a long learning curve that requires specific skills, including intracorporal suturing.(219-223) The RARC learning curve is shorter (estimated at 16–30 cases), because of the three-dimensional vision and the dexterity provided by the endo-wrist (six degrees of freedom).(224-227)

Applicable guidelines

- Dutch guideline for urothelial carcinoma of the bladder(35)
- European guidelines on muscle-invasive and metastatic bladder cancer(228)

Indications

The indications for radical cystectomy (LRC and RARC) are summarized in Table 5.9.1.(29, 228, 229)

Table 5.9.1. Indications for radical cystectomy

NMIBC stage Ta-T1 and carcinoma in situ
Recurrent or persistent high-grade NMIBC, stage T1G3 or carcinoma in situ, during intravesical BCG treatment (BCG refractory disease)
Large NMIBC that cannot be resected transurethrally
Muscle-invasive bladder cancer
Tumor stage T2-4a N0-x M0
Recurrence after bladder-sparing therapy (brachytherapy or external beam radiotherapy)
Other indications for considering cystectomy
Persistent hematuria, which necessitates frequent blood transfusions
Severe drug-resistant bladder symptoms (e.g. pain, frequency, and urgency)
Severe urinary incontinence (persisting despite other interventions)
Bladder fistulae (i.e. persisting vesico-vaginal fistula and vesico-enteral fistula)

BCG: Bacillus Calmette Guerin; NMIBC: non-muscle-invasive bladder cancer

Contraindications

General contraindications for laparoscopic and robot-assisted surgery are stated in Chapter 3.

Specific contraindications for RARC and LRC are:(120)

- Prior pelvic surgery
- Prior pelvic radiation

Preoperative preparation

The possibilities of urinary diversion [ileal conduit diversion (Bricker) and orthotopic neobladder] should be offered to the patient. Specializing nurses can provide tailored information.

Instrumentation for RARC

Standard laparoscopic instruments and instruments for the open introduction of camera trocars are used. It is advisable to use one bipolar instrument, one pair of scissors, one needle driver, and one or two instruments for bowel handling. The Cadiere forceps can be used for retraction and bowel handling. A laparoscopic stapler with a length of 45 mm as well as 60 mm should be present in the operating room. Surgeons may stent the ureters differently, but a single J stent or a double J stent is advisable.

Preparation for surgery and positioning for RARC

The patient position is the same as for RARP. For women, the vagina is disinfected and made accessible to the speculum and for specimen extraction.

Transperitoneal LRC

Patient positioning and anaesthesiology

The patient lies in the dorsal decubitus position with his/her arms beside the body. Both legs are slightly spread to allow physical examination of the external genitals and rectum. Put a transurethral catheter in place at the beginning of the procedure. Place the patient in the Trendelenburg position and fix him/her on the operating table to prevent sliding. A nasogastric tube is advisable.

Instruments

The instruments used in LRC are similar to those for laparoscopic radical prostatectomy.

Standard trocar positioning as in laparoscopic prostatectomy is used:

- 5 ports, two of 10 mm and three of 5 mm
- Bipolar grasper
- Monopolar scissors or harmonic scalpel
- Suction device
- Maryland grasper
- Bowel grasper
- Two needle drivers
- Hemolock clips
- Extraction bag

Operating procedure

The operation consists of two major parts:

- Part 1. Ablation: laparoscopic lymph node dissection plus cystectomy or cystoprostatectomy
- Part 2. Reconstruction: creation of the urinary diversion.

Part 1. The laparoscopic pelvic lymph node dissection and radical cystectomy

1. Open port placement (Hasson technique) for the 10-mm camera port – creation of the pneumoperitoneum with a standard pressure of 14–15 mmHg
2. Place the four working trocars under vision: two 5-mm ports in the right lower abdomen, as well as a 5-mm port and a 10-mm port in the left lower abdomen
3. Open the peritoneum laterally and cranially to the iliac vessels
4. Extended laparoscopic dissection of the pelvic lymph node. Resect the lymphatic tissue bilaterally while respecting the following boundaries: the genitofemoral nerve, external iliac artery, external iliac vein, obturator nerve, hypogastric artery, common iliac artery, and sacral bone
5. Free, clip, and transect the ureters. Frozen sections of the distal ureter ends are sent for histopathologic examination
6. Clip and transect the vasa deferentia. They are used as a landmark to open the peritoneum from left to right. Then lift the bladder for the dorsal dissection between bladder, prostate, or uterus and the rectum
7. Open the endopelvic fascia and release the pelvic floor muscles from the prostate

8. The bladder and the prostate pedicles can now be clipped and transected at both sides
9. After completing the dorsal dissection, incise the peritoneum laterally to the umbilical ligaments, and develop the plane between the bladder and the fascia transversalis (Retzius space)
10. The remaining structures are the dorsal venous complex (DVC) and the urethra. Transect both puboprostatic ligaments and the DVC in men. Transect the round ligaments, as well as the broad ligament in women. The next step for women is to open the vagina top and develop the plane between the urethra and the anterior vaginal wall
11. Clip the urethra to avoid spilling tumor cells in the abdominal cavity
12. Place the specimen in an endobag
13. Next, resect the presacral lymph-node tissue and tunnel the left ureter underneath the sigmoid colon
14. Fix both ureters to the abdominal wall to facilitate the reconstruction

Part 2. The minilaparotomy and creation of the urinary derivation

1. The minilaparotomy is 4-5 cm to the right of the navel, starting from the camera port
2. The endobag is extracted and sent for histopathologic examination
3. Both ureters are picked up (Figure 5.9.1.)
4. Separate 15–20 cm of terminal ileum to create a Bricker ileostoma
5. Rinse the ileal conduit with water
6. Create the side-to-side bowel anastomosis by stapling. Close the mesentery of the ileum to avoid herniation of the bowel

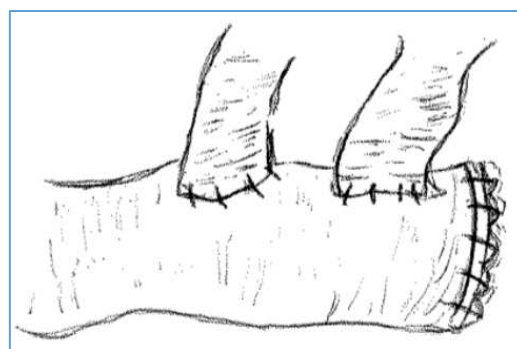

Figure 5.9.1. Ureteral anastomosis of the ileal conduit

7. The cranial part of the ileal conduit is closed and both ureters are implanted separately according to the Nesbitt anastomosis technique (figure 5.9.1), leaving behind a single-J-stent in both ureters
8. The urostoma is created in the right lower abdomen, using one of the 5-mm incisions
9. Close the minilaparotomy wound in layers. Do the same for the trocar ports
10. One drain is left behind and extracted via the remaining 5-mm port

Robot-assisted radical cystectomy

Robotic surgery technique

Trocars are placed as illustrated (Figure 5.9.2).

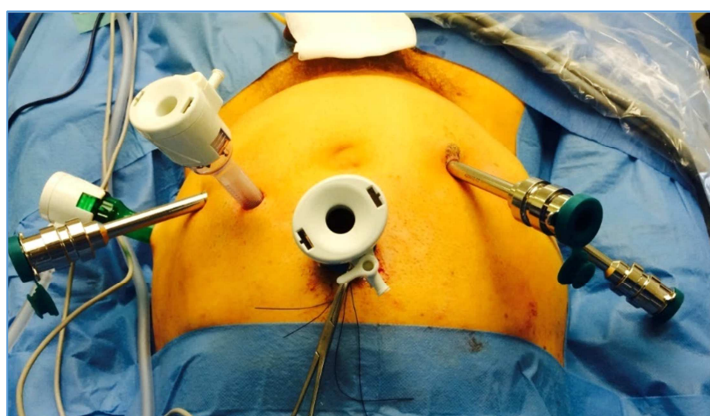


Figure 5.9.2. Trocar positioning

- Camera trocar; 3–4 cm above the navel
- Place three robot trocars in one line, 4 cm caudal to the camera trocar

- Place the third robot trocar at or nearby the pre-operatively marked position for the urostoma
- Place the 15-mm assistant trocar 5 cm cranially to the left spina iliaca anterior superior (to pass the endobag and stapler)
- Place the 12-mm assistant trocar between the camera trocar and the left robot trocar
- Place the patient in a 30-degree Trendelenburg position

Surgical steps in RARC

1. Mobilize the sigmoid colon medially, open the peritoneum, and identify the left ureter without compromising the vasculature of the ureter
2. Place a vessel loop around the ureter for a touch-free mobilization of the left ureter
3. Place two hemolock clips around the ureter near its bladder insertion. Then transect the ureter, and send the distal end for frozen section analysis
4. Incise the peritoneum laterally to the umbilical ligaments, and develop the Retzius space to the endopelvic fascia. Follow the umbilical ligament to its insertion in the internal iliac artery
5. Dissect the pelvic lymph node in an extended way. The template includes the external and internal iliac nodes along with the fossa of Marcille distal to the common iliac bifurcation. dissection of the obturator fossa on the left side
6. Incise the peritoneum in Douglas' pouch and Dennonvilliers fascia. In women, open the vagina top
7. Clip and transect the vascular pedicles
8. Open the endopelvic fascia to free the prostate in men. Identify the right ureter and repeat steps 2–5 and 7 on the right side
9. In women, resect the ventral wall of the vagina. In men, develop the plane between the rectum and the prostate to the apex
10. Dissect the umbilical ligaments near the navel and let the bladder drop
11. Ligate the deep venous complex and perform the apical dissection. This procedure is comparable to RARP
12. Remove the catheter before dissecting the urethra
13. Place a hemolock on the urethra
14. For women, keep the catheter in place for the dissection of the urethra
15. Introduce an endobag through the 15-mm assistant trocar. In women, extract the specimen through the vagina. In men, leave the specimen inside, and remove it at the end of the procedure
16. Close the vagina
17. Check the rectum for lesions
18. Incise the peritoneum by following the right common iliac artery. Next, resect the presacral lymph node tissue and tunnel the left ureter underneath the sigmoid colon

Intracorporal reconstruction

1. Select a 15–20 cm of terminal ileum to create the Bricker loop
2. Isolate this ileum loop by stapling perpendicular to the ileum with a stapler of 60 mm length. If necessary (for obese patients), add an extra 45 mm stapler length
3. Create the side-to-side bowel anastomosis by using staplers with a 60 mm and 45 mm length. Close the anastomosis with a stapler of 60 mm length at the top. The mesentery can be closed, but this is not necessary
4. Spatulate the ureters and connect them to the Bricker loop (with the Nesbitt procedure)
5. Place stents in the ureters
6. After the uretero-ileal anastomosis has been completed, undock the robot
7. Create a urostoma by opening the skin at the marked spot and extract the caudal end of the Bricker loop
8. Extract the specimen through either the opening of the camera trocar or the 15-mm trocar at the lateral side

Postoperative care

In line with fast-track protocols in colorectal surgery, early enteral feeding and early mobilization expedites recovery and reduces the risk of postoperative complications.

General and specific complications

General complications

Radical cystectomy is a complex procedure, with a rather high complication rate. A multi-institutional analysis of 939 patients who underwent RARC shows a complication rate of 41% at 30 days and 48% at 90 days.(133) According to the Clavien-Dindo grading system, 29% of the complications were grades 1–2 and 19% were grades 3–5. Most complications were gastro-intestinal (27%), infectious (23%), and genitourinary (17%).

RARC had lower rates of major complications than ORC at both 30 days and 90 days.(133, 135) However, other studies have found comparable complication rates for RARC and ORC.(230, 231)

There are indications that intracorporal urinary diversion is less prone to gastro-intestinal and infectious complications than extracorporal urinary diversion (OR 0.68; 95% CI 0.50 – 0.94).(232)

Specific complications in RARC

- Specific complications due to patient positioning, trocar placement, bladder resection, and lymph node dissection are described in Chapter 5.6.
- Leakage of the ureter-bowel anastomosis. If it occurs, a ureter stent needs to be placed to secure the anastomosis and prevent further leakage. It is generally assumed that the stents can be removed safely when the patient is mobilized
- If the wound drain production is high, a creatinine value must be determined to differentiate between urine and lymph or peritoneal fluid
- Urinary leakage can be treated conservatively. However, it can cause uremic peritonitis and paralytic ileus. In case of severe leakage or anastomotic disruption, nephrostomies are necessary.
- Stricture of the ureter-bowel anastomosis
- Leakage or ischemia of the ureter-bowel anastomosis may result in strictures. Postrenal obstruction necessitates placement of a nephrostomy or antegrade placement of a JJ stent. When hydro-ureteronephrosis is persistent and/or urinary infections occur, a reconstruction of the ureter-bowel anastomosis is necessary.
- Small-bowel leakage
- Ischemia of the bowel may lead to leakage and stricture of the bowel anastomosis

5.10. Image-guided minimally invasive surgery in an experimental setting: robotic and laparoscopic sentinel node detection

Henk van der Poel

Introduction

Sentinel node (SN) methods improve early detection of metastases in a variety of cancers, which prevents the morbidity associated with more extensive nodal dissection. Laparoscopic indications for SN detection in urology have been experimental so far.(233) Near infra-red (NIR) imaging facilitates the intra-operative detection of SNs better than gamma-probe detection.(234-236) Light at 800-1000 nm (NIR) penetrates tissue better than white light. NIR tracers [such as indocyanine green (ICG)] are visualized by NIR and are not visible in white light. This makes both white-light-guided surgery and NIR-guided surgery simultaneously possible without the NIR tracer obscuring surgical planes, as would be the case with tracers visible in the white-light spectrum.

Basics of fluorescent tracers

Fluorescent tracers or fluorophores can be found in all spectra of light. Several tracers for the NIR spectrum that allow intra-operative imaging are available. Two widely applied NIR tracers are indocyanine green (ICG) and the infrared dye 800CW. ICG is applied for imaging of vascular, bile, and lymph drainage, while 800CW is mainly used for protein labeling.

Fluorophores work through a mechanism of excitation and emission. The Jablonski diagram (Figure 5.10.1) shows the electron excitation of ICG by illumination with light in the 750–780 nm spectrum. ICG absorbs the light energy and expels the energy through photons of a slightly higher wavelength (emitted light). Specific systems of optically filtered cameras can visualize fluorophores at specific wavelengths.

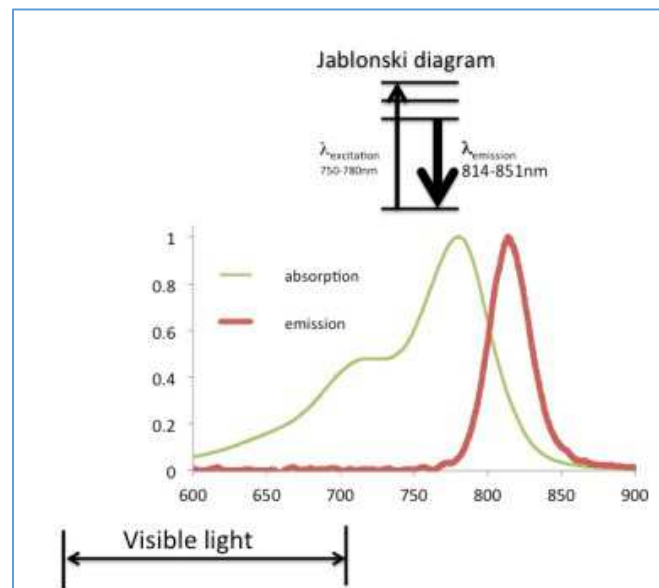


Figure 5.10.1. Jablonski diagram of indocyanine green

Both free ICG and technetium-nanocolloid ICG are used to detect SNs. Free ICG can be injected directly into the prostate several minutes prior to the SN procedure. The use of SPECT/CT and radioactive technetium-labeled ICG helps to anatomically localize SNs preoperatively.(235) The bimodal tracer consisting of radioactive technetium and ICG makes both preoperative and intraoperative SN detection possible (Figure 5.10.2).(236, 237).

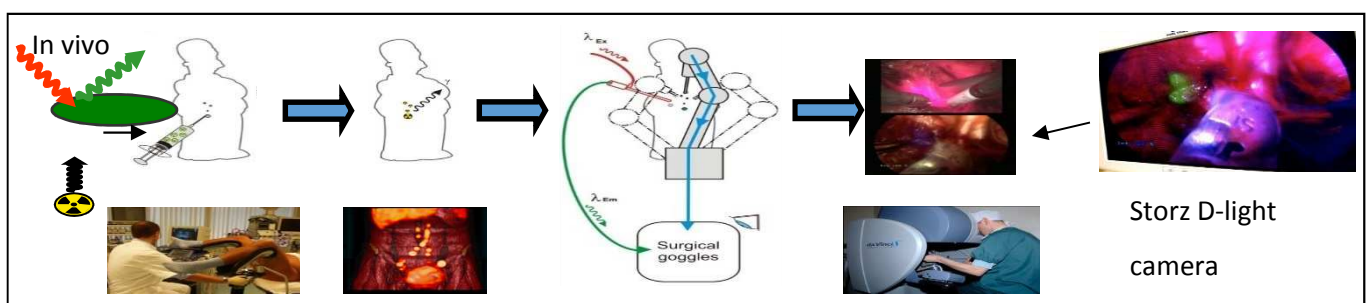


Figure 5.10.2. Multimodal method for the sentinel node tracer

Applicable guidelines

EAU guidelines (238) recommend SN detection for penile cancer, while SN detection for prostate cancer is considered experimental. Other guidelines do not mention the use of SNs for laparoscopic or robot-assisted urological procedures.

Brief summary of evidence, guidelines, standards, and laws

Prostate cancer

In a systematic review, laparoscopic gamma-probe detection of SNs was feasible for 81-100% of 7319 patients who underwent SN detection in prostate cancer management. The addition of intraoperative fluorescent ICG tracing was found to improve the detection rate.(239) The range of false negative SN detections ranged from 0% to 10% in cases where ICG bound to technetium nanocolloid was applied, but was 24.4% in one study that applied free ICG in a robotic setting.

Preoperative SPECT/CT imaging improves the accuracy of anatomical localization. SNs were found in 4-35% of the patients outside the conventional template of the extended lymph-node dissection. The mode of injection (free vs technetium-nanocolloid-bound ICG) and the location of injection (intraprostatic vs intratumoral) are subjects of study.

Bladder, testis and renal cancer

Limited feasibility studies only are available for the bladder, testis, and renal cancer. Lymph drainage patterns from the bladder are poorly understood, and contralateral drainage is frequently reported.(240)

In testis cancer, laparoscopic SN detection has been shown to be feasible for small lymph nodes.(241, 242)

The detection rate of SNs in renal cancer is lower than in other cancers, which suggests that direct lymph drainage into the thoracic duct renders SN detection potentially less useful.(243)

Recommendations

- Laparoscopic and robot-assisted SN detection is considered experimental
- When they are applied preoperatively, the use of technetium tracers improves anatomical localization, particularly for SPECT/CT imaging
- In the absence of nuclear medicine facilities, injection of free ICG into the prostate provides an alternative to technetium-based methods.

5.11 Robot-assisted laparoscopic enucleation of the prostate (RALEP)

Carl Wijburg

Introduction

The standard therapy for large obstructive prostate adenoma (>80 mL) is enucleation of the adenoma with open surgery. The enucleation can also be achieved with robot-assisted surgery.

There are two approaches for the robot-assisted technique: (1) the transperitoneal and transvesical approach and (2) the preperitoneal approach in which the Retzius space is developed and the bladder is opened. There is no preference for either approach. Bladder calculi or a diverticulum can be treated in the same session with the transperitoneal and transvesical approach.

Indications

- Severe lower urinary tract symptoms, caused by obstructive benign prostate hyperplasia, with a prostate volume >80 mL

Contraindications

- Previous extensive abdominal surgery or radiation, which makes a pneumoperitoneum and enough abdominal laparoscopic working space impossible
- Steep Trendelenburg position not possible (Chapter 2.3)
- Hypocontractile urinary bladder

Preoperative preparation

- Informed consent after complete information of the patient
- International Prostate Symptom Score (IPSS) and flowmetry to determine the severity of the symptoms
- Transrectal ultrasound to establish the prostate volume

Robotic instruments

- 0-degree camera
- Needle driver, scissors, and, if needed, a bipolar fenestrated instrument and prograsp
- Two monofilament absorbable sutures, each with a straight needle to be used as temporary bladder sutures
- Multifilament absorbable suture for closure of the bladder mucosa
- Barbed suture to close the prostate capsule and bladder muscle

Preparation for surgery and positioning

See Chapter 5.6.

Robotic surgery technique

1. Trocar placement (Figure 5.11.1.) The trocar placement is the same as in RARP.
 - A skin incision for open Hasson trocar placement should be made just above the navel
 - Pneumoperitoneum pressure should be maximized to 12 mmHg
 - Other trocar placements can follow under camera vision
2. Open the peritoneum laterally to the umbilical ligaments. Open the Retzius space by developing the plane between the fascia transversalis and the bladder, as in RARP (see chapter 5.6.).
3. Remove the periprostatic fatty tissue (Figure 5.11.2.).

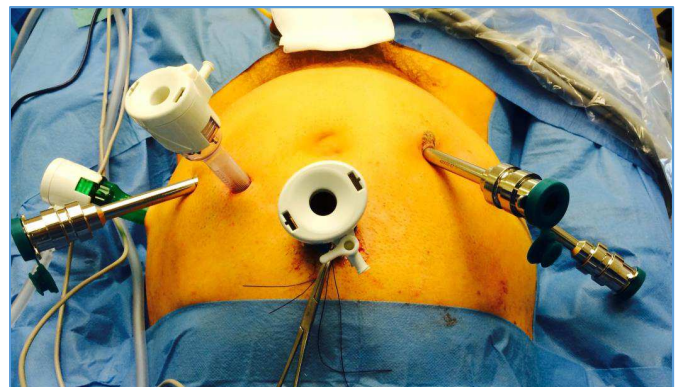


Figure 5.11.1. Standard trocar placement

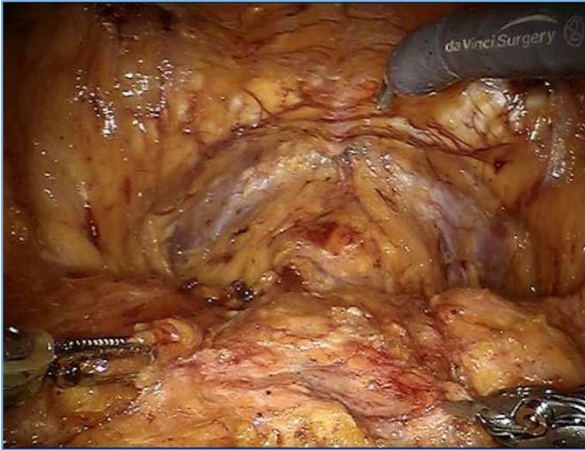


Figure 5.11.2. Opening the Retzius space and removing the periprostatic fat

4. Open the bladder in the midline, in longitudinal direction (Figure 5.11.3). Extend the incision to halfway the prostate capsule and use bipolar energy for coagulating any bleeding vessels in the prostate capsule or bladder.

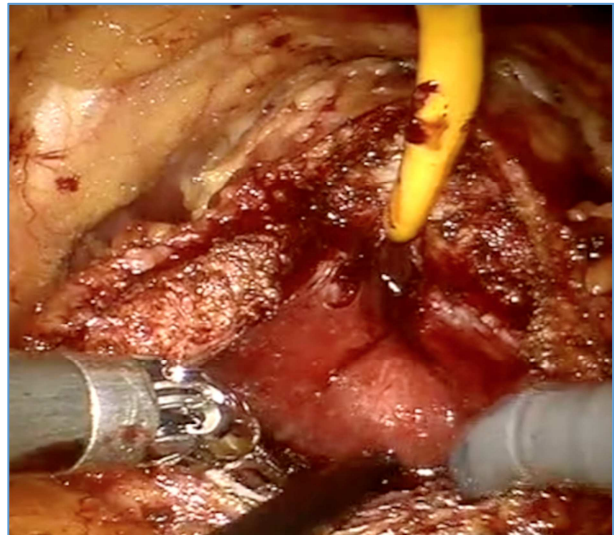
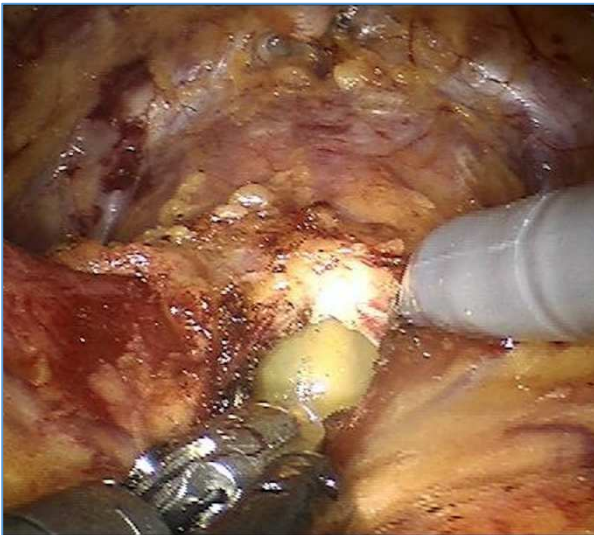


Figure 5.11.3. Opening of the bladder in the midline

5. Inspect the bladder for calculi and, if any are present, remove them.
6. Introduce temporary bladder sutures with long straight needles through the abdominal wall, pass them through the bladder, and then return and fix them (Figure 5.11.4.).
7. Identify the ureter ostia and incise the bladder mucosa distally, about 5 mm dorsally to the middle lobe of the prostate adenoma. Use the prograsp to lift the adenoma (either directly or with a traction suture).

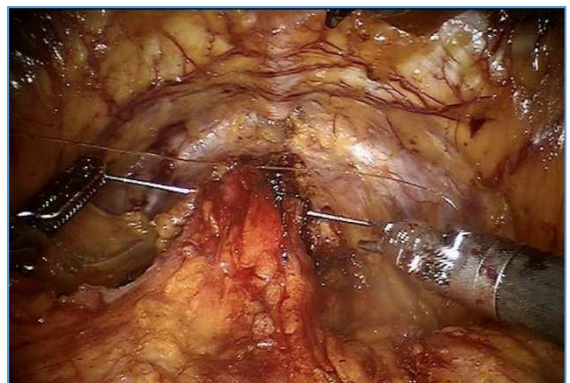

Figure 5.11.4. Straight needle passed through the bladder

8. Find the surgical plane between the adenoma and prostate capsule (Figure 5.11.5). Start at the left side and dorsally. Coagulate small vessels. Then continue to the apical side.

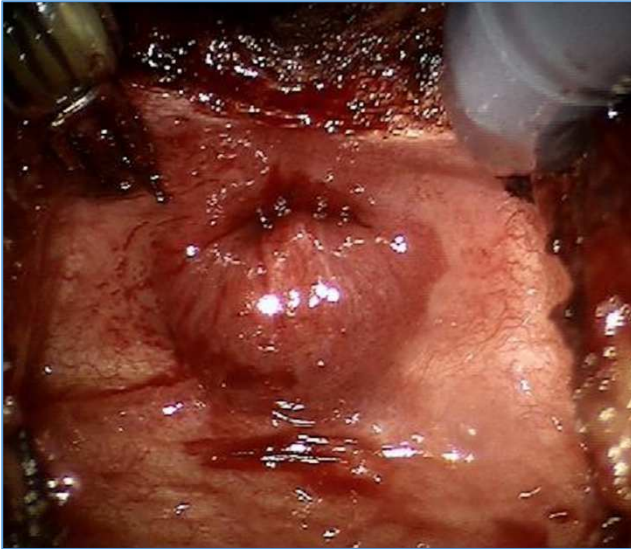


Figure 5.11.5. Identification of the surgical plane

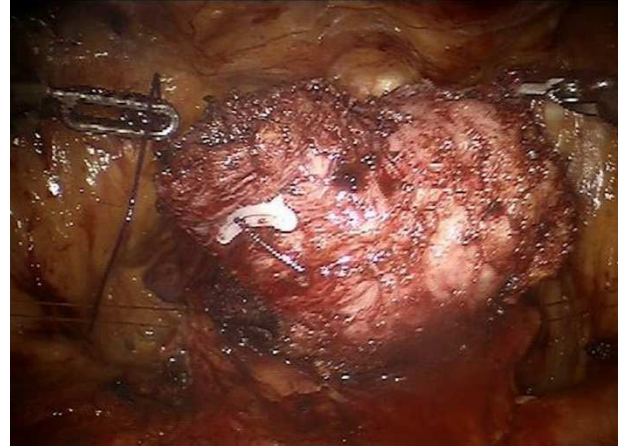


Figure 5.11.6. Enucleation of the adenoma

9. For the right side, switch the two right arms to gain more working space and less collision of the instruments. Repeat the procedure in the previous step.
10. At the apical side, incise the urethral mucosa and retract the adenoma cranially (Figure 5.11.6).
11. Place the specimen in an endobag
12. Rinse the surgical field and coagulate small vessels.
13. Use a barbed suture to approximate the bladder mucosa towards the urethra, paying extra attention to large vessels (Figure 5.11.7.).

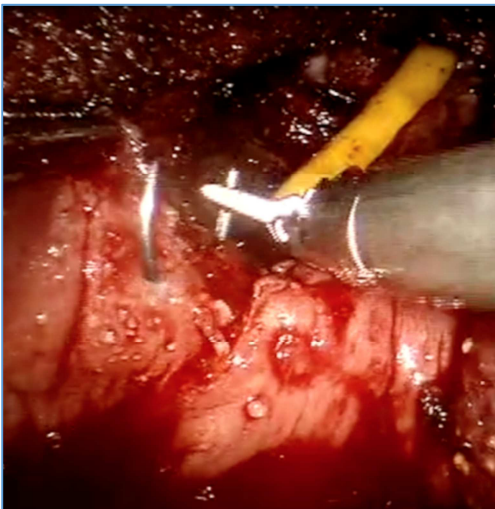


Figure 5.11.7. Approximation of the bladder mucosa to the urethra

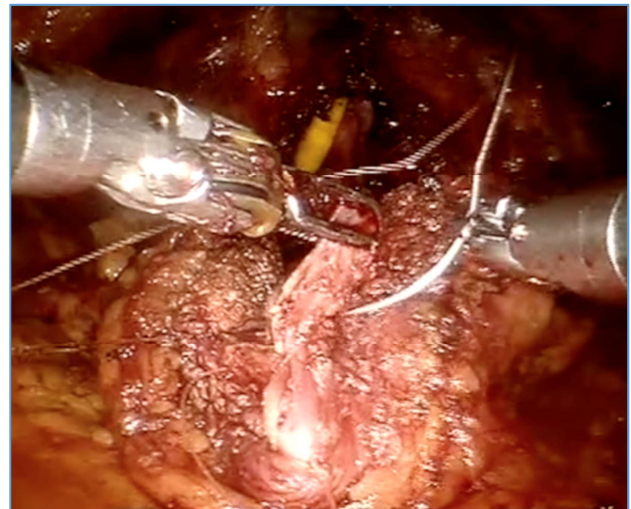


Figure 5.11.8. Closure of the bladder

14. Introduce a three-way catheter and inject 10 mL of water into the balloon.
15. Start closure of the bladder mucosa with a multifilament absorbable suture.
16. Close the prostate capsule and the bladder muscle with a barbed suture, and check for any leakage by filling the bladder with 200–300 mL of water (Figure 5.11.8.).
17. Inject an extra 20 mL of water into the catheter balloon (30 mL in total).
18. Place a drain in the Retzius space, remove the trocars under camera vision, and extract the endobag through the camera-port incision.
19. Rinse the bladder extensively and continuously until the urine is clear and has no blood clots.

Postoperative care

- Check the blood pressure, hemoglobin, and electrolytes
- Continue rinsing if necessary
- Aim for discharge on the second postoperative day
- Perform urine culture, before catheter removal (1 week following surgery)
- Check for retention after micturation
- Outpatient clinic appointment at 6 weeks, at which time the IPSS is calculated and flowmetry is done

General and specific complications

- Wound bleeding and infection
- Urinary tract infections
- Urine leakage through the bladder or prostate capsule wound
- Stress or urge urinary incontinence
- Incisional hernia

Tips and tricks

Use a 5 to 10-cm multifilament absorbable suture, with a hemolock at the end, followed by a knot (also known as the Pinocchio stitch). This will prevent it from slipping off. The prostate adenoma can be retracted out of the surgical field with this stitch, which creates more working space.

5.12. Robot-assisted laparoscopic ureterolysis and omental wrap

André Vis

Robot-assisted laparoscopic ureterolysis and omental wrap is a demanding procedure, which can be performed by experienced console surgeons.

Indication

The indication for this procedure is retroperitoneal inflammation and fibrosis involving one or both ureters.

Prior to surgery, conservative treatment with corticosteroids and/or tamoxifen has been given, and the ureter has been stented with JJ catheters. The aim of the procedure is to achieve free ureteral passage without the necessity of immunosuppressive medication.

Preoperative preparation

It can be difficult to find the ureter in the fibrotic tissue. Therefore, it is important to identify the anatomical position of the ureter with preoperative imaging.

Patient positioning

The patient positioning is similar to that for robot-assisted nephrectomy or robot-assisted pyeloplasty with the patient in the left or right flank position. The robotic instruments should be able to reach the total length of the ureter from the pelvis to the ureterovesical junction.

Procedure

Place JJ stents to facilitate the identification of the ureters. Open the white line of Toldt to mobilize the colon, then use blunt and sharp dissection to initiate ureterolysis near the renal hilum. Mobilize the ureter circumferentially. (The ureter often has a blue or gray appearance). Use a vessel loop around the freed part of the ureter. This can provide traction and facilitates dissection. Once the ureteral mobilization is complete, retract the ureter from the retroperitoneal space into the peritoneal cavity. Close the retroperitoneal defect with sutures. Prepare a strip of greater omentum and place it between the ureter and the retroperitoneal defect (Figure 5.12.1). Fix the wrapped omentum around the ureter with clips (Figure 5.12.2). Fix the omentum to the distal parietal peritoneum at the level of the vessel crossing to prevent retraction. If necessary, treat the contralateral ureter similarly.

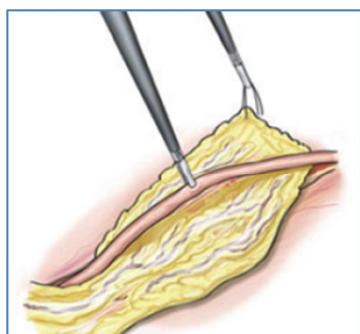


Figure 5.12.1. The omentum is wrapped around the ureter

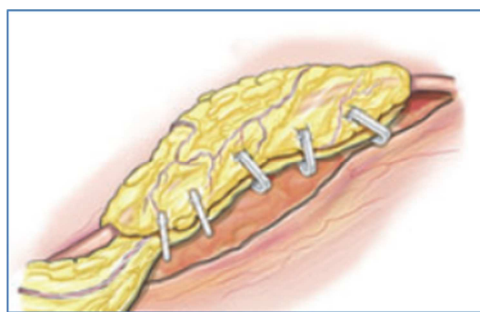


Figure 5.12.2. Ureter fully packed in omentum

Postoperative care

Postoperative care consists mainly of identifying urine leakage. Patients are regularly discharged on the second postoperative day. The JJ stents remain in place for 2 to 3 weeks. Follow-up consists of nuclear functional studies at 3 to 6 months postoperatively to evaluate urinary passage.

5.13. Robot-assisted partial cystectomy for bladder endometriosis

Carl Wijburg

Introduction

Endometriosis, the presence of functioning endometrium outside the uterine cavity, is the most common benign gynecologic disease. It affects 6–10% of women in their reproductive age, of whom 50–60% have pelvic pain and up to 50% have infertility.(244) Endometriosis occurs as a peritoneal, ovarian, or deeply invasive disease. Deeply invasive disease can be present in the pouch of Douglas, close to the rectosigmoid, in the uterosacral ligaments, and in the urinary tract. Urinary tract endometriosis has been reported to have a prevalence of 0.3–12% among women with endometriosis.(245) In approximately 90% of such cases, the endometriosis is located in the bladder.(246)

Endometriosis can be treated medically with pain relief or hormonal preparations, or surgically by removing endometriotic lesion. Medical treatment rarely definitely cures bladder endometriosis, and the recurrence rates are high. Therefore, radical excision of the lesion is considered the treatment of choice, despite the lack of randomized controlled trials.(247, 248) Surgical treatment may be carried out with laparotomy, which results in a large scar and a prolonged convalescence time. As an alternative, a robot-assisted procedure can be offered, which results in a shorter recovery time and better cosmesis.

Indication

Partial cystectomy is indicated for invasion of endometriosis in the bladder.

Table 5.13.1. Contraindications for robot-assisted partial cystectomy

Absolute contraindications	
Severe cardiac comorbidity:	Severe aortic or mitral valve insufficiency
	Intracardiac shunts (heart septal defect)
	Severe heart failure (NYHA III–IV)
High intracranial pressure (risk of intracranial hemorrhage)	
High intraocular pressure (risk of retinal hemorrhage)	
Severe uncorrected coagulation/bleeding disorders	
Relative contraindications	
Severe chronic obstructive pulmonary disease (e.g. pulmonary emphysema)	
Prior pelvic treatment:	Surgery, including trauma surgery
	Radiotherapy
Prior abdominal surgery (with extensive intraperitoneal adhesions)	

Preoperative preparation

- The indication for surgery should be discussed by a multidisciplinary team that includes a gynecologist, a general surgeon, a urologist, and a radiologist
- Cystoscopy
- Physical examination and transvaginal ultrasound
- MRI of the pelvis (Figures 5.13.1 and 5.13.2)
- Informed consent should be obtained after possible complications during and after surgery, and alternative treatment strategies have been discussed with the patient

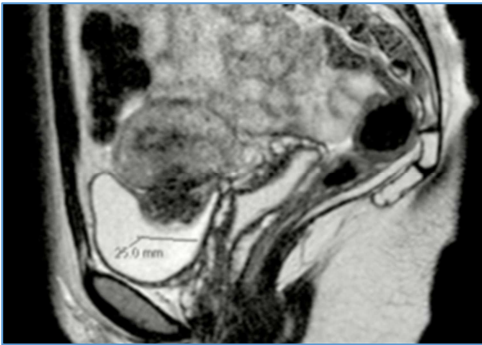


Figure 5.13.1. Sagittal MRI

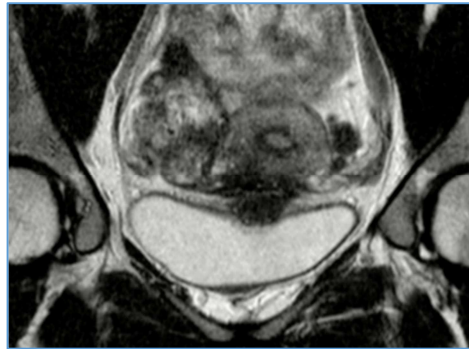


Figure 5.13.2. Coronal MRI

Instruments and sutures

- Robot: scissors, needle driver, bipolar fenestrated forceps
- Three robot trocars; and one or two assistant trocars, of which at least one has a diameter of 12 mm
- Multifilament absorbable suture 3/0 for closure of the bladder mucosa
- Barbed suture to close the bladder muscle

Patient preparation and positioning

- Standard robotic set-up, with legs in leg holders
- Robot side docking on the right side of the patient
- Cystoscopy with a rigid scope
- Table for the assistant on the left side of the patient
- The patient in the Trendelenburg position at 25 degrees

Robot-assisted surgery technique

- Skin incision for open Hasson trocar placement just above the navel
- Pneumoperitoneum pressure maximized to 12 mmHg
- Other trocar placements follow under camera vision
 - Two robotic trocars on the right side, with an 8-cm space between the camera and the robotic trocars
 - One robotic trocar on the left side, 8–10 cm from the camera trocar
 - One 12-mm assistant trocar just above the left spina iliaca anterior superior. One 5-mm assistant trocar can be placed cranially between the left robot and the camera trocar, if needed
- Pelvis inspection with the gynecologist and bowel inspection with the general surgeon on indication
- Dissection of the plane between the bladder and the uterus (Figure 5.13.3)

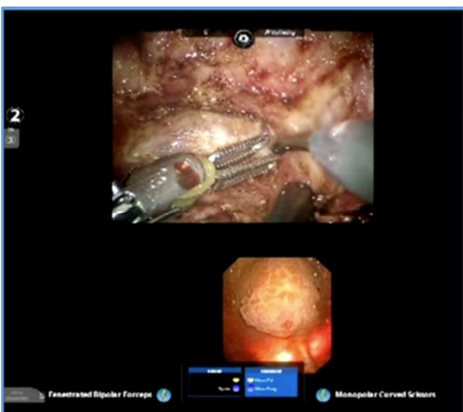


Figure 5.13.3. Dissection in the surgical plane between the uterus and the bladder wall

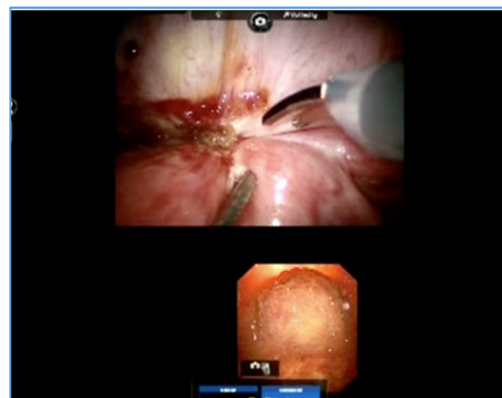


Figure 5.13.4. TilePro view of simultaneous cystoscopy and laparoscopy

- Picture-in-picture with simultaneous cystoscopy (Figure 5.13.4)
- Identification of the bladder endometriosis
- Open the bladder just above the endometriosis in the bladder wall
- Dissection of the endometriosis with partial cystectomy; be aware of the ureteral orifices (Figure 5.13.5)
- Place the specimen in an endobag
- Close the bladder mucosa and the muscle separately (Figure 5.13.6 and 5.13.7)
- Place the catheter and test the bladder for leakage
- Remove the trocars
- Retrieve the endobag through the camera trocar opening
- Close the fascia and skin. No drainage needed

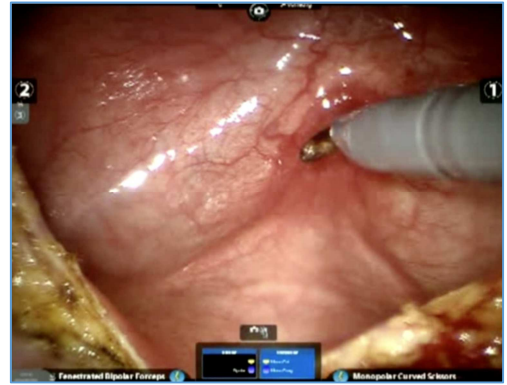


Figure 5.13.5. Identifying the ureteral orifices

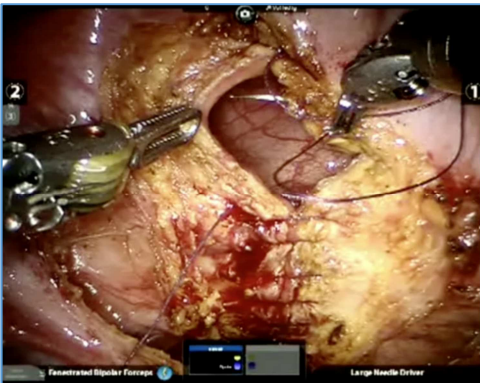


Figure 5.13.6. Closing the bladder mucosa with absorbable suture

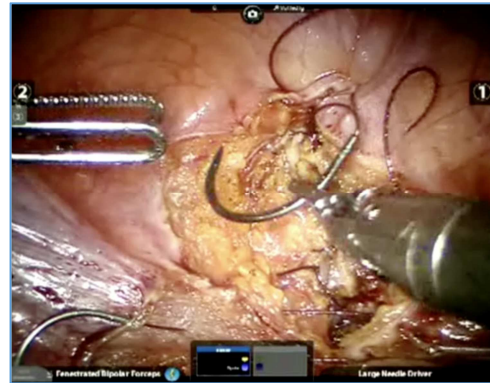


Figure 5.13.7. Closing the detrusor muscle with a barbed suture

Postoperative care

- Discharge the patient with catheter when she is pain free and without fever
- Cystogram after 2 to 3 weeks and catheter removal in the absence of leakage
- Cystoscopic control after 3 months
- Further follow-up by the gynecologist

Complications

- Standard laparoscopy risks of bowel lesions
- Urinary leakage. Check the cystogram or the computed tomography intravenous urogram (CT-IVU)
- Ureteric lesion; check the ultrasound or CT-IVU
- Urinary tract infection; a culture is standard at the time of catheter removal

5.14. Laparoscopic and robot-assisted radical nephro-ureterectomy

Flip Jansen, Fieke Prins, Maurits Barendrecht, Arto Boeken Kruger

Indications

Radical nephro-ureterectomy is the standard of care in high-risk upper-tract urothelial carcinoma (UTUC), regardless of the tumor location. Other indications are suspicion of infiltration of UTUC on imaging, high-grade urinary cytology, multifocality (with two functional kidneys), and low-risk but large UTUC (>1 cm).(32)

Besides oncological indications, severe emphysematous pyelonephritis may be also an indication for radical nephro-ureterectomy.(249)

Surgical approaches

The open nephro-ureterectomy has been the gold standard of treatment for UTUC for decades. Since several reports have shown identical oncological results and superior peri-operative outcomes (less blood loss, shorter hospital stay, and decreased analgesic use), this standard has shifted towards the laparoscopic approach.(250) Regarding the group of locally advanced tumors (pT3/pT4), there is conflicting evidence whether oncological outcomes for the two surgical approaches are comparable.(250, 251)

Either the transperitoneal approach or the retroperitoneal approach can be used for a laparoscopic nephro-ureterectomy. The retroperitoneal access route might result in shorter hospital stay and time to first oral intake.(252)

Various surgical techniques addressing the excision of the distal ureter and bladder cuff have been described. In short, most studies have shown that local recurrence, the development of metastases and cancer specific survival depend on the tumor stage and are independent of the surgical technique.(253, 254)

Open resection (by the transvesical or extravesical approach) is the standard technique. The second most common approach is the Pluck technique in which a transurethral resection of the ostium and transvesical ureter is followed by a laparoscopic dissection of the distal ureter. The Pluck technique is not advisable for distal ureteral tumors because of the increased risk of incomplete resection and tumor seeding. The third approach, purely laparoscopic, can be used when the ureter is dissected by an extravesical approach. An alternative is the extravesical stapling of the distal ureter, but this technique leaves the ostium in place in 50% of the patients and has an increased risk of recurrences of bladder cancer and positive margins.

Nephrectomy

Regarding the nephrectomy, the preparations and procedure are identical to those described in the section on laparoscopic and robot-assisted radical nephrectomy (Chapter 5.3).

Open dissection of the distal ureter

After the laparoscopic nephrectomy, slightly reposition the patient to a supine position. A lower midline, a modified Pfannenstiel, or a Gibson incision provides access. First, expose the bladder, clip the lower ureter, and dissect it free. Then, after filling the bladder, create an anterior cystotomy with two stay sutures. Identify the ureteral orifice and excise it carefully. Placing a suture through the orifice may help in handling the intramural dissection of the ureter. Alternatively, place a ureteral stent. Dissect the ureter intramurally, so that the specimen can be removed en bloc. Then close both cystotomies. The approach to manage the bladder cuff already described is particularly useful for distal ureteral tumors.

Alternatively, the bladder cuff may be secured in an extravesical approach.

Postoperatively, leave a catheter in place and perform cystography after 7–10 days.

Pluck technique

Place the patient in the dorsal lithotomy position for the laparoscopic part of the nephro-ureterectomy. Insert a resectoscope transurethrally, then put a ureteral stent in place, and use a Collins knife to dissect the

ureteral orifice. Disengage the ureter from the bladder wall. Then the patient must be repositioned for the nephrectomy. During the laparoscopic dissection of the distal ureter, traction on the incised bladder cuff enables the mobilization of 3–4 cm of distal ureter into the bladder. The entire ureter can then be pulled through in a cephalad fashion.

Pure laparoscopic approach

In a purely laparoscopic approach, the trocar placement is identical to that of a radical nephrectomy except that the trocars are positioned more caudally, and the ureter is dissected caudally after the nephrectomy. Then the extravesical approach can be used to dissect the distal ureter and a bladder cuff. The bladder is closed in a suture reconstruction.

Robotic radical nephro-ureterectomy technique

Rha et al describe variations and modifications in another method.(255) It is technically feasible to perform both the nephrectomy and the distal ureterectomy, then optionally dissect a lymph node without the need of intraoperatively repositioning either the patient or the robot..

Lateral flank positioning

In the trocar placement (Figure 5.14.1):

- The camera trocar laterally and cranially to the navel.
- A 12-mm trocar, in which the 8-mm robotic trocar is placed in the superior umbilical region, midway between the navel the xiphoid process, becomes assistant the trocar during the ureterectomy when the 8-mm robotic trocar is taken out.
- An 8-mm robotic trocar is placed at the lateral rectus margin 3-4 mm below the navel.
- A 12-mm assistant trocar between the navel and symphysis pubis becomes the robotic trocar during the ureterectomy when the 8-mm robotic trocar is put in place.
- Another 12-mm assistant trocar is placed just below the xiphoid process.

The distance between the camera trocar and the robotic trocars is approximately 8 cm.

Robot placement. Docking takes place with the axis of the robot towards the kidney in the first part of the operation, and then takes place with the axis towards the hip while the distal ureter is being dissected (Figure 5.14.2).

Figure 5.14.1. An example of trocar placement for a robotic-assisted right nephro-ureterectomy. The cranial side is to the right. By changing robot trocars and the alignment of the robot, both the nephrectomy and the ureterectomy can take place with no repositioning of the patient. The changeable robot trocar is placed in a 12-mm trocar (hybrid trocar sites). While the third arm of the robot is in use, either assistant trocar can be made available by inserting a robot trocar instead

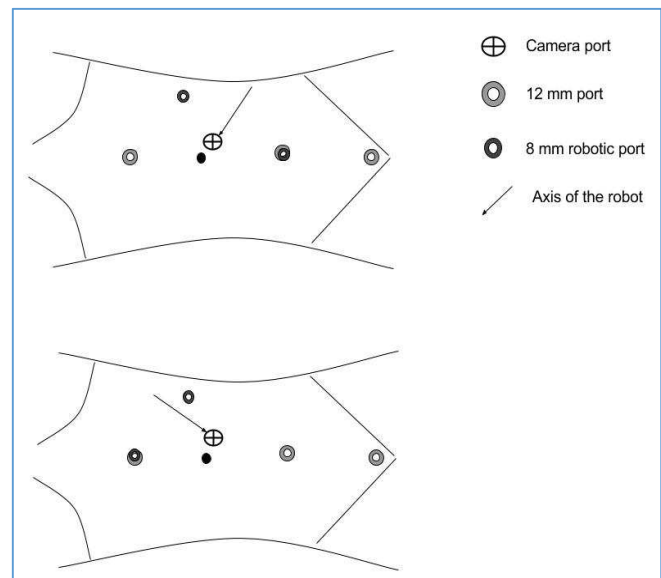

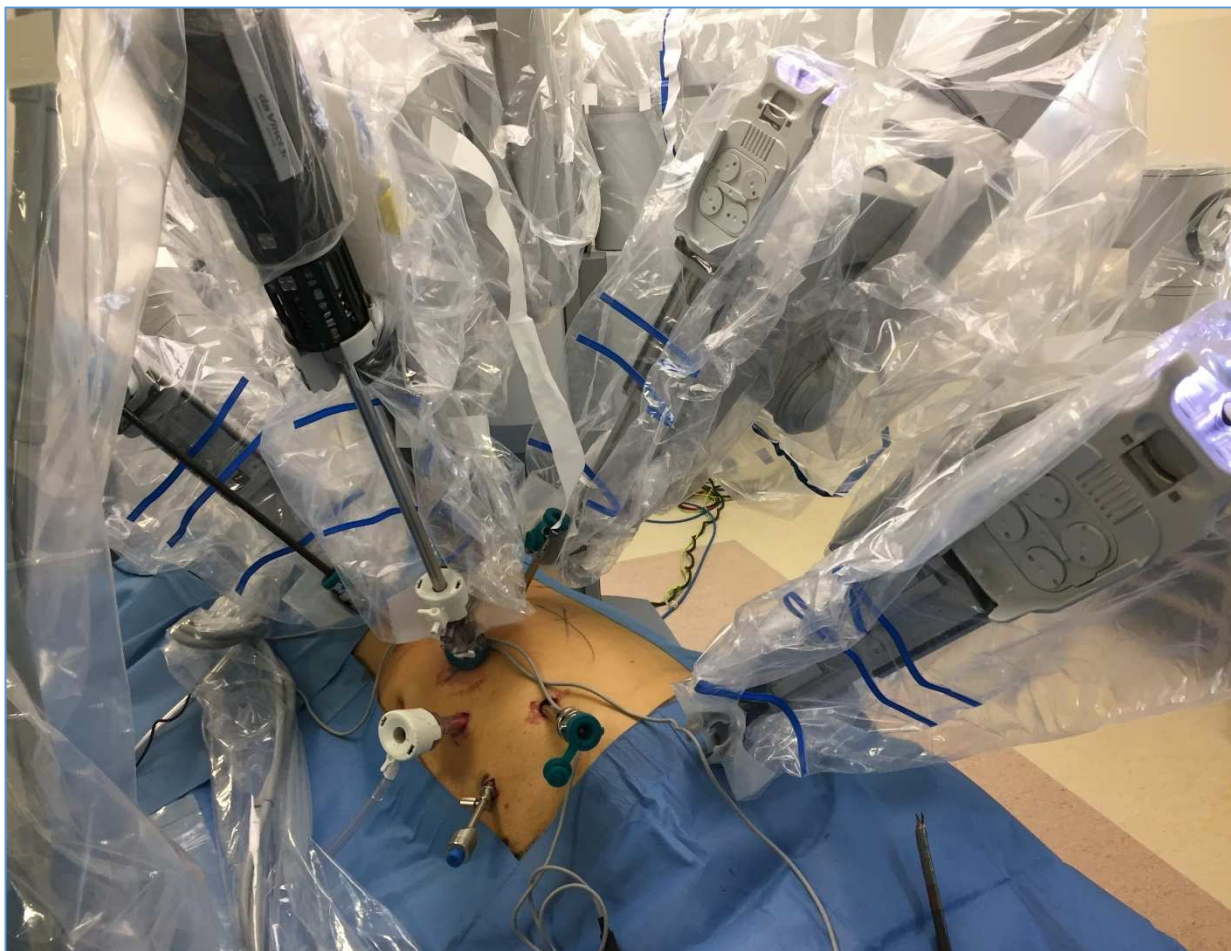


Figure 5.14.2. Robot position after redocking for the distal ureterectomy with the use of the third arm.

Procedure

First, identify the ureter and follow it to the renal hilum. Dissect the renal artery and vein as in a radical nephrectomy (Chapter 5.3.). After complete dissection of the kidney, follow the ureter towards the bladder. The robotic axis changes for the distal ureterectomy. The robot arm that was attached to the 8-mm trocar at the lateral rectus margin is now positioned in the 12-mm trocar caudal to the navel. The 12-mm trocar cranial to the navel now serves as an assistant trocar.

Dissect the ureter up to the bladder wall. Excise the ureter cuff as has already been described. Close the defect of the ureteric orifice by suturing in layers. Test the closed defect by inserting 100–150 ml of saline solution. Extract the specimen in an entrapment bag, preferably through a McBurney incision.

Lymphadenectomy in upper-tract tumors

Introduction

Lymphadenectomy is a well-established part of the treatment of bladder cancer. However, there have been no large randomized studies about whether a lymphadenectomy in upper urinary tract tumors is useful or not. Moreover, scientific information about the extent of the lymph node resection is lacking.

The influence of lymphadenectomy

Lymphadenectomy may be used as a staging procedure, but it is unknown whether it has any therapeutic effect.(256)

Patients with a renal pelvis tumor may possibly benefit from a retroperitoneal lymph-node dissection. The cancer-specific survival rate at 5 years is 90%.

Template

Kondo and Martin conducted mapping studies of metastases related to the site of the primary tumor.(257, 258) Figure 5.14.3 shows the proposed anatomical templates of lymph-node dissection for upper urinary tract tumors in relation to the tumor site.

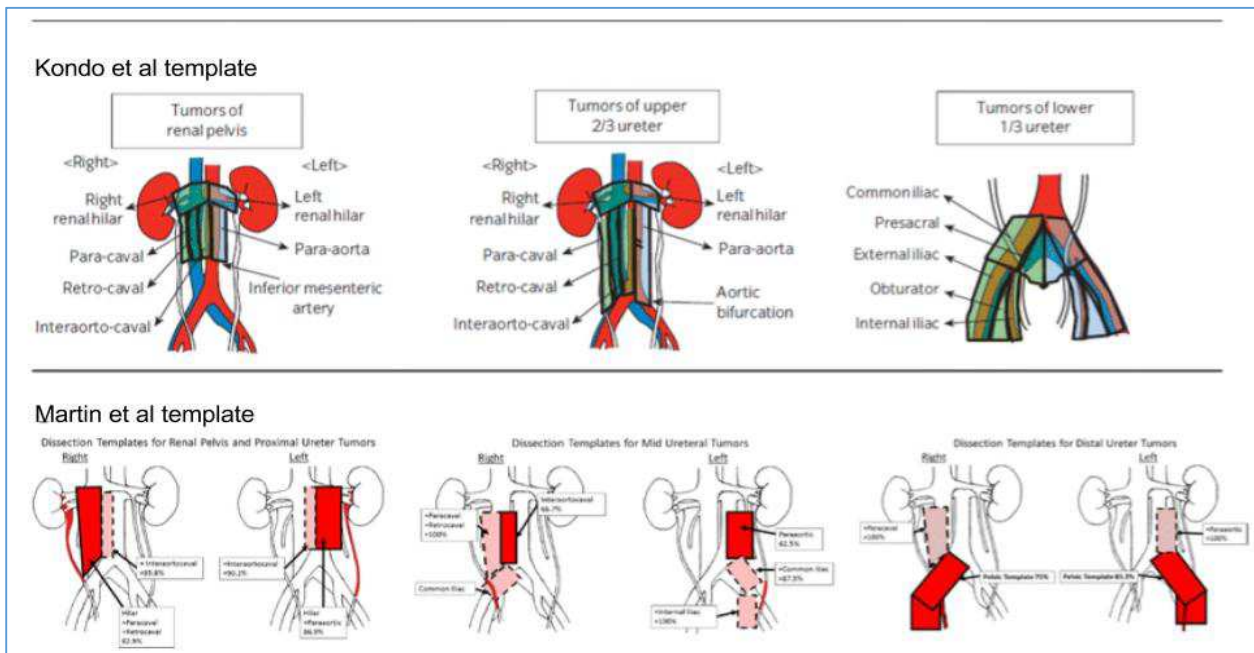


Figure 5.14.3. Suggested templates (adapted from Seisen et al)(259)

Postoperative intravesical instillations

There have been several reports on the use of intravesical chemotherapy to prevent the occurrence of intravesical cancer after nephro-ureterectomy. Two recent meta-analyses show a wide heterogeneity of treatment regimens (differences in drugs, timing, and number of instillations).(260, 261) However, in spite of this heterogeneity, both studies conclude that there is a significant decrease in occurrences of bladder cancer if patients receive any form of postoperative instillation. Although the optimal treatment regimen needs to be explored, we advocate the use of at least one postoperative instillation of intravesical chemotherapy before removing the catheter after nephro-ureterectomy.

5.15. Future perspectives

5.15.1. 3D imaging in the operating theatre

Fokko Wieringa, Geert Smits

Introduction

During surgical procedures, team members must focus on various individual tasks while they maintain a shared situational awareness. One of the most important components of situational awareness in surgery is spatial perception. We define spatial perception here as the interaction of people with their 3D environment. Spatial perception involves a combination of vision, proprioception, and complex mental tasks. The more delicate visually guided motor skills become, the more demands are placed on shared perception. For example, the teamwork between the surgeon and the assistants requires complex eye-hand coordination.

Stereoscopic laparoscopy systems, which offer depth perception by means of stereopsis, are available in hand-held laparoscopes and in surgical robots. Three-dimensional (3D) monitors improve shared perception for the whole surgical team. Standardized dry lab experiments have shown that delicate teamwork is up to 40% faster when a 3D monitor is being used.(262)

Observations in clinical practice confirm this. The introduction of an auxiliary 3D monitor for the assistants at the operating table had a positive impact on robot-assisted partial nephrectomies. Operation times and warm ischemia times were significantly reduced.(263)

Apart from the live 3D video stream, computers can offer support for the complex memory task of constructing a 3D map of the surgical field. This has been demonstrated off-line and applied in surgical simulators, but is still being developed.(264)

Technologies

We distinguish the following categories of 3D visualization methods:

- A. *Active polarization glasses.* A video monitor alternatively displays the left (L) and the right (R) eye images over time while the users are wearing LCD shutter glasses that are electronically (and usually wirelessly via infrared light pulses) synchronized to present both eyes with the correct image. This usually results in a slightly flickering image, but it has very good separation between the images for both eyes (low “ghosting”). Because the L and R images alternate over time, the effective 3D video frame rate is just half as fast as the monitor frame rate (Figures 5.15.1.1 and 5.15.1.2).
The glasses need a battery, and they are relatively heavy and expensive. Without the 3D glasses, the monitor shows a double image. Because active glasses are only synchronized to one particular monitor, they can provoke a nuisance interference flicker while other electronic displays are being viewed.
- B. *Passive polarization glasses.* A 3D video monitor simultaneously displays the left and the right eye images with two different types of optical polarization. The users wear 3D glasses containing filters with matching, but different, polarizations for the left and right eyes. Hence, these passive glasses do not need synchronization. They do not need a battery, and they are lightweight and cheap. Without 3D glasses, the monitor shows a double image. Passive glasses are usually not a nuisance when other electronic displays are being viewed.
- C. *Autostereoscopic (no glasses needed).* A 3D video monitor emits the left and right eye images in different viewing angles so that each eye selectively views the appropriate image. Autostereoscopic 3D monitors presently offer inferior depth perception and are inherently more vulnerable to ghosting, but technical improvements are rapidly emerging. There is usually only a limited viewing position range where the user experiences the 3D effect.

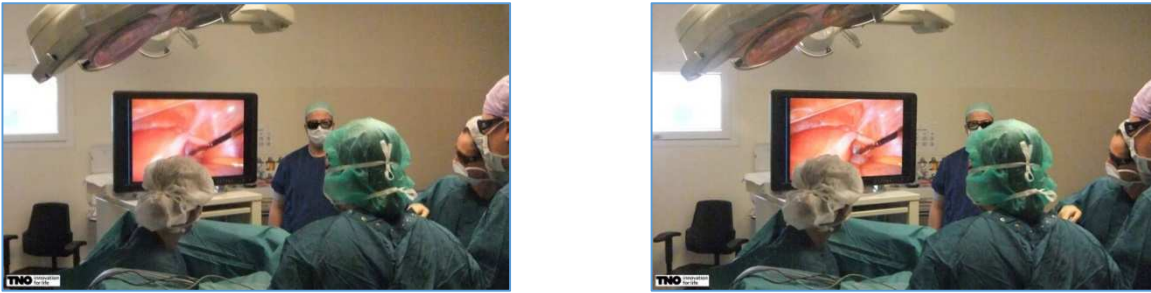


Figure 5.15.1.1. Two photos, taken exactly simultaneously through a pair of 3D-glasses; the left photo through the left glass, and the right photo through the right glass.

Note the subtle differences in the 3D monitor images and the surrounding scene, which are depth clues, and note the 3D glasses of the person next to the monitor alternating in transparency. The monitor screen does the same. This enables the left and right eyes to receive separate images from one monitor

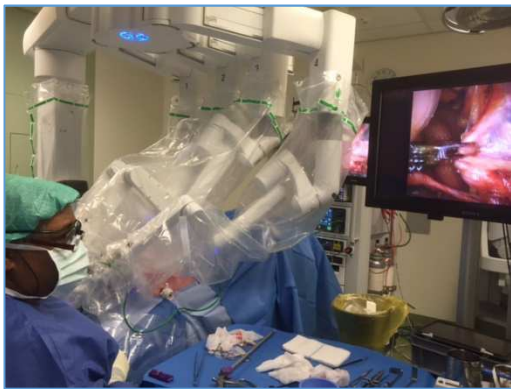

Figure 5.15.1.2. Operation assistant with 3D glasses

Take-home messages

3D vision systems with passive glasses presently offer the best user experience. The assisting staff should be involved in their purchase, several systems should be compared, and extra attention should be paid to ghosting. View a single dark suture against a light background, and a single light suture against a dark background. No extra “ghost” suture should be visible in either case.

5.15.2. Future perspective: fluorescence-guided surgery

Fokko Wieringa

The currently available FDA-approved fluorescents are indocyanine green (ICG) and methylene blue (MB). Both emit in the near infrared, which penetrates relatively well through human tissue and enables visualization of deeper tissue. Both ICG and MB are given intravenously. MB easily passes through the kidney and is excreted into the pyelum and ureter, so that it can be used for ureter visibility. After MB infusion, ureters can be visualized within 10 minutes, and the visibility lasts up to 60 minutes.(265) ICG is not excreted due to its affinity to albumin, and it augments the visualization of blood vessels.

Other developments in fluorescence-guided urologic surgery include:(266)

- Kidney transplantation: kidney allograft perfusion and vessel reconstruction
- Angiography perfusion of tissue flaps
- Visualization of urinary calcifications
- Male infertility and semen quality assessment

The current laparoscopic instruments for visualizing ICG and MB can see one of these fluorescents, or they cannot distinguish between them. Recently, a CE-marked and FDA-approved technology has been developed. It enables the combination of normal laparoscopic vision, with simultaneously viewing of both ICG and MB fluorescence, either separately or in parallel.(267)

References

1. Inspectorate DHC. Risks of minimally invasive surgery underestimated.; 2007.
2. Inspectorate. DHC. Inadequate precision in the introduction of surgical robots.; 2010.
3. Van Basten J, Beerlage, HP, Tjiam I. Recommendations laparoscopy in urology [Aanbevelingen laparoscopie in de urologie].2010.
4. Urology EAo. Guidelines on laparoscopy. 2002 [Available from: www.uroweb.org.
5. Urology. EAo. Guidelines on robotic and single-site surgery. 2013 [Available from: www.uroweb.org
6. Gynaecology DAfOa. Guidelines for minimal invasive surgery / laparoscopy [Richtlijn minimaal invasieve chirurgie / laparoscopie]. 2011 [Available from: http://nvog-documenten.nl/index.php?pagina=/richtlijn/item/pagina.php&richtlijn_id=921.
7. techniques EAFESaoi. European association of endoscopic surgeons (EAES) consensus statement on the use of robotics in general surgery. Surg Endosc. 2014.
8. Association DH. Covenant for safe application of medical technologies in the hospital. 2011.
9. Ahmad G OFH, Duffy JMN, Philips K, Watson A. . Laparoscopic entry techniques. Cochrane Database of Systematic Reviews. 2012.
10. Pemberton RJT, D.A., Velthoven R.F. van. Prevention and Management of Complications in Urological Laparoscopic Port Site Placement. Eur Urol. 2006;50:958-68.
11. Spruce L BM. Implementing AORN recommended practices for electrosurgery. AORN J. 2012;95:373-84.
12. Brown SL WE. Surgical stapler-associated fatalities and adverse events reported to the Food and Drug Administration. J Am Coll Surg 2004;199:374-81.
13. Feldman L FP, Jones DB. The SAGES Manual on the Fundamental Use of Surgical Energy (FUSE).2012.
14. Bandi G WC, Wilkinson EA, Hedican SP, Moon TD, Nakada SY. . Comparison of blade temperature dynamics after activation of Harmonic Ace scalpel and the Ultracision Harmonic Scalpel LCS-K5. J Endourol 2008;22:333-6.
15. Voyles CR TR. Safe Use of Electrosurgical Devices During Minimally Invasive Surgery; excerpt from new textbook pre-vention and management of laparoendoscopic complications, 2nd edition 2015 [Available from: http://www.laparoscopytoday.com/2005/01/safe_use_of_ele.html.
16. Srivastava A NA. Secrets of safe laparoscopic surgery: Anaesthetic and surgical considerations. Minim Access Surg 2010;6:91-4.
17. Szomstein S LME, Simpfendorfer C, Zundel N, Rosenthal RJ. Laparoscopic lysis of adhesions. . World J Surg 2006;30:535-40.
18. Pearl J PR, Richardson W, Fanelli R for the Society of American Gastrointestinal Endoscopic Surgery. Guidelines for diagnosis, treatment, and use of laparoscopy for surgical problems during pregnancy. Surg Endosc 2011;25:3479-92.
19. Collins S LD, McDougall EM, Clayman RV, Landman J. AUA- BLUS. Handbook of Laparoscopic and Robotic Fundamentals2015.
20. Midley S TD. Anaesthesia for Laparoscopic Surgery in Urology. EAU-EBU update series 2006;4:241-5.
21. Mortazavi MM RA, Deep A, Griessenauer CJ, Shoja MAM, , Tubbs RS FW. Hypertonic saline for treating raised intracranial pressure: literature review with meta-analysis. J Neurosurg. 2012;116(210-221).
22. Rosenblatt A BR, Cohen BE. . Manual of Laparoscopic Urology. 2008.
23. Miller K1 BM, Pickens A, Shipp E, Zheng Q. Ergonomics principles associated with laparoscopic surgeon injury/illness. Hum Factors 2012;54:1087-92.
24. Mirbod S YH, Miyamoto K, Miyashita K, Inaba R, Iwata H. . Subjective complaints in orthopedists and general surgeons. Int Arch Occup Environ Health 1995;67:179-86.
25. Mitre AI DR, Arap MA, Coelho RF, Lopes RI, Trigo-Rocha F, et al. . Ergonomic aspects related to surgeon position in laparoscopic radical prostatectomy. J Endourol 2009;23:259-62.
26. Bendix T KL, Jessen F, Aaras A. . Trunk posture and trapezius muscle load while working in standing, supported-standing, and sitting positions. Spine. 1985;10:433-9.
27. Heidenreich A, et al. EAU guidelines on prostate cancer. part 1: screening, diagnosis, and local treatment with curative intent-update 2013. . Eur Urol. 2014;65(1):124-37.
28. Ljungberg B BK, Canfield S, Dabestani S, Hofmann F, Hora M, et al. . EAU Guidelines on Renal Cell Carcinoma: 2014 Update. . Eur Urol. 2015;67:913-24.
29. Merseburger AS HT, Shariat SF, et al. . EAU guidelines on robotic and single-site surgery in urology. . Eur Urol. 2013;64:277-91.
30. Mitropoulos D AW, Graefen M, Remzi M, Roupret M, Truss M, et al. Reporting and grading of complications after urological surgical procedures: An ad hoc EAU guidelines panel assessment and recommendations. . Eur Urol. 2012;61:341-9.

31. Novick AC CS, Beldegrun A, Blute ML, Chow GK, Derweesh IH. Guideline for Management of the Clinical stage 1 Renal Mass. American Urological Association 2010 Ref type: Online Source 2010.
32. Rouprêt MB, A. Böhle, M. Burger, E. Compérat, N. Cowan, E, et al. EAU Guidelines on Urothelial Carcinomas of the Upper Urinary Tract. 2016.
33. Guideline prostate carcinoma [Richtlijn prostaatacarcinoom]. [press release]. 2016.
34. Urology EAo. EAU Guidelines on Pediatric Urology. 2013.
35. Urology. DAo. Dutch guideline on bladder cancer [Urotheelcarcinoom van de blaas]. 2009.
36. Witjes JA CE, Cowan NC, et al. . EAU guidelines on muscle-invasive and metastatic bladder cancer: summary of the 2013 guidelines. . Eur Urol 2014;65:778-92.
37. Turchetti G PI, Pierotti F, Cuschieri A. Economic evaluation of da Vinci-assisted robotic surgery: a systematic review. Surg Endosc. 2012;26(3):598-606.
38. Liberman D TQ, Jeldres C, Zorn KC. Is robotic surgery cost-effective: yes. Curr Opin Urol. 2012;22(1):61-5.
39. Ramsay C PR, Soomro N et al. Systematic review and economic modelling of the relative clinical benefit and cost-effectiveness of laparoscopic surgery and robotic surgery for removal of the prostate in men with localised prostate cancer. Health Tech Ass. 2012;16:1-313.
40. Buse S HC, Klumpen P et al. Cost-effectiveness of robot-assisted partial nephrectomy for the prevention of perioperative complications. . World J Urol. 2015.
41. Wijnburg C. Editorial: Cost-effectiveness of robotic surgery; what do we know? Brit J Urol Int. 2016;117(6):852-3.
42. HuJC GG, Karakiewicz PI et al. Comparative effectiveness of robot-assisted versus open radical prostatectomy. Eur Urol. 2014;66:666-72.
43. Poulin P AL, Scott CM, Poulin M, Gall N, Seidel J, et al. Introduction of new technologies and decision making processes: a framework to adapt a Local Health Technology Decision Support Program for other local settings Med Devices 2013;6:185-93.
44. Specialists. KloM. Guideline for new interventions in clinical practice [Leidraad nieuwe interventies in de klinische praktijk]. 2014.
45. Sciences RNAoAa. Evaluation of new technology in health care. In need of guidance for relevant evidence. . 2014.
46. Inspectorate DHC. Assessment framework follow-up minimal invasive surgery. 2nd phase. Sept. 2009 [Toetsingskader follow-up minimaal invasieve chirurgie ten behoeve van het tweede-faseonderzoek vanaf september 2009]. . IGZ, Den Haag. 2009.
47. Siemerink K VL BCdWC. Zorgen voor veilige toepassing van Medische Technologie: verkennende interviews in vijf Nederlandse ziekenhuizen. Utrecht/Amsterdam, EMGO+/NIVEL. 2013.
48. Wagner C ZM, Bruijne MC de. Patiëntveiligheid: onbedoelde en potentieel vermijdbare schade bij snijdende specialismen. Ned Tijdschr Geneesk 2009;153:327-33.
49. Zegers M BMD, Wagner C, Hoonhout LH, Waaijman R, Smits M, et al. Adverse events and potentially preventable deaths in Dutch hospitals: results of a retrospective patient record review study. Qual Saf Health Care 2009;18:297-302.
50. Zegers M BMD, de Keizer B, Merten H, Groenewegen PP, van der Wal G, et al. The incidence, root-causes, and outcomes of adverse events in surgical units: implication for potential prevention strategies. . Saf Surg 2011;5:13.
51. C. W. Unintended harm in hospitals: results chart review patient safety [Onbedoelde schade in ziekenhuizen: resultaten dossieronderzoek naar patiëntveiligheid]. Klachtenmanagement in de Zorg. 2007.
52. Schoten SM van KV, Blok C de, Spreeuwenberg P, Groenewegen PP, Wagner C. Compliance with a time-out procedure intended to prevent wrong surgery in hospitals: results of a national patient safety programme in the Netherlands. BMJ Open. 2014;4.
53. Kohn KT CJ, Donaldson MS, editors. To err is human: building a safer health system. Washington DC: Committee on Quality of Health Care in America. . Institute of Medicine, National Academy Press. 1999.
54. Langelaan M BMD, Baines RJ, Broekens MA, Hammink K, Schilp J, et al. Monitor Zorggerelateerde schade 2011/2012: dossieronderzoek in Nederlandse ziekenhuizen. Utrecht/Amsterdam, EMGO+/NIVEL. 2013.
55. A. G. The checklist manifesto: how to get things right. . New York, US: Metropolitan Books of Henry Holt and Co. 2011.
56. Russ S RS, Sevdalis N, Moorthy K, Darzi A, Vincent C. . Do safety checklists improve teamwork and communication in the operating room? A systematic review. Ann Surg 2013;258:856-71.
57. Inspectorate. DHC. Safety criteria in hospitals. Quality indicators Dutch hospitals [Veiligheidsnormen ziekenhuizen. Basisset kwaliteitsindicatoren ziekenhuizen IGZ]. 2014.
58. Organization. WH. Surgical Safety Checklist 2009 [Available from: <http://www.who.int/patientsafety/safesurgery/checklist/en/>].

59. Blok C de KE, Schilp J, Wagner C. Implementation Safety Program in hospitals [Implementatie VMS Veiligheidsprogramma]. Utrecht/Amsterdam: EMGO+/NIVEL; 2013.
60. Anesthesiology. DAo. Guideline the perioperative process [Richtlijn het perioperatieve proces]. 2011.
61. Haynes AB WT, Berry WR, Lipsitz SR, Breizat AH, Dellinger EP, et al. . A surgical safety checklist to reduce morbidity and mortality in a global population. . *New Engl J Med*. 2009;360:491-9.
62. Cundy TP HL, Hughes-Hallett A, Mayer EK, Najmaldin AS, Athanasiou T, et al. Meta-analysis of robot-assisted vs conventional laparoscopic and open pyeloplasty in children. *BJU Int*. 2014;114:582-94.
63. Mayer EK SN, Rout S, Caris J, Russ S, Mansell J, et al. Surgical Checklist Implementation Project: The Impact of Variable WHO Checklist Compliance on Risk-adjusted Clinical Outcomes After National Implementation: A Longitudinal Study. . *Ann Surg*. 2015;[Epub ahead of print].
64. Patel J AK, Guru KA, Khan F, Marsh H, Shamim Khan M, et al. . An overview of the use and implementation of checklists in surgical specialities - a systematic review. . *Int J Surg* 2014;12:1317-23.
65. Treadwell JR LS, Tsou AY. Surgical checklists: a systematic review of impacts and implementation. . *BMJ Qual Saf*. 2014;23:299-318.
66. Vries EN de PH, Crolla RM, Outer AJ den, Anel G van, Helden SH van, et al. Effect of a comprehensive surgical safety system on patient outcomes. . *New Engl J Med* 2010;363:1928-37.
67. Noordmans HJ BMD, Wientjes R, Martens E, Lindenhovius K, Swart P. . Evaluation of the ScopeControl endoscope test system in six hospitals in The Netherlands. . *Phys Med* 2015;31:152-8.
68. Science RNAoAa. 2016 [Available from: <http://www.knmg.nl/Dossiers-9/Dossiers-thematrefwoord/Patientenrechten/Informed-consent-3.htm>].
69. Witmer JM dRR. Implementation of the Dutch Medical Treatment Agreement Act. [Implementatie van de WGBO]. 2004.
70. Zwaan L WC. Menselijke factoren en patiëntveiligheid. . Medisch teamwork, CRM in de gezondheidszorg Houten: Bohn Stafleu van Loghum, . 2013.
71. Dindo D DN, Clavien P. . Classification of surgical complications: a new proposal with evaluation of a cohort of 6336 patients and results of a survey. *Ann Surg*. 2004;40:205-13.
72. Bosma E VE, Jongh MA de, Roukema JA. Variable impact of complications in general surgery: a prospective cohort study. . *Can J Surg* 2012;55:163-70.
73. Coello R CA, Wilson J, Ward V, Pearson A, Borriello P. Adverse impact of surgical site infections in English hospitals. *J Hosp Infect* 2005;60:93-103.
74. Collins TC DJ, Henderson WH, Khuri SF. Risk factors for prolonged length of stay after major elective surgery. . *Ann Surg* 1999;230:251-9.
75. Khuri SF HW, DePalma RG, Mosca C, Healey NA, Kumbhani DJ. . Determinants of long-term survival after major surgery and the adverse effect of postoperative complications. *Ann Surg* 2005;243:326-41.
76. Roukema JA WCvd, Leenen LP. Registration of postoperative complications to improve the results of surgery. *Ned Tijdschr Geneesk* 1996;140:781-4.
77. Zhan C MM. Excess length of stay, charges, and mortality attributable to medical injuries during hospitalization. . *J Am Med Assoc*. 2003;290:1868-74.
78. Bruce J RE, Mollison J, Krukowski ZH. Bruce J, Russell EM, Mollison J, Krukowski ZH. The measurement and monitoring of surgical adverse events. *Health Tech Ass*. 2001;5:1-194.
79. Rowell KS TF, Hutter MM, Khuri SF, Henderson WG. Use of national surgical quality improvement program data as a catalyst for quality improvement. . *J Am Coll Surg* 2007;204:1293-300.
80. Sokol DK WJ. What is a surgical complication? *World J Surg* 2008;32:942-4.
81. J. M. Defining and classifying clinical indicators for quality improvement. *Int J Qual Health Care*. 2003;15:523-30.
82. Samenwerking SSO. Multidisciplinaire Normering Oncologische Zorg In Nederland. Normeringsrapport 3. 2015.
83. Furriel FT LM, Figueiredo AJ, Nunes PT, Rassweller JJ. Training of European urology residents in laparoscopy: results of a pan-European survey. *Br J Urol Int*. 2013;112:1223-8.
84. Brinkman WM TI, Schout BM, Muijtjens AM, Cleynenbreugel B van, Koldewijn EL, et al. . Results of the European Basic Laparoscopic Urological Skills examination. *Eur Urol* 2014;65:490-6.
85. Dankelman J CM, Verdaasdonk EG, Stassen LP, Grimbergen CA. Fundamental aspects of learning minimally invasive surgical skills. *Minim Invasive Ther Allied Technol* 2005;14:247-56.
86. Klein J TD, Frede T, Stock C, Hruza M, Gözen A, et al. Development, validation and operating room-transfer of a six-step laparoscopic training program for the vesicourethral anastomosis. *J Endourol* 2013;27:349-54.
87. Matsuda T ME, Ono Y, Hattori R, Baba S, Iwamura M, et al. Positive correlation between motion analysis data on the LapMentor virtual reality laparoscopic surgical simulator and the results from videotape assessment of real laparoscopic surgeries. *J Endourol*. 2012;26:1506-11.

88. Da Cruz JA SN, Passerotti CC, Nguyen H, Antunes AA, Dos Reis ST, et al. Does training laparoscopic skills in a virtual reality simulator improve surgical performance? *J Endourol* 2010;24:1845-9.
89. Lee YL KG, Phelps JY. . Medicolegal review of liability risks for gynecologists stemming from lack of training in robot-assisted surgery. . *J Minim Invasive Gynecol* 2011;18:512-5(b).
90. Lee YL KG, Phelps JY. Liability exposure for surgical robotics instructors. *J Minim Invasive Gynecol* 2012;19:376-9.
91. Zorn KC GG, Shalhav AL, Clayman RV, Ahlering TE, Albala DM, et al. Training, credentialing and medicolegal risks of robotic urological surgery: recommendations of the society of urologic robotic surgeons. *J Urol* 2009;182:1126-32.
92. Lee JY MP, Sundaram CP, McDougall EM. Best practices for robotic surgery training and credentialing. *J Urol*. 2011;185:1191-7(a).
93. Tjiam I PM, Hendriks A, Muijtjens A, Witjes J, Scherpbier A. Program for Laparoscopic Urological Skills: A newly developed and validated educational program. *Urology* 2012;79(4):815-20.
94. Tjiam I SB, Hendriks A, Muijtjens A, Scherpbier A, Witjes J, van der Vleuten C. Program for laparoscopic urological skills assessment: Setting certification standards for residents. *Min Inv Ther*. 2013;22(1):26-32.
95. Section. EAoU-RU. 2014 [Available from: <http://uroweb.org/section/erus/information/>].
96. Sood A JW, Ahlawat R, Campbell L, Aggarwal S, Menon M, et al. . Robotic surgical skill acquisition: What one needs to know? . *J Minim Access Surg* 2015;11:10-5.
97. EM. M. Validation of surgical simulators. *J Endourol* 2007;21:244-7.
98. Gamboa AJ SR, Sargent ER, Louie MK, Box GN, Sohn KH, et al. . Long-term impact of a robot assisted laparoscopic prostatectomy mini fellowship training program on postgraduate urological practice patterns. *J Urol*. 2009;181:778-82.
99. Hay D KM, Poppel H van, Cleynenbreugel B van, Peabody J, Guru K, et al. Current Status and Effectiveness of Mentorship Programmes in Urology: A Systematic Review. . *Br J Urol Int*. 2015;116:487-94.
100. Patel SR HS, Bishoff JT, Shichman SJ, Link RE, Wolf JS, Jr, et al. Skill based mentored laparoscopy course participation leads to laparoscopic practice expansion and assists in transition to robotic surgery. *J Urol* 2011;186:1997-2000.
101. Aboumarzouk OM SR, Eyraud R, Haber GP, Chlosta PL, Somani BK, et al. . Robotic versus laparoscopic partial nephrectomy: a systematic review and meta-analysis. . *Eur Urol*. 2012;62:1023-33.
102. Bi L ZC, Li K, Fan X, Xu K, Han J, et al. Robotic partial nephrectomy for renal tumors larger than 4 cm: a systematic review and meta-analysis. . *PLoS One*. 2013;8:e75050.
103. Marszalek M MH, Polajnar M, Rauchenwald M, Jeschke K, et al. . Laparoscopic and open partial nephrectomy: a matched- pair comparison of 200 Patients. *Eur Urol*. 2009;55:1171-8.
104. Tumoren. LWU. Richtlijn Niercelcarcinoom.; 2010.
105. Leibovitch I RG, Mor Y, Nativ O, Goldwasser B. . Reconsidering the necessity of ipsilateral adrenalectomy during radical nephrectomy for renal cell carcinoma. . *Urology*. 1995;46:316-20.
106. Blom JH PHv, Marechal JM, Jacqmin D, Schroder FH, Prijck L de, et al. . Radical nephrectomy with and without lymph-node dissection: final results of European Organization for Research and Treatment of Cancer (EORTC) randomized phase 3 trial 30881. . *Eur Urol*. 2009;55:28-34.
107. Kok NF LM, Hansson BM, Pilzecker D, Mertens zur Borg IR, Knipscheer BC, et al. Comparison of laparoscopic and mini incision open donor nephrectomy: single blind, randomised controlled clinical trial. *Brit Med J*. 2006;333:221.
108. Atwell TD CR, Schmit GD et al. Complications following 573 percutaneous renal Radiofrequency and Cryoablation procedures. . *J Vasc Interv Radiol*. 2012;23:48-54.
109. Long CJ KA, Canter DJ et al. . Percutaneous vs surgical cryoablation of the small renal mass: is efficacy compromised?. *BJUI*. 2010;107:1376-80.
110. D T. Cancer cryotherapy: Evolution and biology. . *Rev Urol*. 2004;6(Suppl4):S9-S19.
111. Clarke DM RA, Rhee E et al. Cryoablation of renal cancer: variables involved in freezing-induced cell death. . *Technol Cancer Res Treat*. 2007;6:69-79.
112. Buy X LH, Garnon J, Sauleau E, Roy C, Gangi A. . Percutaneous renal cryoablation: prospective experience treating 120 consecutive tumors. *AJR Am J Roentgenol*. 2013;201:1353-61.
113. Cordeiro ER BK, Anastasiadis A et al. Laparoscopic cryotherapy for sm all renal masses: current state. . *Arch Esp Urol*. 2013;66:41-53.
114. Georgiades CS RR. Efficacy and Safety of Percutaneous Cryoablation for Stage 1A/B Renal Cell Carcinoma: Results of a Prospective, Single-Arm, 5-Year Study. . *Cardiovasc Intervent Radiol*. 2014;37:1494-9.
115. Canes D DM, Haber GP, Colombo JR, Turna B, Kaouk JH, et al. Is routine transposition of anterior crossing vessels during laparoscopic dismembered pyeloplasty necessary? . *J Endourol* 2009;23(469-73).

116. O'Reilly PH BP, Mak S, Jones M, Pickup C, Atkinson C, et al. . The long term results of Anderson-Hynes pyeloplasty. *BJU Int* 2001;87:287-9.
117. Rassweiler JJ TD, Frede T. Complications of laparoscopic pyeloplasty. *World J Urol.* 2008;26:539-47.
118. Chamma MF MA, Hubert N, Egrot C, Hyber J, Wolf JS. . Laparoscopic transperitoneal pyeloplasty. . *J Endourol* 2011;25:173-8.
119. Sooriakumarn P JM, Wiklund P, Lee D, Nilsson A, Tewari AK. . Learning curve for robotic assisted laparoscopic prostatectomy: a multi-institutional study of 3794 patients. . *Minerva Urol Nefrol.* 2011;63:191-8.
120. Stolzenburg JU QH, Holze S, Mende M, Nicolaus M, Franz T, et al. . Evaluating the learning curve of experienced laparoscopic surgeons in robot-assisted radical prostatectomy. *J Endourol.* 2013;27:80-5.
121. Samenwerking SO. Multidisciplinary criteria oncological care in the Netherlands [Multidisciplinaire normering oncologische zorg in Nederland. SONCOS normeringsrapport 4]. 2016.
122. Urology EAo. Guidelines on prostate cancer. 2016.
123. Montorsi F WT, Rosen RC, Ahlering TE, Artibani W, Carroll PR, et al. . Best Practices in Robot-assisted Radical Prostatectomy: Recommendations of the Pasadena Consensus Panel. . *Eur Urol.* 2012;62:368-81.
124. Martin GL NR, Humphreys MD, Martin AD, Ferrigni RG, Andrews PE, et al. . Interval from prostate biopsy to robot-assisted radical prostatectomy: effects on perioperative outcomes. . *BJU Int.* 2009;104:1734-7.
125. Albertsen PC FD, STorer BE, Kolon TF, Fine J. . The impact of co-morbidity on life expectancy among men with localized prostate cancer. . *J Urol.* 1996;156:127-32.
126. Shveiky D1 AJ, Iglesia CB. . Brachial plexus injury after laparoscopic and robotic surgery. . *J Minim Invasive Gynecol.* 2010;17:414-20.
127. Binder J KW. Robotically-assisted laparoscopic radical prostatectomy. . *BJU Int.* 2001;87:408-10.
128. Menon M SA, Tewari, Sarle R, Hemal A, Peadbody JO, et al. . Laparoscopic and robot assisted radical prostatectomy: establishment of a structured program and preliminary analysis of outcome. . *J Urol.* 2002;168:945-9.
129. Patel VR SK, Thaly RK, et al. Robotic-assisted laparoscopic radical prostatectomy: The Ohio State University technique. . *J Robotic Surg* 2006;1:51-9.
130. Van Velthoven RF AT, Peltier A, Skarecky DW, Clayman RV. . Technique for laparoscopic running urethrovesical anastomosis: the single knot method. . *Urology.* 2003;61:699-702.
131. Schramm P TA, Berres M, Pestel G, Engelhard K, Werner C, et al. . Time course of cerebrovascular autoregulation during extreme Trendelenburg position for robotic-assisted prostatic surgery. . *Anaesthesia.* 2014;69:58-63.
132. Callier C T-FP, Bram R, Ballanger P. . Effect of sublingual oxybutynin in postoperative pain after radical retropubic prostatectomy. *Prog Urol.* 2009;19:558-62.
133. Dindo D DN, Clavien P. . Classification of surgical complications: a new proposal with evaluation of a cohort of 6336 patients and results of a survey. . *Ann Surg.* 2004;240:205-13.
134. Bhandari A ML, Kaul SA, Kemal AK, Peabody JO, Menon M. Perioperative complications of robotic radical prostatectomy after the learning curve. . *J Urol.* 2005;174:915-8.
135. Novara G CJ, Wilson T, et al. . Systematic review and cumulative analysis of perioperative outcomes and complications after robot-assisted radical cystectomy. *Eur Urol.* 2015;67:376-401.
136. Sotelo RJ HA, Machuca V, Medina L, Nunez L, Santinelli F, et al. . Safer surgery by learning from complications: a focus on robotic prostate surgery. *Eur Urol.* 2016;69:334-44.
137. Bishoff JT AM, Kirkels W, Moore RG, Kavoussi LR, Schroder F. . Laparoscopic bowel injury: incidence and clinical presentation. . *J Urol.* 1999;161:887-90.
138. Tyrantzis SI KI, Consantinides CA. . All you need to know about urethrovesical anastomotic urinary leakage following radical prostatectomy. *J Urol.* 2012;188:369-76.
139. Zorn KC TQ, Jeldres C, Schmitges J, Widmer H, Lattouf JB, et al. Prospective randomized trial of barbed polyglyconate suture to facilitate vesico-urethral anastomosis during robot-assisted radical prostatectomy: time reduction and cost benefit. . *BJU Int.* 2012;109:1526-32.
140. Barrington JW GE. Posthysterectomy vault prolapse. . *Int J Pelvic Floor dysfun Urogynaecol* 2000;11:241-5.
141. Benson JT LV, McClellan E. . Vaginal versus abdominal reconstructive surgery for the treatment or pel vic support defects: a prospective randomized study with long-term outcome evaluation. *Am J Obstet Gynecol* 1996;175:1418-22.
142. Maher C, Feiner B Decuyper EM, Nichlos CJ, K. Hickey, P. O'Rourke Laparoscopic sacral colpopexy versus total vaginal mesh for vaginal vault prolapse: a randomized trial. *American Journal of Obstetrics and Gynecology* 2011;204:360e1-7.
143. FL L. Repair or posthysterectomy vaginal vault prolapse. . *Obstet & Gynecol* 1962;20:72-7.

144. Anand M WJ, Weaver AL, Trabuco EC, Klingele CJ, JB Gebhart. . Perioperative complications or robotic sacrocolpopexy for post-hysterectomy vaginal vault prolapse. *International urogynecology Journal* 2014;25:1193-200.
145. Freeman RM PK, A Thomson, J Frappell, Bombieri L, Moran P, et al A randomized controlled trial of laparoscopic versus abdominal sacrocolpopexy for the treatment of post-hysterectomy vaginal vault prolapse:. . LAS study *International urogynecology Journal and Pelvic Floor Dysfunction* 2013;24:377-84.
146. Iavazzo C, Papadopoulou EK GI. Cost assessment of robotics in gynecologic surgery: A systematic review. *The Journal of Obstetrics and Gynaecology Research* 2014;40:2125-34.
147. Nezhat CH NF, Nezhat C. Laparoscopic sacral colpopexy for vaginal vault prolapse. *Obstet Gyne- col.* 1994;84:885-8.
148. Anger JT ME, Tarnay C, B Smith, K Stroupe, Rosenman A, et al Robotic Compared with laparoscopic sacrocolpopexy: a randomized controlled trial. . *Obstetrics and Gynecology* 2014;123:5-12.
149. Nosti PA AUU, Kane S, White DE, Harvie HS, Lowenstein L, et al Outcomes of minimally invasive abdominal and sacrocolpopexy:. A retrospective cohort study. *Female Pelvic Med Reconstr Surg* 2014;20:33-7.
150. Paraiso MFR JJ, Frick A, Chen CCG, Barber MD. . Laparoscopic compared with robotic sacrocolpopexy for vaginal prolapse: a randomized controlled trial. *Obstetrics and Gynecology* 2011;118:1005-13.
151. Bedaiwy MA ARM, Deter S, T Farghaly, Shalaby MM Frasure H, et al. . The impact of training residents on the outcome of robotic-assisted sacrocolpopexy. *Minimally Invasive Surgery* 2012:289-342.
152. Claerhout F JV, Werbrouck E, J Veldman, Lewi P Deprest, J. . Analysis of the learning process for laparoscopic sacrocolpopexy scopic: identification of challenging steps. . *International urogynecology Journal* 2014;25:1185-91.
153. Geller EJ LF, Matthews CA. Analysis of robotic performance times to Improve operative efficiency. . *Journal or Minimally Invasive Gynecology* 2012;20:43-8.
154. Zucchi A LM, Porena M, Mearini L, Costantini E. Uterus preservation in pelvic organ prolapse surgery. *Nat Rev Urol* 2010;7:626-33.
155. Bavel J van B, J den, Everhardt E, Kerkhof M, Kluivers K, Milani F, et al. Nota gebruik van kunststof materiaal bij prolaps chirurgie.; 2014.
156. Cundiff GW VE, Visco AG, Zyczynski HM, Nager CW, Norton PA, et al. . Risk factors for mesh/suture erosion following sacral colpopexy. *Am J Obstet Gynecol.* 2008;199(6):688.e1688.e5.
157. Elser DM1 MM, Stanford EJ, Keil K, Matthews CA, Kohli N, Mattox F, Tomezsko J. Abdominal sacrocolpopexy and urinary incontinence: surgical planning based on urodynamics. . *Urogynecology Network Am J Obstet Gynecol.* 2010;202(4):688.e1688.e5.
158. Kummeling MT1 RJ, Withagen MI, Mannaerts GH, van der Weiden RM. . Sequential urodynamic assessment before and after laparoscopic sacrocolpopexy. . *Acta Obstet Gynecol Scand.* 2013;92(2):172-7.
159. Richardson ML1 EC, Shaw JG, Comiter CV, Chen B, Sokol ER. To sling or not to sling at time of abdominal sacrocolpopexy: a cost-effectiveness analysis. . *J Urol.* 2013;190(4):1306-12.
160. LeClaire EL MM, Juarez D, White, D, Quiroz LH. . Is de novo stress incontinence after sacrocolpopexy related to anatomical changes and surgical approach? . *International Urogynecology Journal* 2014;25:1202-6.
161. Gaston R RA. Surgery illustrated: laparoscopic sacrocolpopexy. . *Br J Urol Int.* 2011;107:500-17.
162. Nygaard IE MR, Brubaker L, Connolly A, Cundiff G, Weber AM, Zyczynski H. Abdominal sacrocolpopexy: a comprehensive review. *Obstet Gynecol* 2004;104:805-23.
163. Culligan PJ BL, Goldsmith LJ, Graham CA, Rogers A, Heit MH. A randomized controlled trial comparing fascia lata and synthetic mesh for sacral colpopexy. . *Obstet Gynecol.* 2005;106(1)(29-37).
164. Ginath S GA, Condrea A, Vardy MD. Mesh erosion following abdominal sacral colpopexy in the absence and presence of the cervical stump. *Int Urogynecol J.* 2013;24:113-8.
165. Mourik SL MJ, Aktas M. Uterien preservation in pelvic organ prolapse using robot assisted laparoscopic sacrohysteropexy: quality of life and technique. *Eur J Obstet Gynecol Reprod Biol.* 2012;165(1):122-7.
166. Osmundsen BC CA, Goldsmith C, Adams K, Denman MA, Edwards R, et al. Mesh Erosion in Robotic Sacrocolpopexy. *Female Pelvic Med Reconstr Surg.* 2012;18(2).
167. Haylen BT FR, Swift SE, Cosson M, Davilla GW, Deprest J, et al. An International Urogynecological Association (IUGA) / International Continence Society (ICS) joint terminology and classification of the complications related directly to the insertion of prostheses (meshes, im-plants, tapes) & grafts in female pelvic floor surgery. *Int Urol J.* 2011;22:3-15.
168. Blinman T PT. Pediatric minimally invasive surgery: laparoscopy and thoracoscopy in infants and children. *Pediatrics.* 2012;130(3):539-49.
169. Casale P PR, Kolon TF. Nerve sparing robotic extravesical ureteral reimplantation. *J Urol* 2008;179(5):1987-9.
170. Da Cruz JAS PC. Reconstructive laparoscopy in pediatric urology. *Curr Opin Urol* 2010;20(4):330-5.

171. Kuebler JF UB. Minimally invasive surgery in the neonate. *Semin Fetal Neonatal Med* 2011;16(3):151-6.
172. Parelkar S V OS, Bachani MK, Sanghvi B V, Gupta R, Prakash A, et al. . Minimal access surgery in newborns and small infants; five years experience. *Minim Access Surg* 2013;9(1):19-24.
173. Dingemann J UB. Systematic review of level 1 evidence for laparoscopic pediatric surgery: do our procedures comply with the requirements of evidence-based medicine? . *Eur J Pediatr Surg* 2013;23(6):474-9.
174. Lacher M KJ, Dingemann J, Ure BM. Minimal invasive surgery in the newborn: current status and evidence. *Semin Pediatr Surg* 2014;23(5):249-56.
175. Sukumar S DO, Sood A, Sammon JD, Varda B, Janosek-Albright K, et al. Minimally invasive vs open pyeloplasty in children: the differential effect of procedure volume on operative outcomes. *Urology*. 2014;84(1):180-4.
176. Passerotti CC FF, Bissoli JCC, Tiseo B, Oliveira CM, Buchalla CAO, et al. Comparison of the learning curves and frustration level in performing laparoscopic and robotic training skills by experts and novices. *Int Urol Nephrol* 2015;47(7):1075-84.
177. TA. B. MIS-behavior: practical heuristics for precise pediatric minimally invasive surgery. *Urol Clin North Am*. 2015;42(1):131-40.
178. Manner T AR, Alanen M. Lung compliance during laparoscopic surgery in paediatric patients. *Paediatr Anaesth*. 1998;8(1):25-9.
179. McHoney M CL, Eaton S, Kiely EM, Drake DP, Tan HL, et al. Carbon dioxide elimination during laparoscopy in children is age dependent. *J Pediatr Surg*. 2003;38(1):105-10.
180. Janetschek G SJ, Radmayr C, Bartsch G. Laparoscopic heminephroureterectomy in pediatric patients. . *J Urol*. 1997;158(5):1928-30.
181. Sümpelmann R ST, Marx G, Härtel D, Hecker H, Ure BM, et al. . Haemodynamic, acid-base and blood volume changes during prolonged low pressure pneumoperitoneum in rabbits. . *Br J Anaesth*. 2006;96(5):563-8.
182. Sümpelmann R ST, Marx G, Jesch NK, Osthaus WA, Ure BM. . Hemodynamic changes during acute elevation of intra-abdominal pressure in rabbits. *Paediatr Anaesth*. 2006;16(12):1262-7.
183. Turner RM FJ, Ost MC. . Advances in the surgical pediatric urologic armamentarium. *Pediatr Clin North Am* 2012;59(4):927-41.
184. Bowlin PR FW. Laparoscopic nephrectomy and partial nephrectomy: intraperitoneal, retroperitoneal, single site. *Urol Clin North Am* 2015;42(1):31-42.
185. Dingemann J KJ, Ure BM. . Laparoscopic and computer-assisted surgery in children. *Scand J Surg* 2011;100(4):236-42.
186. Tomaszewski JJ CD, Turner RM, Casale P, Ost MC. . Pediatric laparoscopic and robot-assisted laparoscopic surgery: technical considerations. . *J Endourol* 2012;26(6):602-13.
187. Gupta R SS. Challenges in paediatric laparoscopic surgeries. *Indian J Anaesth*. 2009;53(5):560-6.
188. PC G. Robotic-assisted bladder neck repair: feasibility and outcomes. . *Urol Clin North Am*. 2015;42(1):111-20.
189. Valla JS GB, Montupet P, Geiss S, Steyaert H, el Ghoneimi A, et al. . Retroperitoneal laparoscopic nephrectomy in children. Preliminary report of 18 cases. *Eur Urol* 1996;30(4):490-3.
190. Blanc T MC, Pons M, Pashootan P, Paye-Jaouen A, El Ghoneimi A. . Laparoscopic Mitrofanoff procedure in children: critical analysis of difficulties and benefits. . *J Pediatr Urol* 2015;11(1):28e.1-8.
191. Chrzan R KA, Dik P, de Jong TPVM. U2B-dry: preliminary results of a new vesicoscopic technique for bladder neck repair in children. . *J Laparoendosc Adv Surg Tech A* 2010;20(3):295-9.
192. Chrzan R KA, Kuijper CF, Dik P, de Jong TPVM. Laparoscopic burch colposuspension in children: technical challenges and primary results. *J Laparoendosc Adv Surg Tech A*. 2014;24(7):513-7.
193. Cilento BG DD, Yeung CK, Manzoni G, Poppas DP, Hensle TW. . Laparoscopically assisted ureterocystoplasty. *BJU Int* 2003;91(6):525-7.
194. Gundeti MS AS, Zagaja GP, Shalhav AL. . Paediatric robotic-assisted laparoscopic augmentation ileocystoplasty and Mitrofanoff appendicovesicostomy (RALIMA): feasibility of and initial experience with the University of Chicago technique. . *BJU Int* 2011;107(6):962-9.
195. Peters CA SR, Retik AB. Pediatric Laparoscopic Dismembered Pyeloplasty. *J Urol*. 1995;153(6):1962-5.
196. Tugcu V IY, Polat H, Tasci AI. Early experience with laparoendoscopic single-site pyeloplasty in children. *J Pediatr Urol* 2011;7 (2):187-91.
197. Varlet F PT, Leclair M-D, Lardy H, Geiss S, Becmeur F, et al. . Laparoscopic treatment of renal cancer in children: a multicentric study and review of oncologic and surgical complications. *J Pediatr Urol*. 2014;10(3):500-5.
198. Warmann SW GJ, van Tinteren H, Heij H, Powis M, Sandstedt B, et al. Minimally invasive nephrectomy for Wilms tumors in children - data from SIOP *J Pediatr Surg* 2014;49(11):1544-8.
199. Yeung CK SJ, Borzi PA. . Endoscopic cross-trigonal ureteral reimplantation under carbon dioxide bladder insufflation: a novel technique. *J Endourol* 2005;19(3):295-9.

200. Yeung CK TY, Sihoe JD, Lee KH, Liu KW. . Retroperitoneoscopic dismembered pyeloplasty for pelvi-ureteric junction obstruction in infants and children. . *BJU Int* 2001;87(6):509-13.
201. Esposito C EM, Saxena A, Montupet P, Chiarenza F, De Agustin J, et al. . European Society of Pediatric Endoscopic Surgeons (ESPEs) guidelines for training program in pediatric minimally invasive surgery. *Pediatr Surg Int*. 2015;31(4):367-73.
202. Canon SJ JV, Lowe GJ. Which is better--retroperitoneoscopic or laparoscopic dismembered pyeloplasty in children? . *J Urol* 2007;178(4 pt 2):1791-5.
203. El-Ghoneimi A FW, Bolduc S, Bagli D, McLorie G, Aigrain Y, et al. . Laparoscopic dismembered pyeloplasty by a retroperitoneal approach in children. . *BJU Int*. 2003;92(1):104-8.
204. Yucel S SM, Nguyen MT, Baker LA. Usefulness of short-term retrievable ureteral stent in pediatric laparoscopic pyeloplasty. *J Urol*. 2007;177(2):720-5.
205. Ooi J LN, Murphy DL. Training model for open or laparoscopic pyeloplasty. *J Endourol*. 2006;20(2):149-52.
206. Chang S-J HC-K, Hsieh C-H, Yang SS-D. Comparing the efficacy and safety between robotic-assisted versus open pyeloplasty in children: a systemic review and meta-analysis. *World J Urol*. 2015.
207. Smith RP OJ, Peters CA. Pediatric robotic extravesical ureteral reimplantation: comparison with open surgery. *J Urol* 2011;185(5):1876-81.
208. Olsen LH RY, Jorgensen TM. Pediatric robot assisted retroperitoneoscopic pyeloplasty: a 5-year experience. *J Urol* 2007;178(5):2137-41.
209. Tasian GE CP. The robotic-assisted laparoscopic pyeloplasty: gateway to advanced reconstruction. . *Urol Clin North Am*. 2015;42(1):89-97.
210. Jeugdgezondheidszorg NC. Dutch Guideline for Nonpalpable Testis [Richtlijn signalering van en verwijzing bij niet scrotale testis]. 2012.
211. Cookson MS CS, Wells N et al. . Complications of radical cystectomy for nonmuscle invasive disease: comparison with muscle invasive disease. *J Urol*. 2003;169(1):101.
212. Konety BR AVaHH. Complications after radical cystectomy: analysis of population-based data. . *Urology*. 2006;68(1):58.
213. Musch M JM, Steves A, Roggenbuck U, Boergers A, Davoudi Y, Loewen H, Groeben H, Kroepfl D. . Comparison of early postoperative morbidity after robot-assisted and open radical cystectomy: results of a prospective observational study. . *BJU Int*. 2014;113(3):458-67.
214. Shabsigh A KR, Vora KC et al. Defining early morbidity of radical cystectomy for patients with bladder cancer using a standardized reporting methodology. *Eur Urol*. 2009;55(1):164.
215. Khan MS EO, Challacombe B, et al. . Long-term outcomes of robot-assisted radical cystectomy for bladder cancer. *Eur Urol*. 2013;64:219-24.
216. Raza SJ A-DA, Zhuo S, et al. Oncologic outcomes following robot-assisted radical cystectomy with minimum 5-year followup: the Roswell Park Cancer Institute experience. . *Eur Urol*. 2014;66:920-8.
217. Yuh B TR, Ruel NH, et al. Intermediate-term oncologic outcomes of robot-assisted radical cystectomy for urothelial carcinoma. . *J Endourol*. 2014;28:939-45.
218. Yuh B WT, Bochner B, et al. . Systematic review and cumulative analysis of oncologic and functional outcomes after robot-assisted radical cystectomy. *Eur Urol*. 2015;67:402-22.
219. Gill IS FA, Klein EA, et al. . Laparoscopic radical cystoprostatectomy with ileal conduit performed completely intracorporeally: the initial 2 cases. . *Urology*. 2000;56:26-9.
220. Gill IS KJ, Meraney A M. . Laparoscopic radical cystectomy and continent orthotopic ileal neobladder performed completely intracorporeally: the initial experience. *J Urol* 2002;186:13-8.
221. Parra RO AC, Jones JP, et al. . Laparoscopic cystectomy: initial report on a new treatment for the retained bladder. *J Urol* 1992;148:1140-4.
222. Puppo P PM, Ricciotti G, et al. Laparoscopically assisted transvaginal radical cystectomy. *Eur Urol*. 1995;27:80-4.
223. Sanchez de Badajoz E GPJ, Reche Rosado A, Gutierrez de la Cruz JM, Jimenez Garrido A. . Radical cystectomy and laparoscopic ileal conduit. *Arch Esp Urol* 1993;46:621-4.
224. Abboudi H1 KM, Guru KA, Froghi S, de Win G, Van Poppel H, Dasgupta P, Ahmed K. . Learning curves for urological procedures: a systematic review. *BJU Int*. 2014;114(4):617-29.
225. Hayn MH1 HN, Seixas-Mikelus SA, Mansour AM, Stegemann A, Hussain A, Guru KA. . Is patient outcome compromised during the initial experience with robot-assisted radical cystectomy? Results of 164 consecutive cases. . *BJU Int*. 2010;108(6 (doi: 10.1111/j.1464-410X.2010.09904.x. Epub 2010 Dec 16.)):882-7.
226. Matthew H. Hayna AH, Ahmed M. Mansoura, Paul E. Andrews et al. . The Learning Curve of Robot-Assisted Radical Cystectomy: Results from the International Robotic Cystectomy Consortium. *European Urology*. 2010;58(1):197-202.

227. NP. W. Technology Insight: surgical robots--expensive toys or the future of urologic surgery? . *Nat Clin Pract Urol* 2004;1:79-102.
228. Urology EAo. Muscle-invasive and Metastatic Bladder Cancer. 2015.
229. Burger M WJ, Babjuk M, et al. . Second international consultation on bladder cancer. . In Soloway M, Khoury S eds, *Bladder Cancer*, . 2012:249-68.
230. Bochner BH DG, Sjoberg DD, et al. Comparing open radical cystectomy to robot-assisted laparoscopic radical cystectomy: a randomized clinical trial. . *Eur Urol*. 2014;67(6):1042-50.
231. Nazmy M YB, Kawachi M, et al. . Early and late complications of robot-assisted radical cystectomy: a standardized analysis by urinary diversion type. . *J Urol*. 2014;191:681-7.
232. Ahmed K KS, Hayn MH, et al. . Analysis of intracorporeal compared with extracorporeal urinary diversion after robot-assisted radical cystectomy: results from the International Robotic Cystectomy Consortium. *Eur Urol*. 2014;65:340-7.
233. Sadeghi R TK, Bazaz SM, Kakhki VR, Massoom AF, Gholami H, et al. . Sentinel node mapping in the prostate cancer. Meta-analysis. . *Nuklearmedizin Nucl Med* 2011;50:107-15.
234. Leeuwen AC van BT, Bendle G, Vermeeren L, Valdes Olmos R, Poel HG van der, et al. Tracer-cocktail injections for combined pre- and intraoperative multimodal imaging of lymph nodes in a spontaneous mouse prostate tumor model. . *J Biomed Opt*. 2011;16:016004.
235. Jeschke S LL, Myatt A, Hruby S, Pirich C, Janetschek G. Visualisation of the lymph node pathway in real time by laparoscopic radioisotope- and fluorescence-guided sentinel lymph node dissection in prostate cancer staging. . *Urology* 2012;80:1080-6.
236. Poel HG van der BT, Brouwer OR, Valdes Olmos RA, Leeuwen FW van. . Intraoperative laparoscopic fluorescence guidance to the sentinel lymph node in prostate cancer patients: clinical proof of concept of an integrated functional imaging approach using a multimodal tracer. . *Eur Urol*. 2011;60:826-33.
237. van der Poel HG, Buckle T, Brouwer OR, Valdes Olmos RA, van Leeuwen FW. Intraoperative laparoscopic fluorescence guidance to the sentinel lymph node in prostate cancer patients: clinical proof of concept of an integrated functional imaging approach using a multimodal tracer. *Eur Urol*. 2011;60(4):826-33.
238. Heidenreich A, Bastian PJ, Bellmunt J, Bolla M, Joniau S, van der Kwast T, et al. EAU guidelines on prostate cancer. part 1: screening, diagnosis, and local treatment with curative intent-update 2013. *Eur Urol*. 2014;65(1):124-37.
239. Kleinjan GH BNvd, Brouwer OR, Jong J de, Acar C, Wit EM, et al. . Optimisation of Fluorescence Guidance During Robot-assisted Laparoscopic Sentinel Node Biopsy for Prostate Cancer. . *Eur Urol*. 2014;66:991-8.
240. Roth B, Wissmeyer MP, Zehnder P, Birkhauser FD, Thalmann GN, Krause TM, et al. A new multimodality technique accurately maps the primary lymphatic landing sites of the bladder. *Eur Urol*. 2010;57(2):205-11.
241. Brouwer OR, Valdes Olmos RA, Vermeeren L, Hoefnagel CA, Nieweg OE, Horenblas S. SPECT/CT and a portable gamma-camera for image-guided laparoscopic sentinel node biopsy in testicular cancer. *J Nucl Med*. 2011;52(4):551-4.
242. Satoh M, Ito A, Kaiho Y, Nakagawa H, Saito S, Endo M, et al. Intraoperative, radio-guided sentinel lymph node mapping in laparoscopic lymph node dissection for Stage I testicular carcinoma. *Cancer*. 2005;103(10):2067-72.
243. Brouwer OR, Noe A, Olmos RA, Bex A. Lymphatic drainage from renal cell carcinoma along the thoracic duct visualized with SPECT/CT. *Lymphat Res Biol*. 2013;11(4):233-8.
244. LC G. Clinical practice endometriosis. *New Engl J Med*. 2010;362:2389-98.
245. Maccagnano C PF, Rocchini L, Ghezzi M, Scattoni V, Montorsi F, Rigatti P, Colombo R. Diagnosis and treatment of bladder endometriosis: state of the art. *Urol Int*. 2012;89:249-58.
246. CV C. Endometriosis of the urinary tract. . *Urol Clin North Am*. 2002;29:625-35.
247. Koninck PR MD. Surgical treatment of deeply infiltrating endometriosis. In: Shaw RX (ed) *Endometriosis: current understanding and management*. . Blackwell, Oxford. 1995:264-81.
248. Seracchioli R MD, Colombo FM, Vianello F, Reggiani A, Venturoli S Cystoscopy-assisted laparoscopic resection of extramucosal bladder endometriosis. *J Endourol*. 2002;16:663-6.
249. Nana GR BA, Akhter W, Karim O, Motiwala H. Nephroureterectomy for emphysematous pyelonephritis: An aggressive approach is sometimes necessary. A case report and literature review. . *Int J Surg Case Rep*. 2015;10:179-82.
250. Su Zhang YL, Cheng Wang, Sheng-Jun Fu, Li Yang. Long-term oncologic outcomes of laparoscopic nephroureterectomy versus open nephroureterectomy for upper tract urothelial carcinoma: a systematic review and meta-analysis. . *Peer J*. 2016;4:e2063.
251. Hyung Suk Kim JHK, · Chang Wook Jeong, · Cheol Kwak , Hyeon Hoe Kim. Laparoscopic radical nephroureterectomy is associated with worse survival outcomes than open radical nephroureterectomy in patients with locally advanced upper tract urothelial carcinoma. . *World J Urol*. 2016;34:859-69.

252. Wentao Liu YW, Zhaohui Zhong, Hongyi Jiang, Shifeng Ouyang, Liang Zhu, et al. Transperitoneal versus retroperitoneal laparoscopic nephroureterectomy in the management of upper urinary tract urothelial carcinoma: a matched-pair comparison based on perioperative outcomes. . *Surg Endosc.* 2016;30(12):5537-41.
253. Ribal MJ, Huguet, J., Alcaraz, A.. Oncologic outcomes obtained after laparoscopic, robotic and/or single port nephroureterectomy for upper urinary tract tumours. . *World J Urol.* 2013;31:93-107.
254. Stravodimos KG, Komninos,C., Kural, A.R., Constantinides, C.. . Distal ureterectomy techniques in laparoscopic and robot-assisted nephroureterectomy: Updated review. . *Urol Ann.* 2015;7(1):8-16.
255. Sung Yul Park WJ, Won Sik Ham, Won Tae Kim, Koon Ho Rha. Initial experience of robotic nephroureterectomy: a hybridport technique. . *Brit J Urol Int.* 2009;104(11):1718-21.
256. Sangjun Yoo DY. Does lymph node dissection during nephroureterectomy affect oncological outcomes in upper tract urothelial carcinoma patients without suspicious lymph node metastasis on preoperative imaging studies? . *World J Urol.*
257. Kondo T NH, Ito F, Hashimoto Y, Toma H, Tanabe K Primary site and incidence of lymph node metastases in urothelial carcinoma of upper urinary tract. . *Urol* 2007;69:265-9.
258. Matin SF SJ, Espiritu PN, Coleman JA, Spiess PE. Patterns of Lymphatic Metastases in upper tract urothelial carcinoma and proposed dissection templates. *J Urol.* 2015.
259. Seisen T, Shariat, S.F., Cussenot, O., Peyronnet, B., Renard-Penna, R., Colin, P., Rouprêt, M. Contemporary role of lymph node dissection at the time of radical nephroureterectomy for upper tract urothelial carcinoma. *World J Urol.* 2016.
260. Haichao Yuan XM, Yunjin Bai, Hengping Li, Liangren Liu, Chunxiao Pu, Jinhong Li, et al. The effect of intravesical chemotherapy in the prevention of intravesical recurrence after nephroureterectomy for upper tract urothelial carcinoma: a meta-analysis. . *J Chemother.*27(4):195-200.
261. Xiaheng Deng XY, Yidong Cheng, Xuzhong Liu, Bian Wu, Zijie Wang, et al. Prognostic value and efficacy valuation of postoperative intravesical instillation in primary urothelial carcinomas of upper urinary tract. . *Int J Clin Exp Med.* 2014;7(12):4734-46.
262. Wieringa FP BH, Eendebak PT, Basten JPA van, Beerlage HP, Smits GAHJ, et al. Improved depth perception with three-dimensional auxiliary display and computer generated three-dimensional panoramic overviews in robot-assisted laparoscopy. . *J Med Imag.* 2014;1(1):015001.
263. Alamyar M BH, Goossens WJH, Wieringa FP, Kroon BK, Eendebak PT, et al. Use of 3D HD auxiliary monitor by bedside assistant results in shorter console-time and ischemia-time in robot-assisted laparoscopic partial tumor-nephrectomy. . *Eur Urol.* 2014;13(Suppl 3):29-30.
264. Bouma H MWvd, Eendebak PT, Landsmeer SH, Eekeren AWM van, Haar FB ter. Streaming video-based 3D reconstruction method compatible with existing monoscopic and stereoscopic endoscopy systems. . *Proc SPIE*, vol 8371A.
265. Verbeek FP vdVJ, Schaafsma BE, Swijnenburg RJ, Gaarenstroom KN, Elzevier HW, , et al. . Intraoperative near infrared fluorescence guided identification of the ureters using low dose methylene blue: a first in human experience. *J Urol.* 2013;190:574-9.
266. Polom W MM, Rho YS, Matuszewski M. Use of invisible near infrared light fluorescence with indocyanine green and methylene blue in urology. . Part 2 *Cent European J Urol* 2014;67:310-3.
267. Quest. Simultaneous HD full color and fluorescent medical imaging platform. [Available from: www.quest-mi.com].

Appendices (in Dutch)

Appendix 1. Nederlandse samenvatting

Inleiding

Laparoscopische en robot-geassisteerde chirurgie in de urologie zijn aantrekkelijke, maar moeilijk uitvoerbare technieken. Patiëntrelevante uitkomsten (bijvoorbeeld oncologisch en functioneel) van deze technieken zijn ten minste vergelijkbaar met open chirurgie, en de hersteltijd na een ingreep is doorgaans korter. Echter, gebruik van deze technieken vereist uitgebreide training en oefening, en gaat gepaard met hoge kosten.

De aanbevelingen voor laparoscopie en robotchirurgie zijn geschreven vanwege de vraag om instructies op dit gebied. In dit document zijn voor de verschillende indicatiegebieden de technieken en veiligheidsaspecten uitgebreid uitgewerkt, voorzien van een veelheid aan visuele ondersteuning. Het doel hiervan is het verbeteren van de patiëntveiligheid en de chirurgische resultaten.

Algemene aanbevelingen

Ten eerste komt het instrumentarium dat gebruikt wordt bij laparoscopische en robot-geassisteerde urologie aan bod. Zo wordt aandacht besteed aan de diverse typen trocars en de wijze waarop hiermee moet worden omgegaan. Ook wordt er in de algemene aanbevelingen ingegaan op bijvoorbeeld electrochirurgie en problemen die daarbij kunnen optreden. Verder beschrijft het algemene hoofdstuk de werking van de insufflator, en andere apparatuur zoals camera, lichtbron, en monitor. Ook wordt informatie verstrekt over de levensduur van de apparatuur.

Een tweede belangrijk onderdeel van de algemene aanbevelingen is patiëntselectie en contra-indicaties. De diverse algemene contra-indicaties komen hierbij aan bod.

Anesthesiologische aspecten die van belang zijn bij laparoscopische en robot-geassisteerde chirurgie in de urologie worden uitvoering beschreven. Veel aandacht gaat daarbij uit naar hemodynamische en pulmonale effecten van pneumoperitoneum en positionering van de patiënt, en complicaties die daarbij op kunnen treden. Tot slot worden in dit deel anesthesiologische aspecten van het postoperatieve traject beschreven.

Andere onderwerpen die in de algemene aanbevelingen aan bod komen zijn ergonomie, doelmatigheid en implementatie van nieuwe technieken.

Veiligheid

Dit hoofdstuk is volledig gewijd aan patiëntveiligheid. Hier wordt ingegaan op het Nederlandse veiligheidsmanagementsysteem in de operatiekamer met gebruik van checklists en de time-out procedure. Ook veiligheid in het gebruik van materialen wordt beschreven, bijvoorbeeld ten aanzien van levensduur, slijtage en controle. Daarnaast komt in dit hoofdstuk de informed consent procedure aan de orde.

Een belangrijk onderdeel van het hoofdstuk over veiligheid zijn de aanbevelingen over multidisciplinaire gebruikersbijeenkomsten, die verplicht zijn om de kwaliteit van minimaal invasieve chirurgie te garanderen.

Tot slot wordt in dit hoofdstuk ingegaan op registratie van uitkomsten en complicaties.

Training

In het hoofdstuk over training wordt het proces van opleiding en certificering beschreven. Het programma voor het verkrijgen van praktische laparoscopische vaardigheden wordt beschreven aan de hand van oefeningen. Voor het verkrijgen van vaardigheden in robot-geassisteerde chirurgie wordt verwezen naar het curriculum van de European Association for Urology, en aanvullende trainingsprogramma's. Ook de overgang van training naar dagelijkse praktijk wordt in dit hoofdstuk beschreven.

Aparte paragrafen besteden aandacht aan training voor operatieassistenten en aan hechtprocedures.

Procedure specifieke aspecten van laparoscopische en robot-geassisteerde chirurgie

Het grootste deel van de nieuwe aanbevelingen voor laparoscopische en robot-geassisteerde chirurgie beslaan de procedure specifieke aspecten. Per ingreep worden onder meer indicaties, contra-indicaties, pre-operatieve voorbereiding, instrumentarium, positionering van de patiënt, de gebruikte technieken, postoperatieve zorg en complicaties beschreven, voorzien van 'tips and tricks' en specifieke aanbevelingen. Deze beschrijvingen zijn zeer rijk voorzien van illustraties en foto's, die de tekst ondersteunen.

De volgende ingrepen komen in dit hoofdstuk aan bod:

- Adrenalectomie
- Nefrectomie (partieel, radicaal, en donor)
- Cryoablatie van niertumoren
- Pyelumplastiek
- Robot geassisteerde radicale prostatectomie met pelviene klierdissectie
- Robot geassisteerde sacrocolpopexie
- Behandeling bij kinderen (inclusief pyelumplastiek, ureterale neo-implantatie voor vesico-ureterale reflux, ureterovesicale obstructie, heminefrectomie, en niet palpabele testis)
- Radicale cystectomie met urinedeviatie
- Schildwachtklierprocedure (image-guided)
- Robot geassisteerde laparoscopische prostaat enucleatie
- Robot geassisteerde laparoscopische ureterolyse en omentum plastiek
- Robot geassisteerde partiële cystectomie vanwege blaasendometriose
- Laparoscopische en robot geassisteerde radicale nefroureterectomie

Tot slot gaat aandacht naar komende ontwikkelingen.

Appendix 2. Samenvatting voor patiënten

Deze aanbevelingen voor laparoscopische en robot-geassisteerde urologie geven instructies voor urologen om deze ingrepen (de zogenaamde 'kijkoperaties') veilig en effectief te kunnen uitvoeren. Deze manier van opereren geeft ten minste even goede resultaten voor patiënten als 'open' chirurgie, maar patiënten herstellen over het algemeen sneller. Echter, deze manier van opereren is moeilijker en duurder. Daarom zijn instructies nodig, waarin deze aanbevelingen voorzien.

De aanbevelingen bevatten vooral veel technische instructies over de manier van opereren, en voorzorgsmaatregelen die de chirurg en anesthesioloog daarbij nemen. Voor patiënten is van belang dat zij door hun behandelaar van tevoren goed voorgelicht worden over de ingreep die zij ondergaan. Daarbij moet de chirurg de patiënt inlichten over de techniek, maar ook over de mogelijke risico's en het resultaat dat de patiënt kan verwachten. Patiënten mogen hier natuurlijk altijd vragen over stellen. Als de patiënt goed is voorgelicht over de mogelijke opties en alle informatie begrijpt, dan kan gezamenlijk besproken worden welke behandeling het beste bij de patiënt past. Dit wordt genoteerd in het patiëntendossier

Appendix 3. Implementatieplan

Deze aanbevelingen voor laparoscopische en robot geassisteerde urologie voorzien in vragen uit de dagelijkse praktijk. Desalniettemin is het niet vanzelfsprekend dat alle aanbevelingen uit dit document automatisch geïmplementeerd worden. Daarin kunnen verschillende strategieën worden gevolgd:

- Verspreiding: Na vaststellen van deze aanbevelingen zullen deze gepubliceerd worden op de website van de Nederlandse Vereniging voor Urologie en zullen alle urologen hiervan op de hoogte worden gebracht.
- Bekendheid creëren: Na publicatie van de aanbevelingen zal op meerdere manieren aandacht voor de inhoud van de aanbevelingen moeten worden gevraagd. Suggesties hiervoor zijn:
 - Afgeleide publicaties in tijdschriften en op websites
 - Presentatie en bespreking van de aanbevelingen binnen de eigen organisatie
 - Presentatie op congressen
- Training: In de opleiding en training zullen deze aanbevelingen gebruikt worden zodat zij veel in de praktijk kunnen worden toegepast.
- Intercollegiale toetsing: In onderling overleg kunnen de aanbevelingen gebruikt worden voor intercollegiale toetsing of bijvoorbeeld bij visitaties steekproefsgewijs besproken worden.
- Inspectie: De Inspectie voor de Gezondheidszorg kan deze aanbevelingen als leidraad gaan gebruiken in de handhaving.
- Ziekenhuismanagement: Bestuurders van instellingen kunnen deze aanbevelingen hanteren bij het formuleren en faciliteren van het instellingsbeleid.